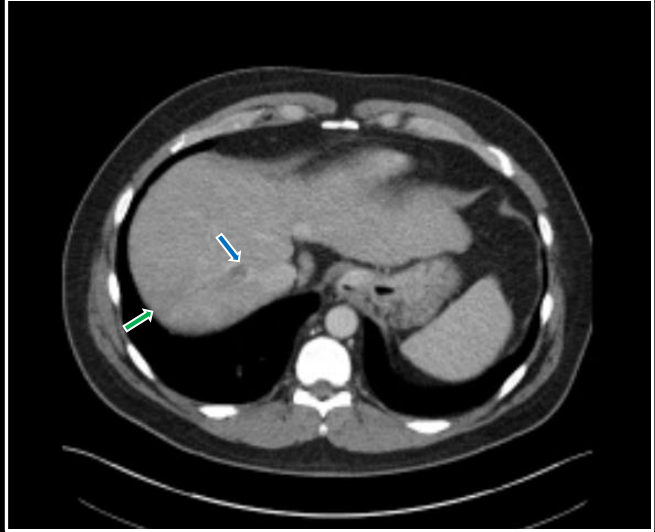


# **“Instant Diagnosis” Neoplasms**

**Benjamin W. Strong, MD**

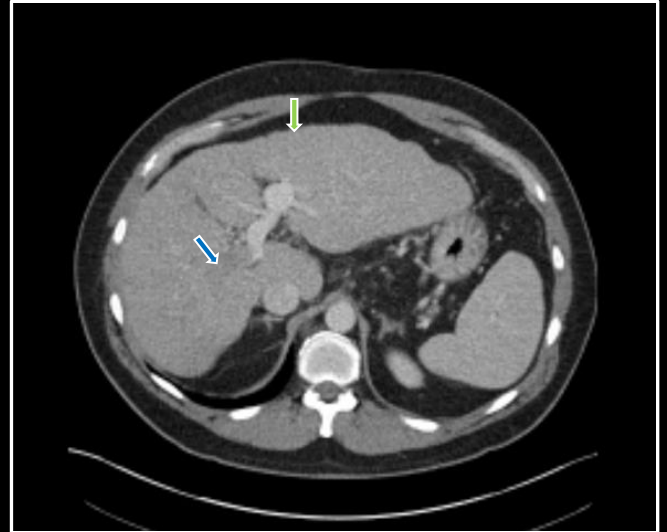
Hypodense hepatic mass  
Nodular liver contour  
Portal venous filling defect  
Hepatic venous filling defect

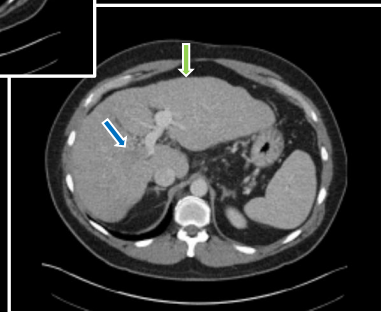
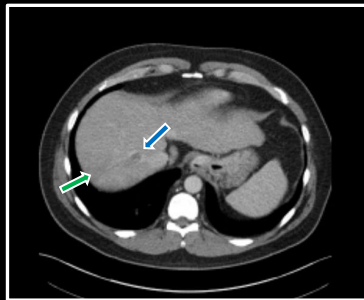
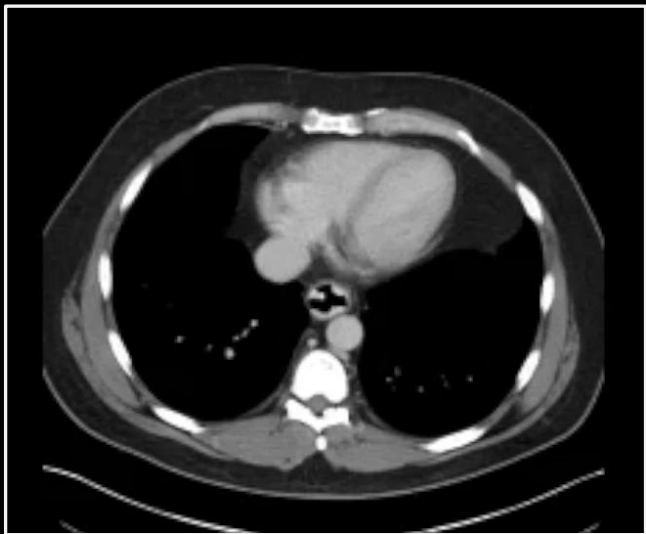
**Vascular invasive HCC**



Hypodense hepatic mass  
Nodular liver contour  
Portal venous filling defect  
Hepatic venous filling defect

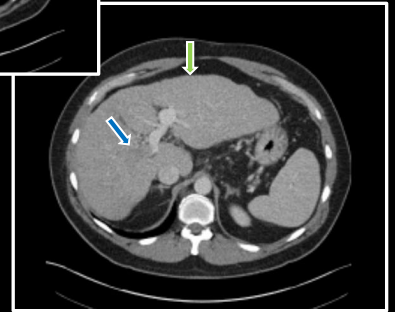
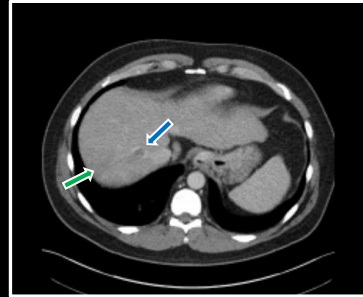
**Vascular invasive HCC**





Hypodense hepatic mass  
Nodular liver contour  
Portal venous filling defect  
Hepatic venous filling defect

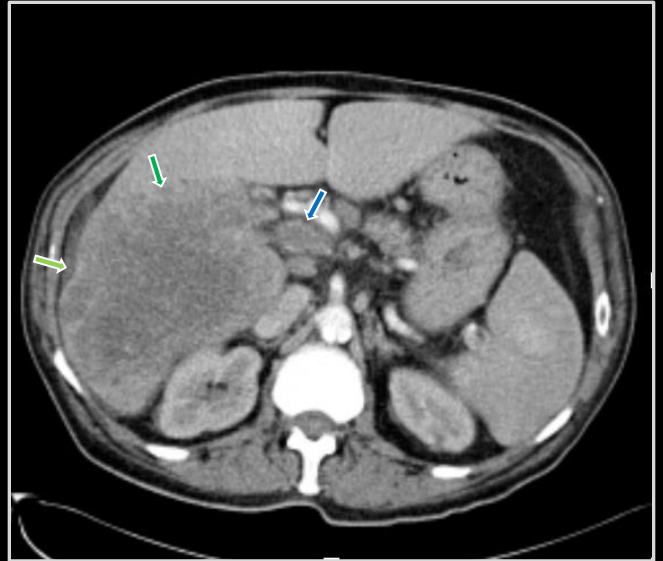
**Vascular invasive HCC**

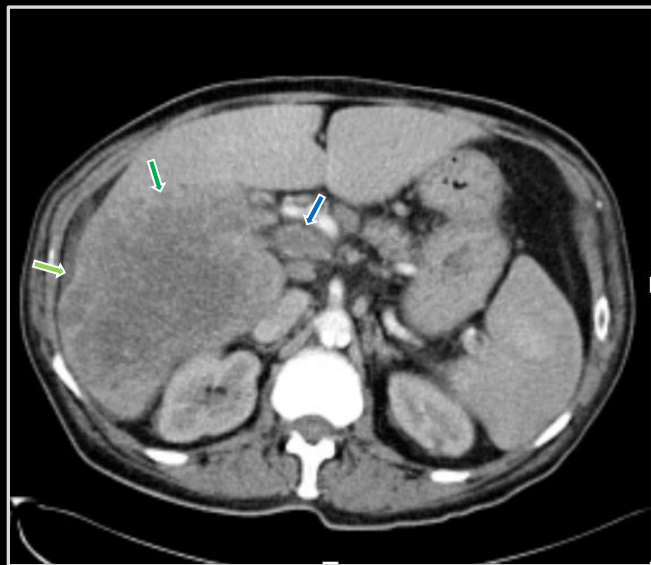
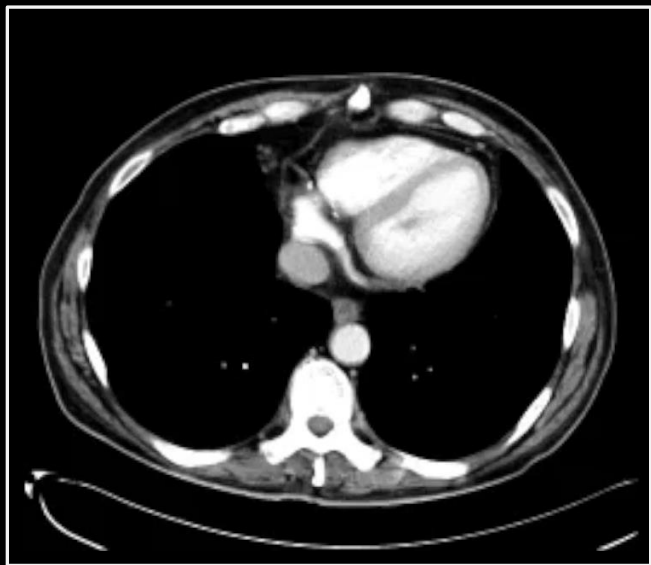




Hypodense hepatic mass  
Capsular cicatrization  
Portal venous filling defect

**Metastatic transitional cell**

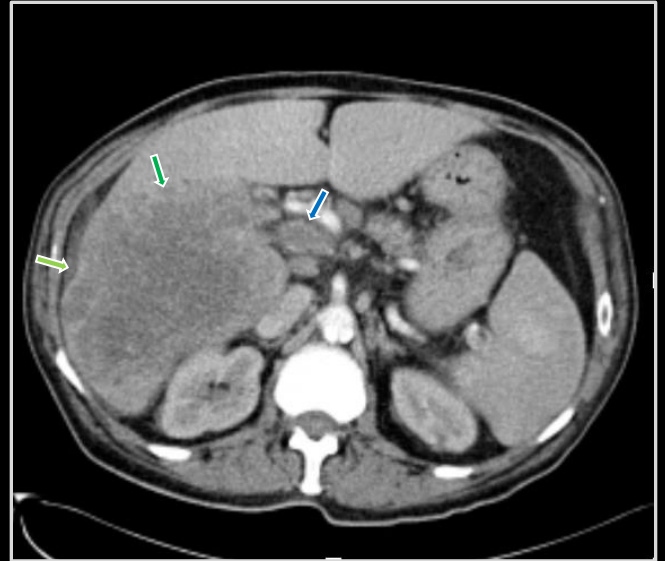






Hypodense hepatic mass  
Capsular cicatrization  
Portal venous filling defect

**Metastatic transitional cell**



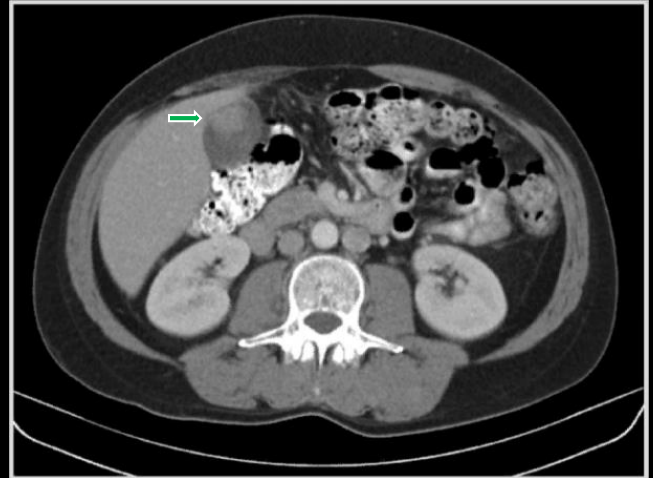


Gallbladder mass

Omental masses

Extra-abdominal soft tissue  
masses

**Metastatic melanoma**

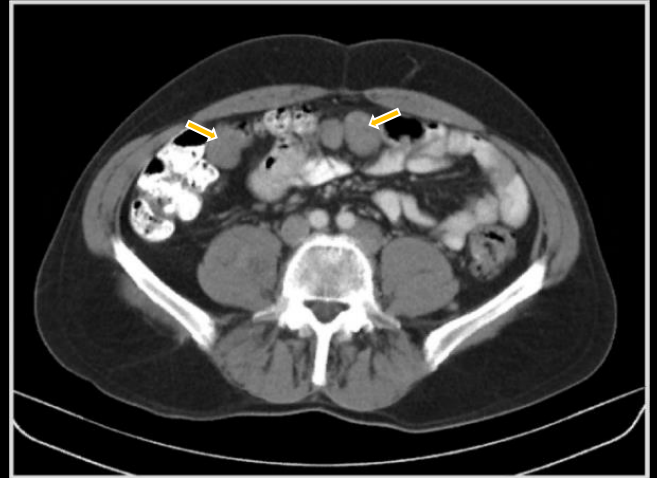


Gallbladder mass

Omental masses

Extra-abdominal soft tissue  
masses

**Metastatic melanoma**

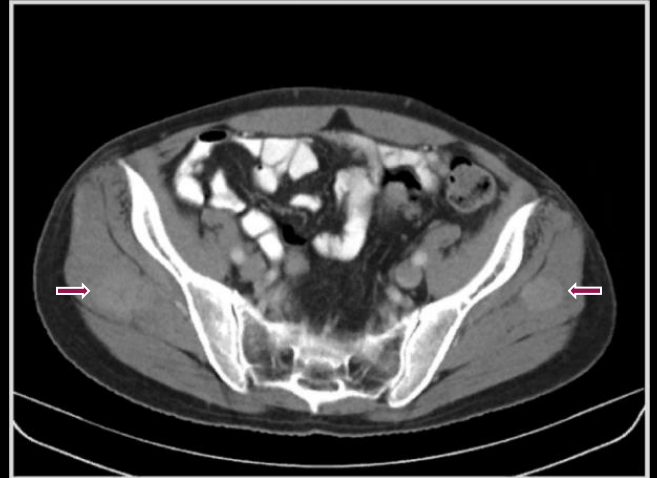


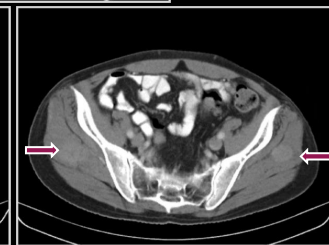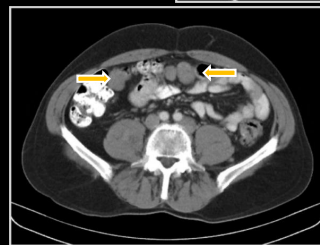
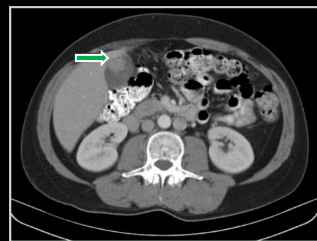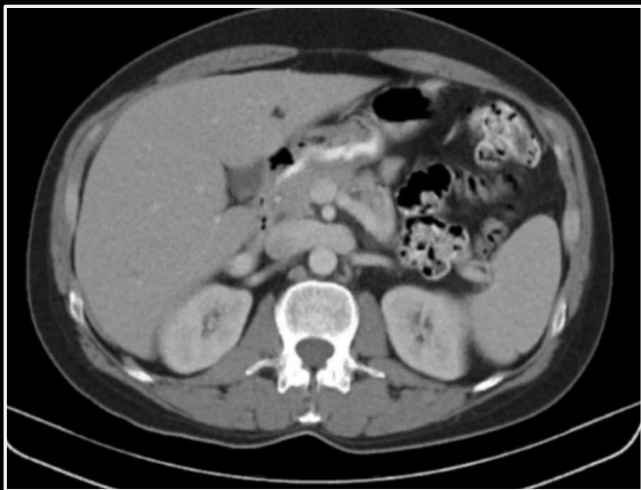
Gallbladder mass

Omental masses

Extra-abdominal soft tissue  
masses

**Metastatic melanoma**



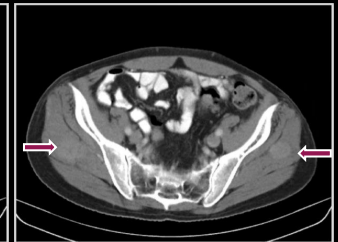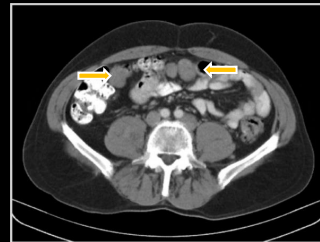
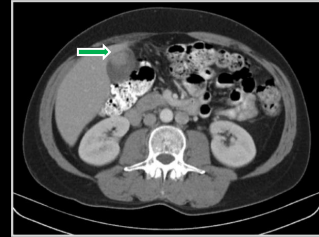


Gallbladder mass

Omental masses

Extra-abdominal soft tissue  
masses

Metastatic melanoma

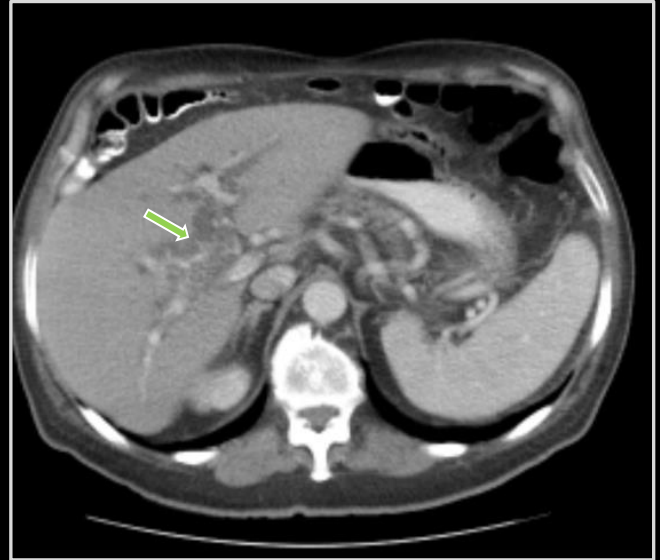





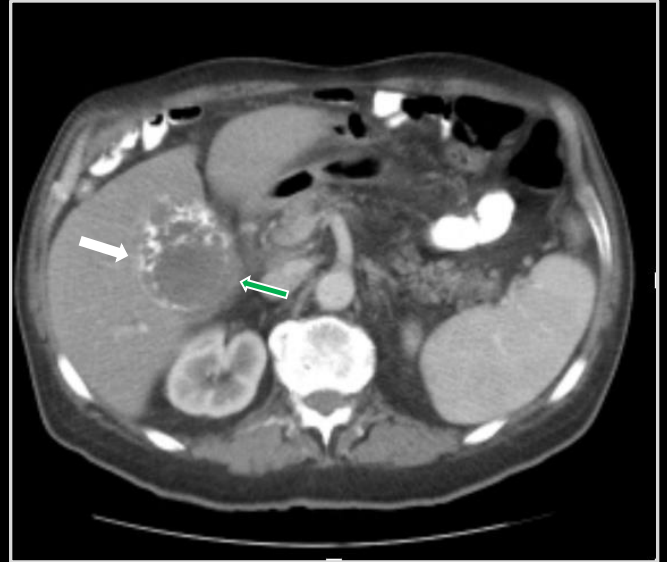Intrahepatic ductal dilation  
Mural gallbladder calcification  
Gallbladder neck soft tissue density

**Gallbladder carcinoma**



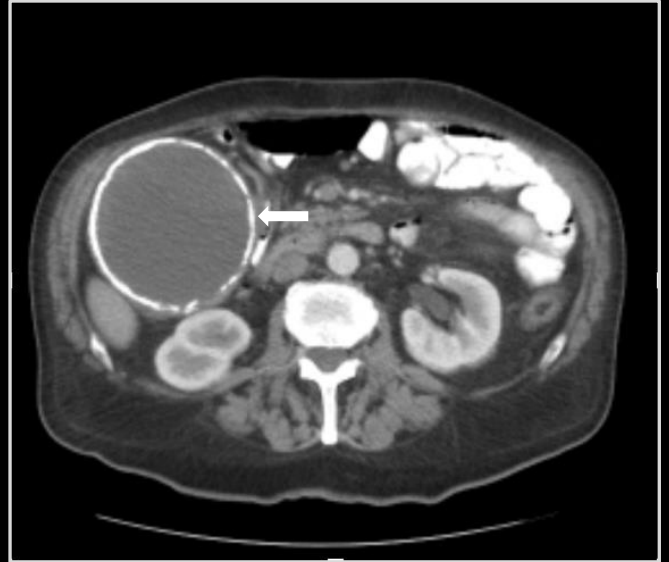
Intrahepatic ductal dilation  
Mural gallbladder calcification  
Gallbladder neck soft tissue density

**Gallbladder carcinoma**



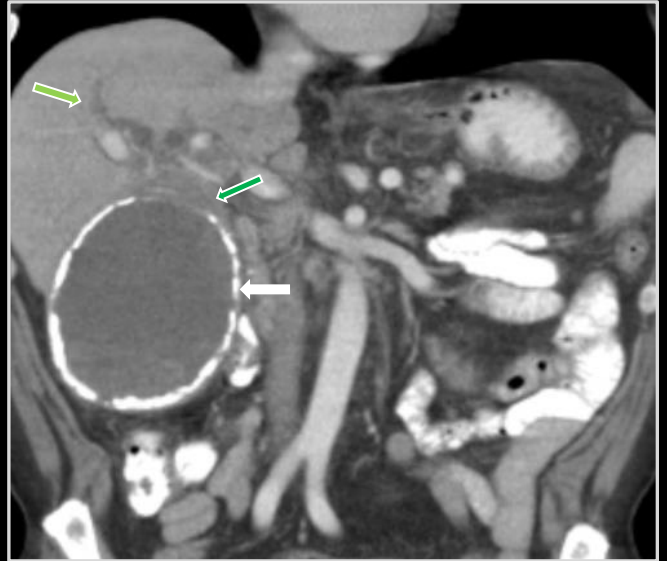
Intrahepatic ductal dilation  
Mural gallbladder calcification  
Gallbladder neck soft tissue density

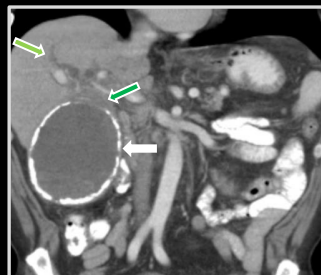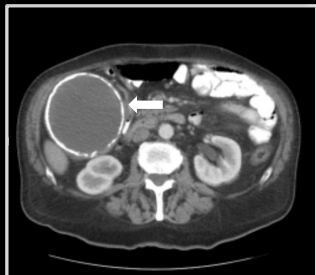
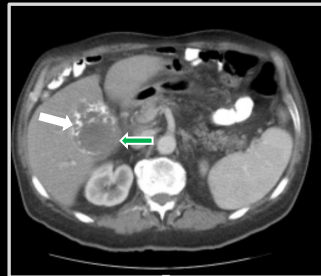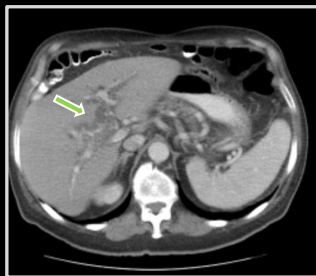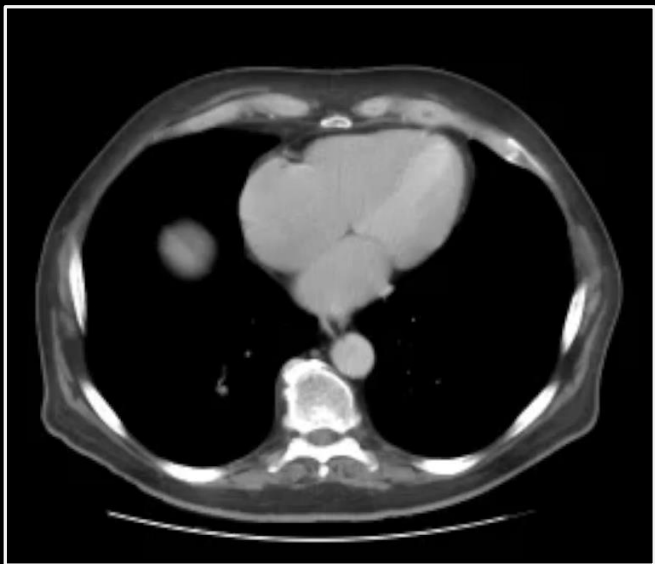**Gallbladder carcinoma**

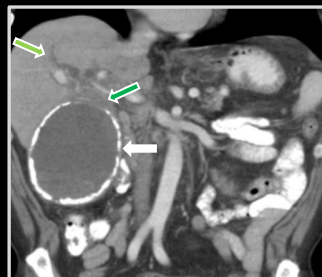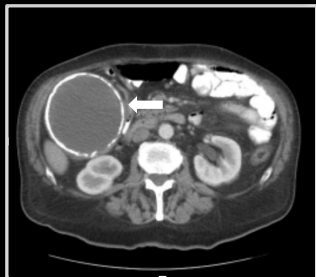
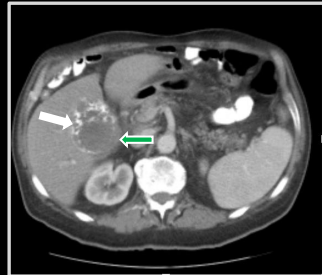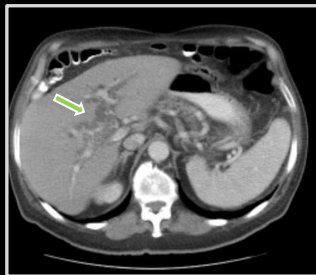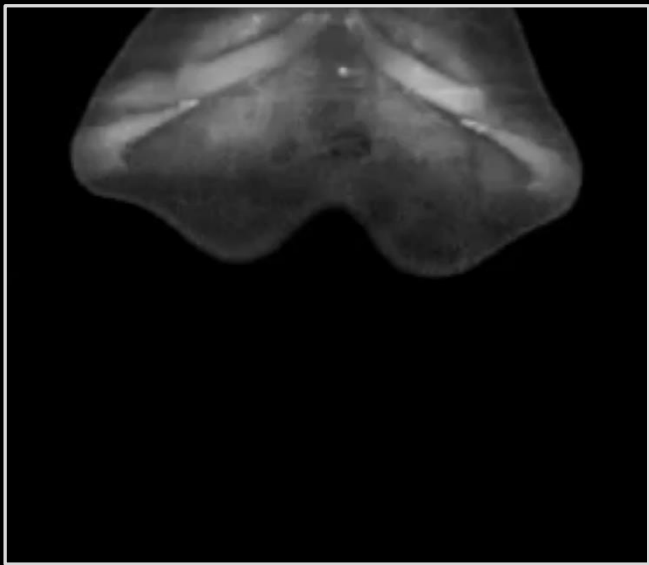


Intrahepatic ductal dilation  
Mural gallbladder calcification  
Gallbladder neck soft tissue density

**Gallbladder carcinoma**

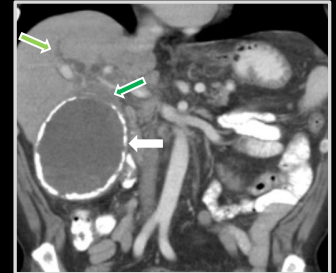
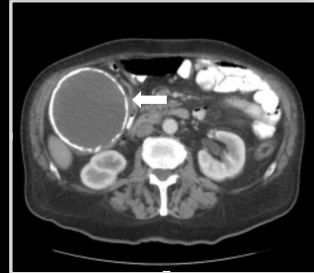
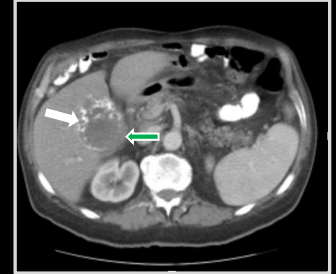
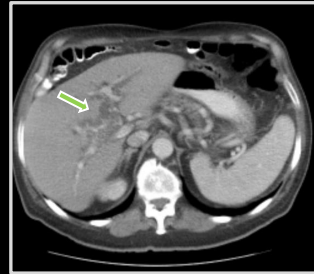


Intrahepatic ductal dilation  
Mural gallbladder calcification  
Gallbladder neck soft tissue density

**Gallbladder carcinoma**

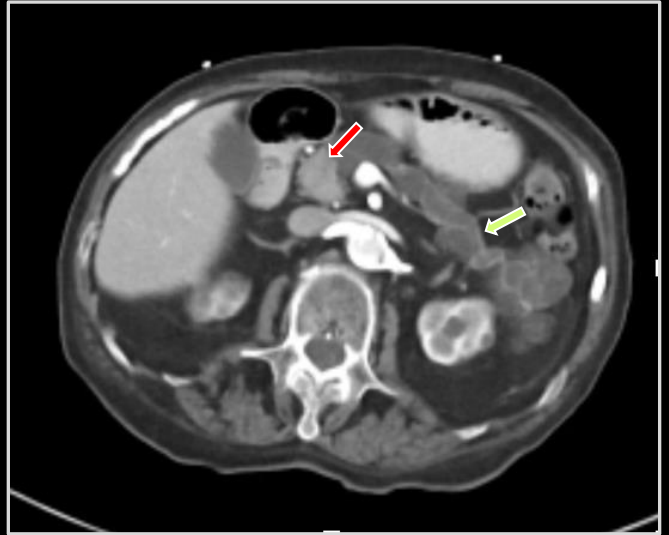






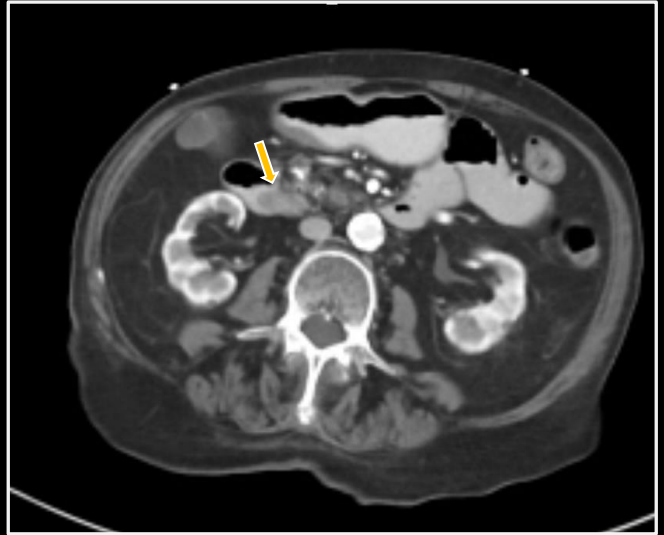
**Pancreatic head mass**  
**Ductal dilation and atrophy**  
**Herniation**

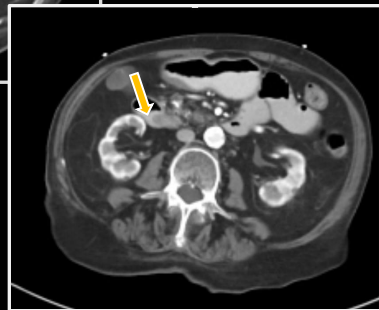
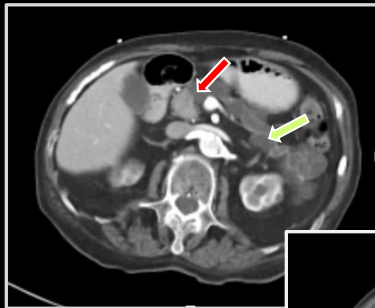
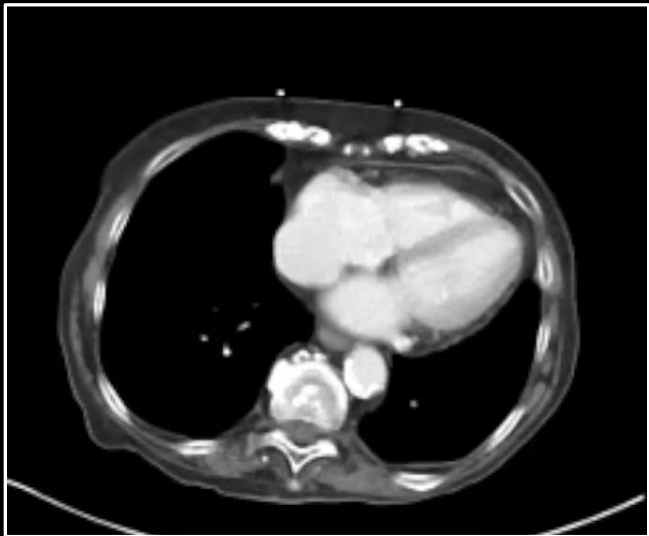
**Intraductal papillary mucinous  
tumor**



Pancreatic head mass  
Ductal dilation and atrophy  
Herniation

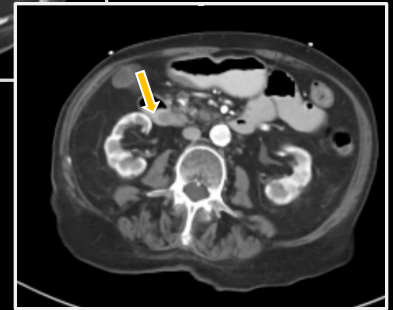
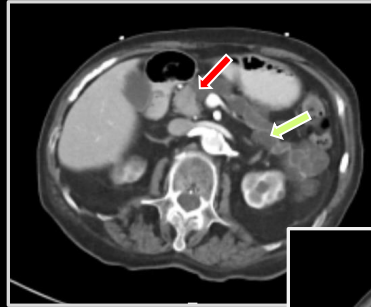
**Intraductal papillary mucinous  
tumor**





**Pancreatic head mass**  
**Ductal dilation and atrophy**  
**Herniation**

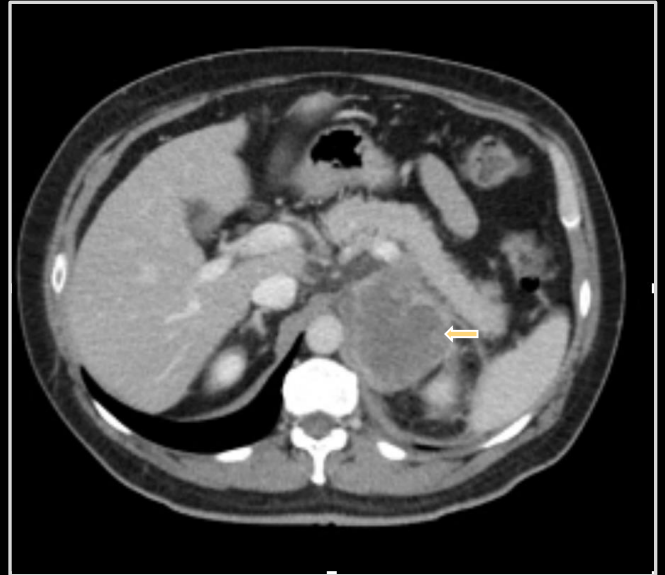**Intraductal papillary mucinous  
tumor**





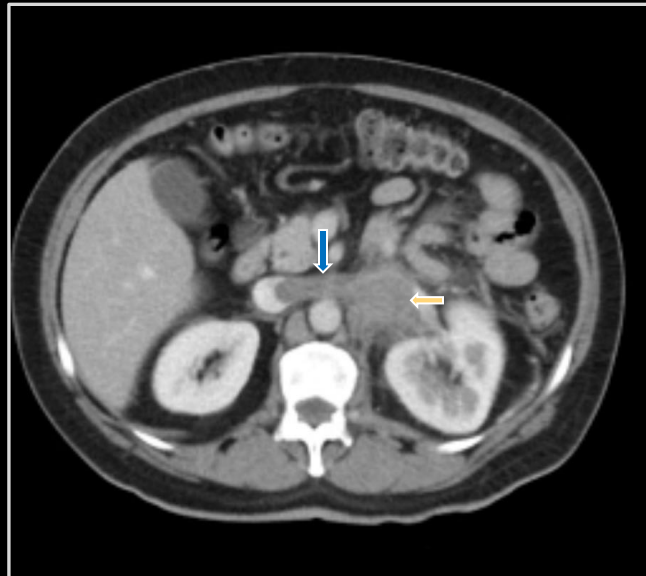
Heterogeneous enhancing  
adrenal mass  
Renal vein and IVC filling defect

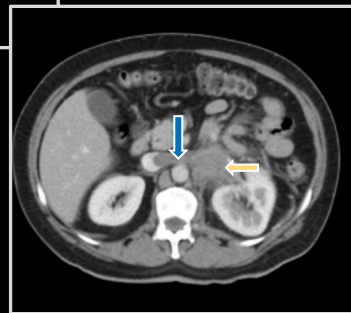
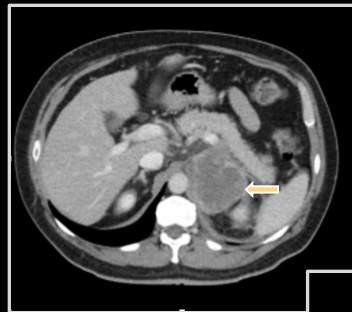
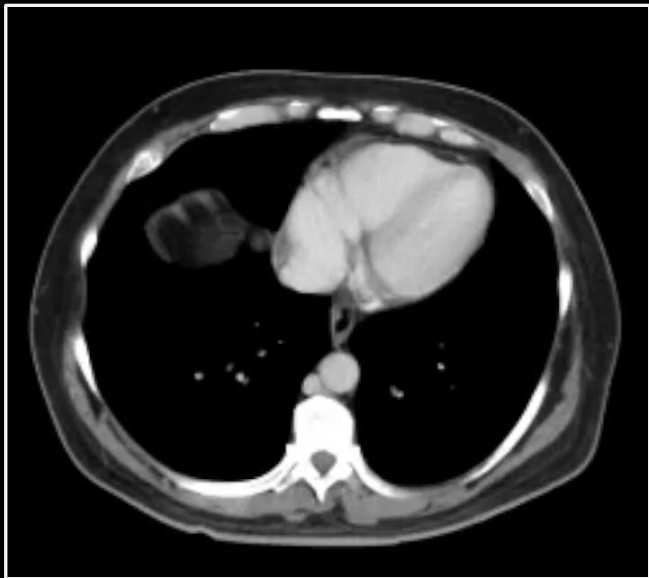**Adrenocortical carcinoma**



Heterogeneous enhancing  
adrenal mass  
Renal vein and IVC filling defect

**Adrenocortical carcinoma**

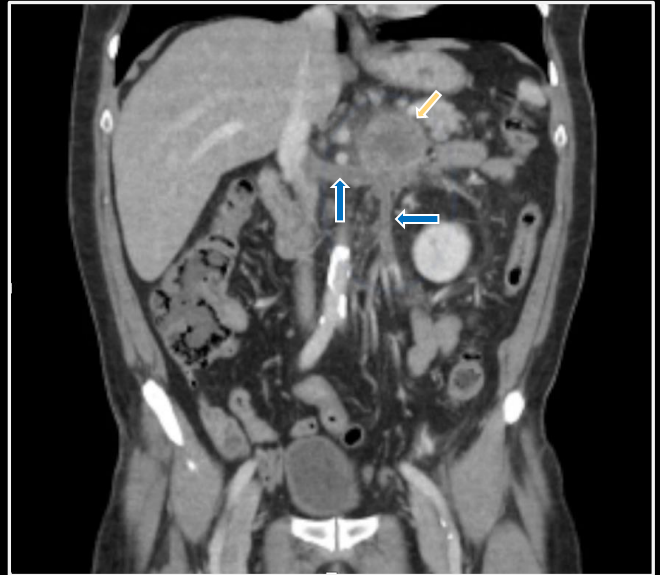

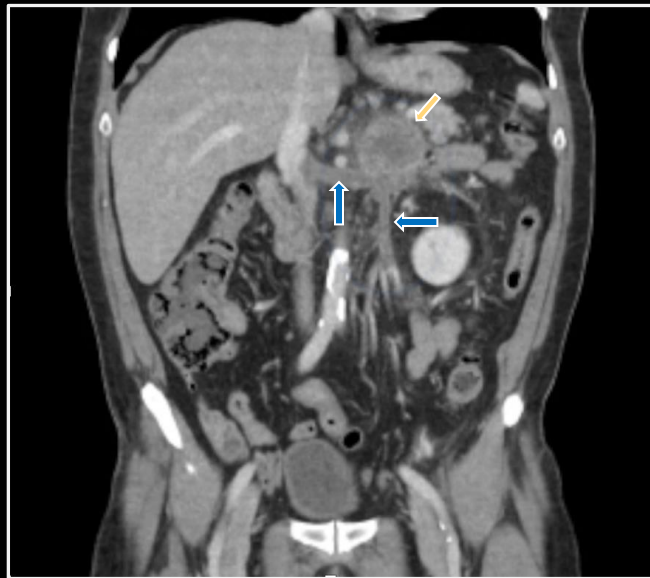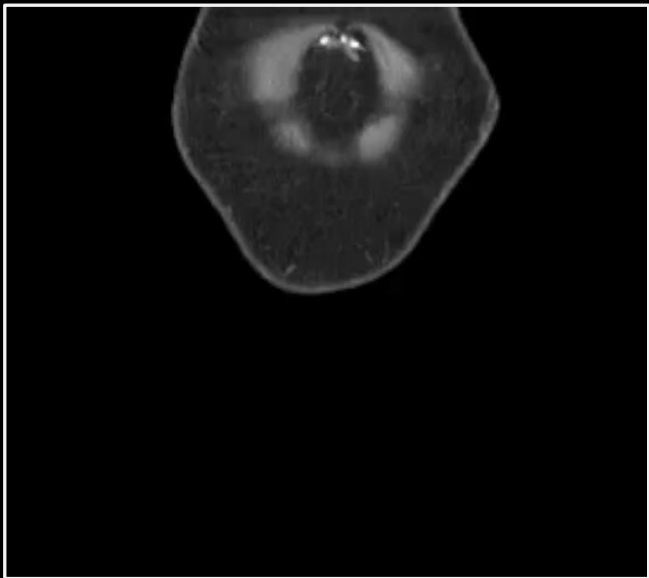




Heterogeneous enhancing  
adrenal mass  
Renal vein and IVC filling defect

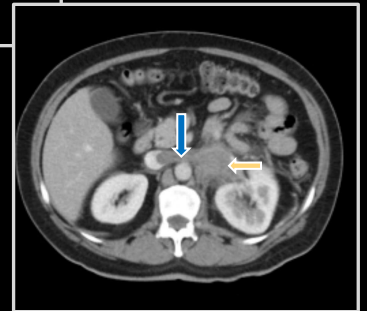
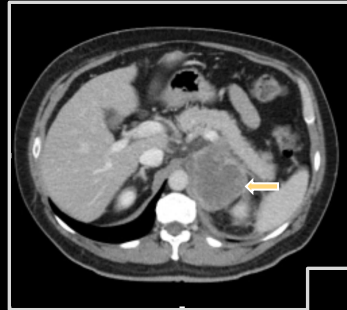**Adrenocortical carcinoma**





Heterogeneous enhancing  
adrenal mass  
Renal vein and IVC filling defect

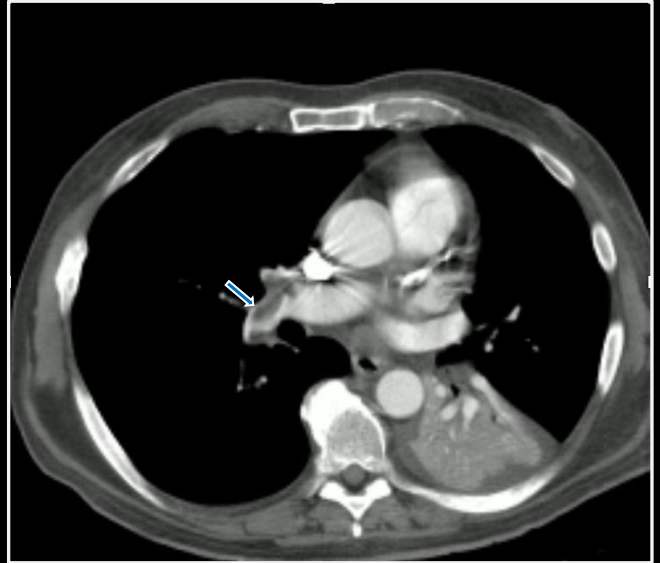
**Adrenocortical carcinoma**





Pulmonary artery defects  
Bronchial compression  
Necrotic adenopathy  
Liver metastases  
Adrenal enlargement  
Renal mass  
Renal vein mass

**Pulmonary embolism**



Pulmonary artery defects

Bronchial compression

Necrotic adenopathy

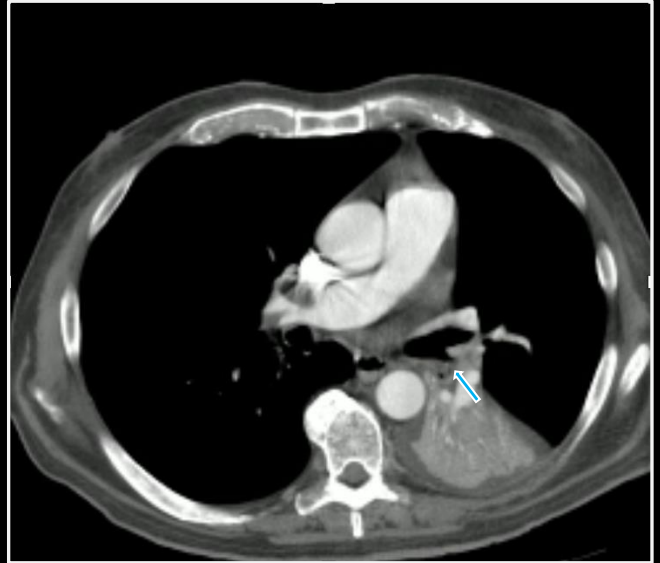Liver metastases

Adrenal enlargement

Renal mass

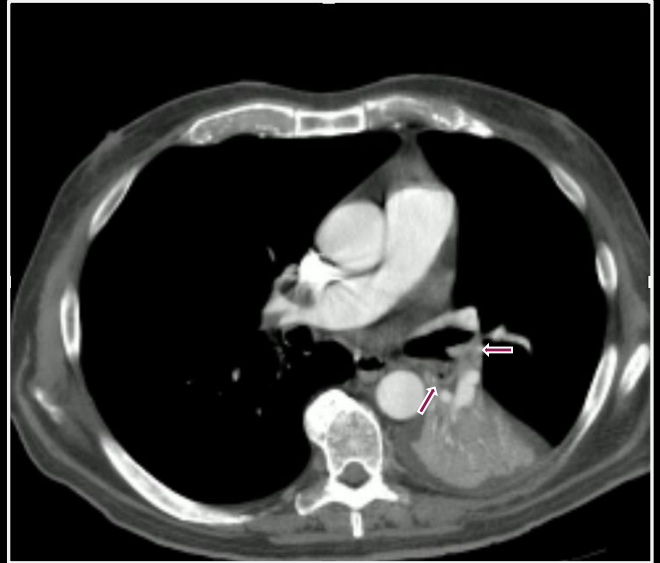Renal vein mass

**Pulmonary embolism**



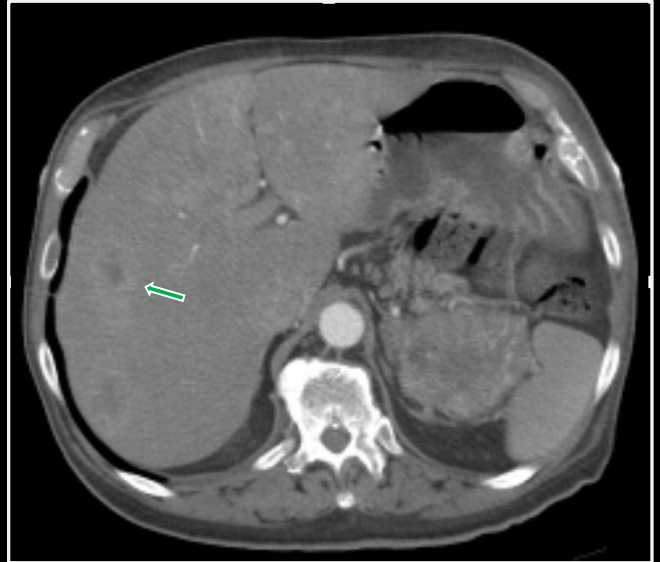
Pulmonary artery defects  
Bronchial compression  
Necrotic adenopathy  
Liver metastases  
Adrenal enlargement  
Renal mass  
Renal vein mass

**Pulmonary embolism**



Pulmonary artery defects  
Bronchial compression  
Necrotic adenopathy  
Liver metastases  
Adrenal enlargement  
Renal mass  
Renal vein mass

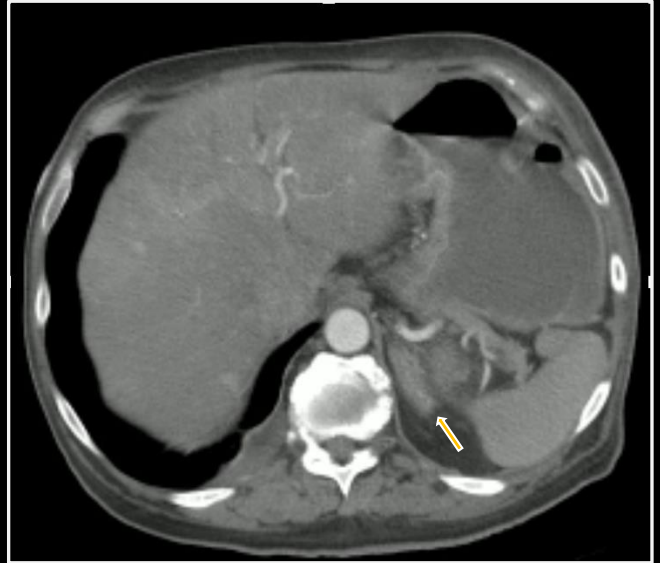
**Pulmonary embolism**





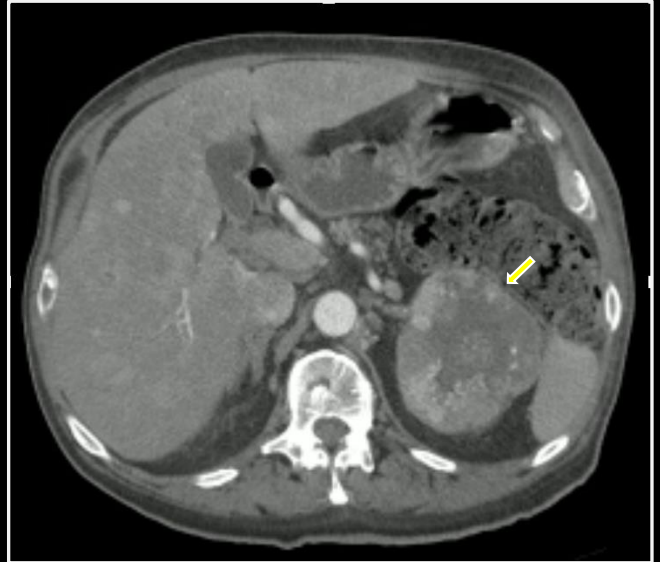
Pulmonary artery defects  
Bronchial compression  
Necrotic adenopathy  
Liver metastases  
Adrenal enlargement  
Renal mass  
Renal vein mass

**Pulmonary embolism**



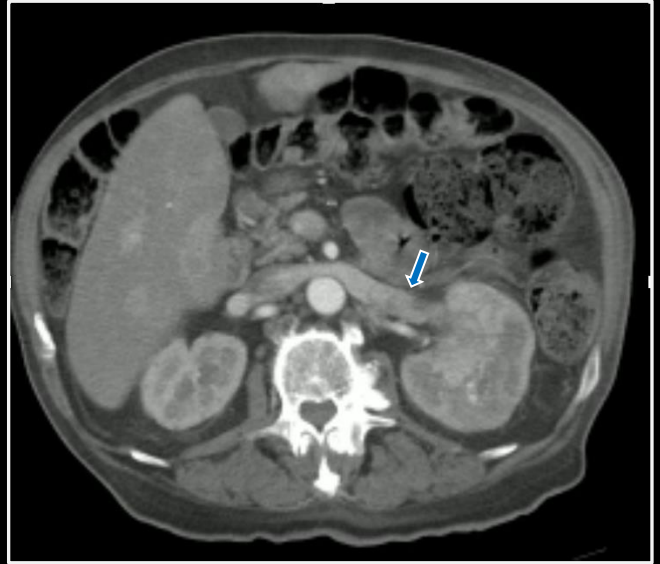
Pulmonary artery defects  
Bronchial compression  
Necrotic adenopathy  
Liver metastases  
Adrenal enlargement  
**Renal mass**  
Renal vein mass

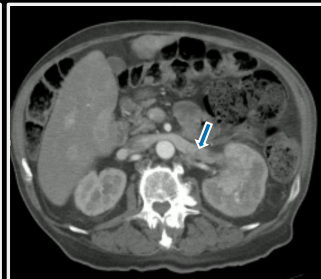
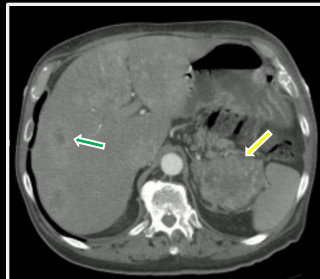
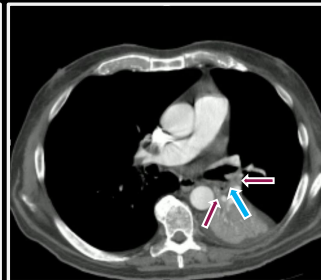
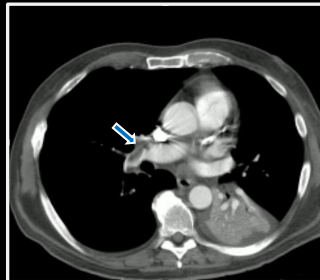
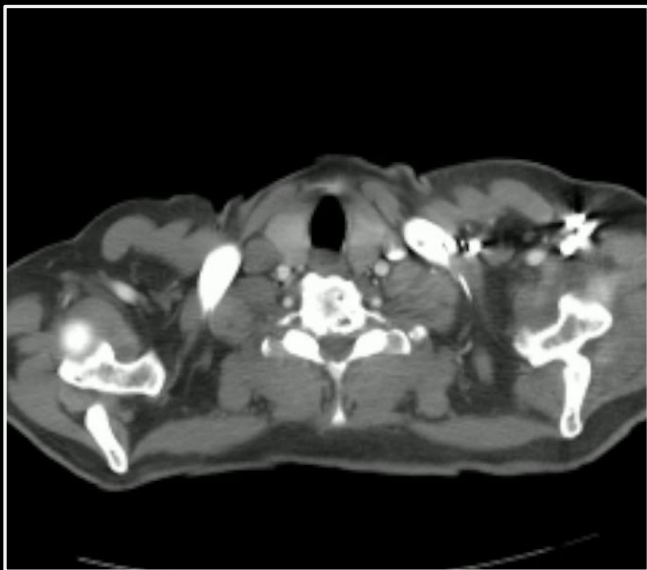
**Pulmonary embolism**



Pulmonary artery defects  
Bronchial compression  
Necrotic adenopathy  
Liver metastases  
Adrenal enlargement  
Renal mass  
Renal vein mass

**Pulmonary embolism**





Pulmonary artery defects

Bronchial compression

Necrotic adenopathy

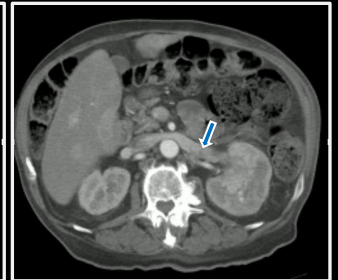
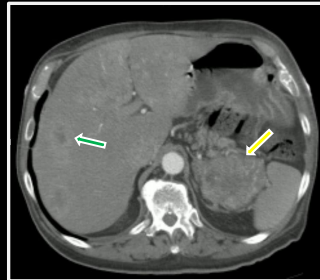
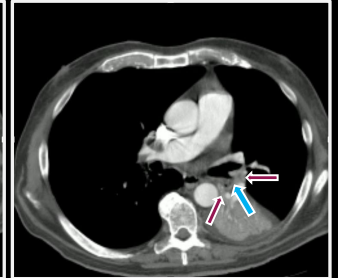
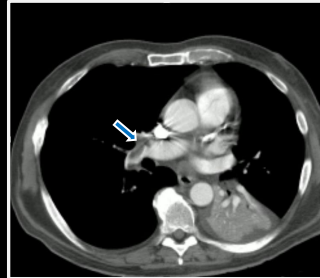
Liver metastases

Adrenal enlargement

Renal mass

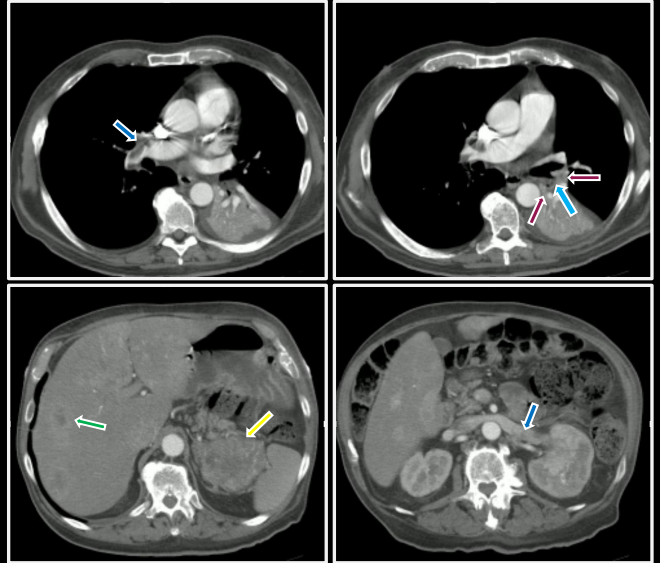
Renal vein mass

**Pulmonary embolism**



Pulmonary artery defects  
Bronchial compression  
Necrotic adenopathy  
Liver metastases  
Adrenal enlargement  
Renal mass  
Renal vein mass

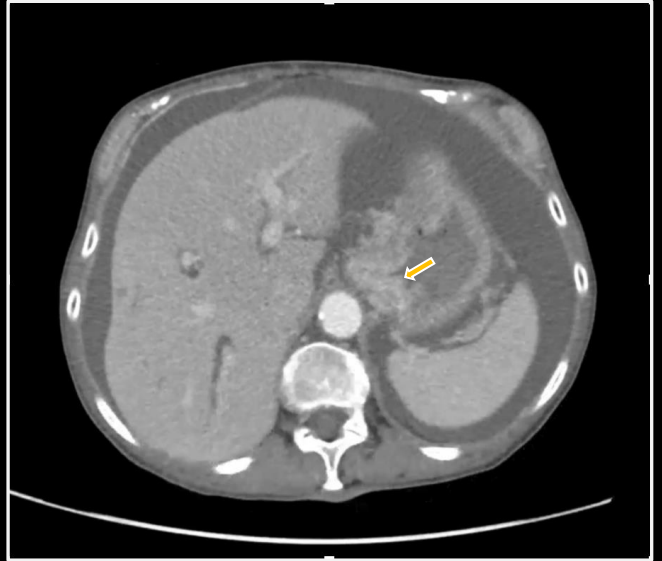
**Metastatic renal cell carcinoma  
with pulmonary embolism**





Gastric enhancement  
Omental nodularity  
Ovarian enlargement

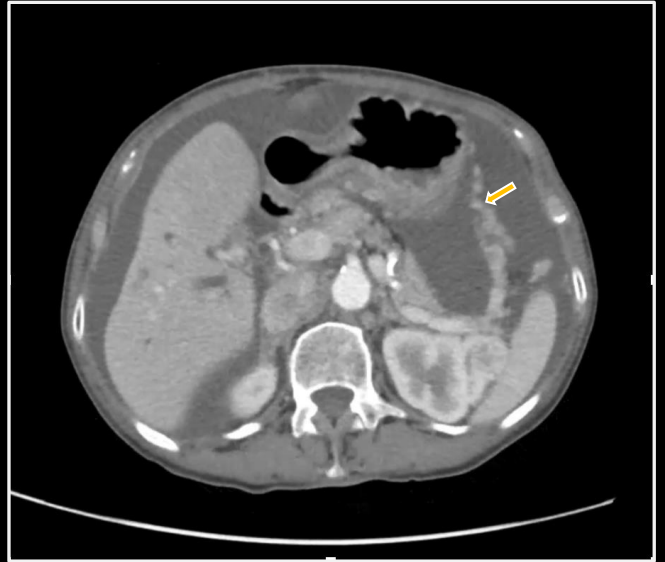**Metastatic Krukenberg tumors**





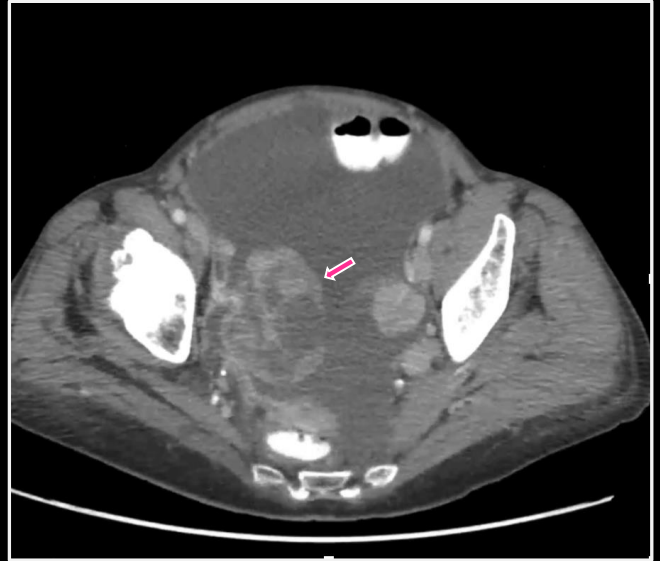
Gastric enhancement  
Omental nodularity  
Ovarian enlargement

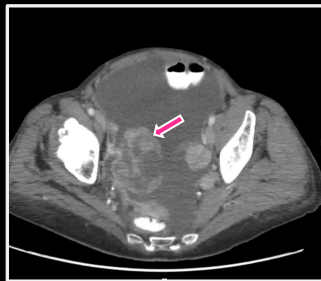
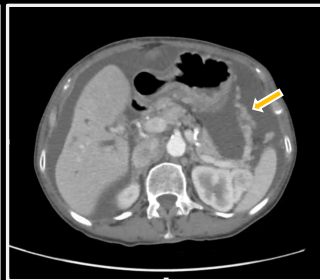
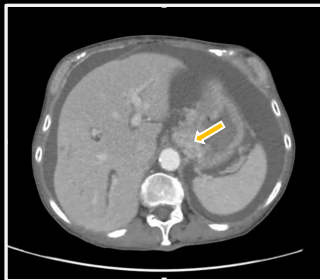
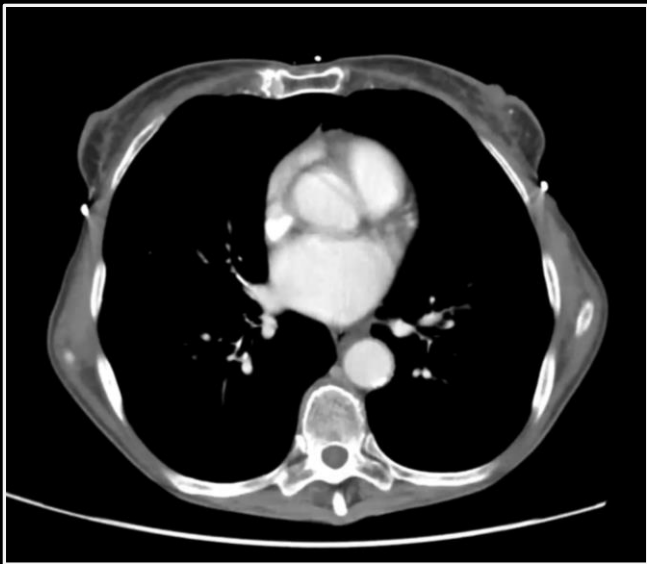**Metastatic Krukenberg tumors**



Gastric enhancement  
Omental nodularity  
Ovarian enlargement

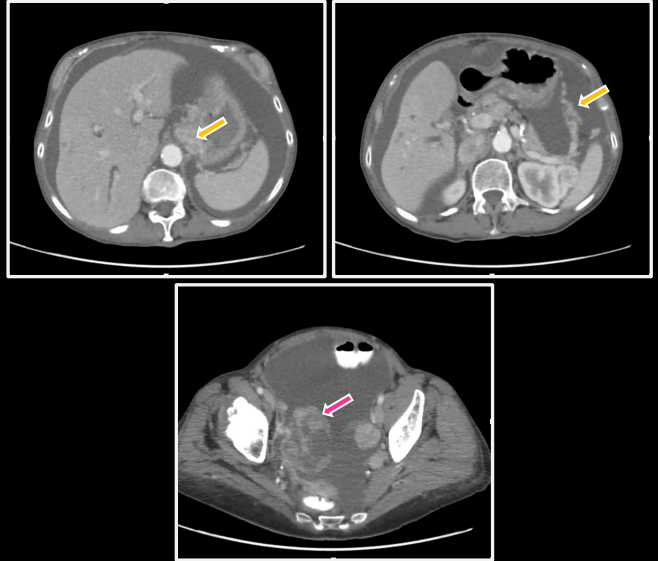
**Metastatic Krukenberg tumors**





Gastric enhancement  
Omental nodularity  
Ovarian enlargement

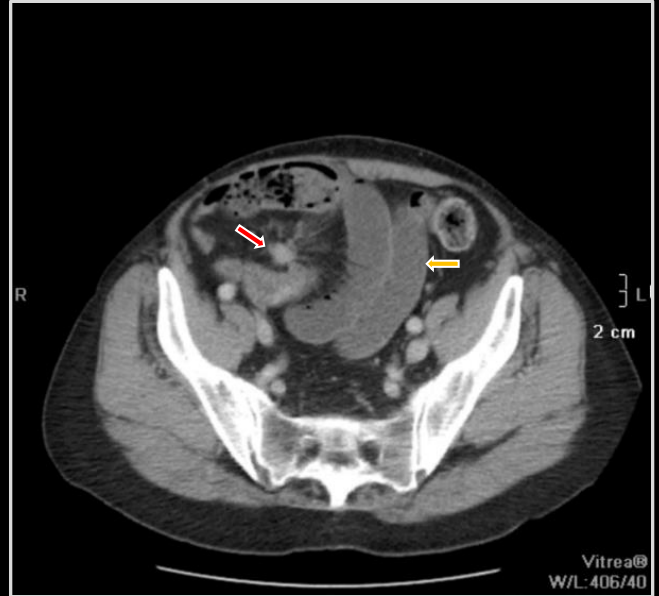
**Metastatic Krukenberg tumors**





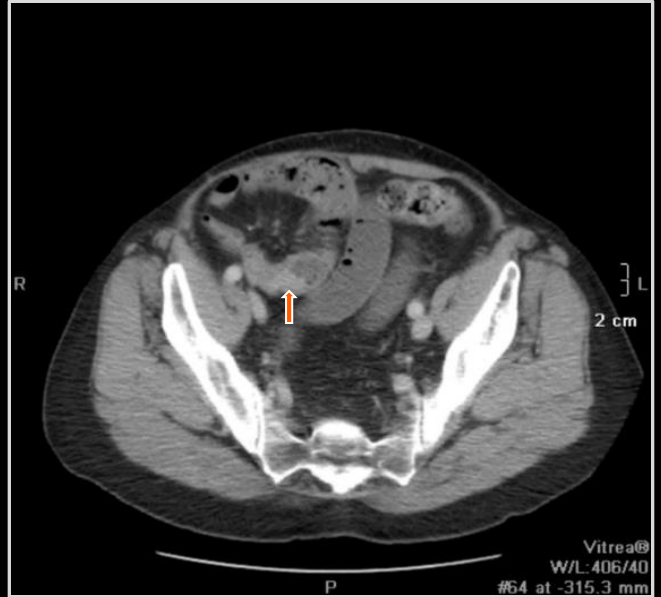Mesenteric mass  
Small bowel dilation  
Small bowel mass

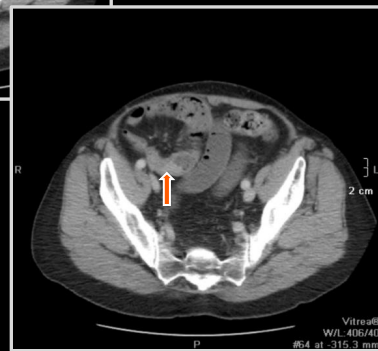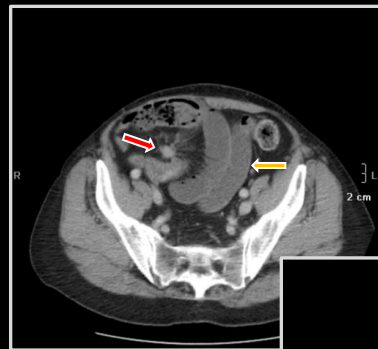
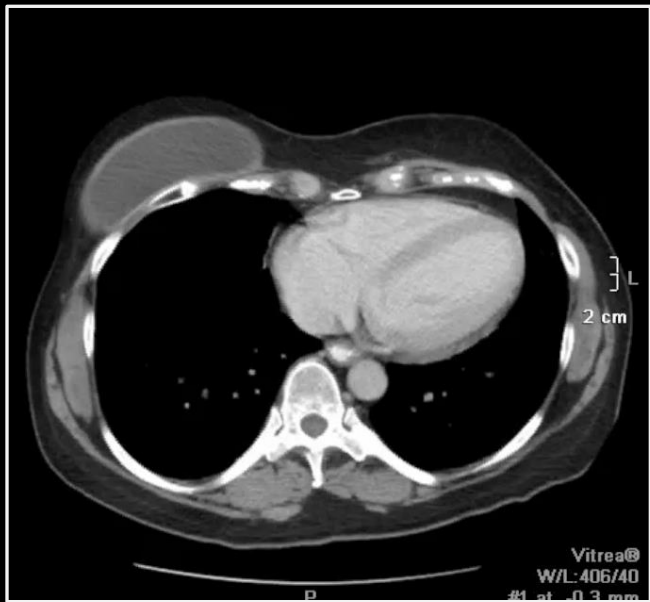
**Metastatic carcinoid tumor**



Mesenteric mass  
Small bowel dilation  
Small bowel mass

**Metastatic carcinoid tumor**

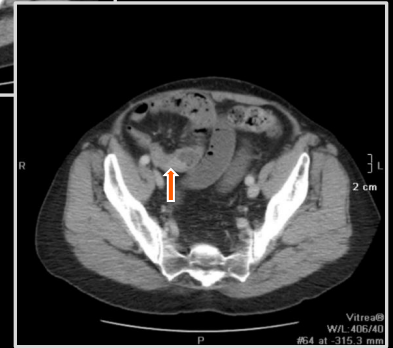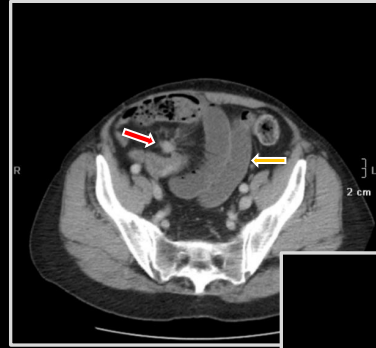






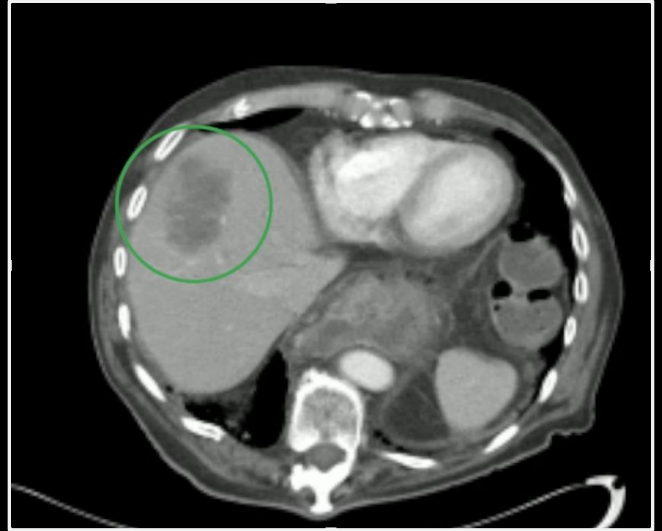
Mesenteric mass  
Small bowel dilation  
Small bowel mass

Metastatic carcinoid tumor

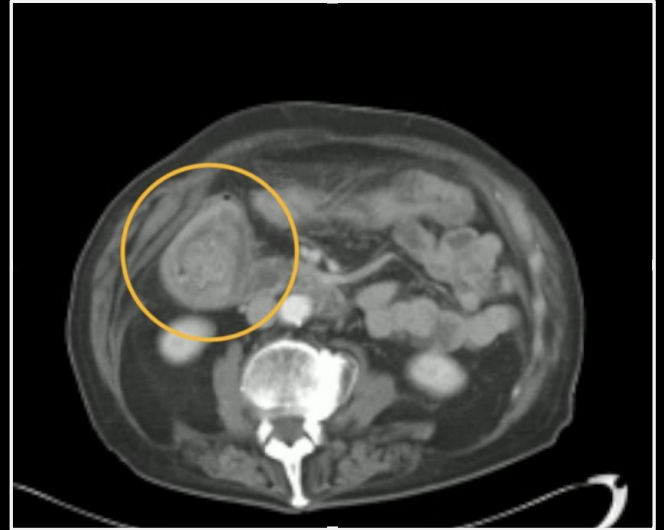


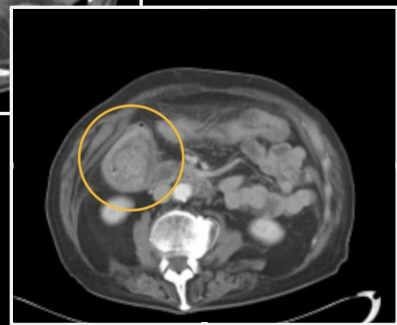
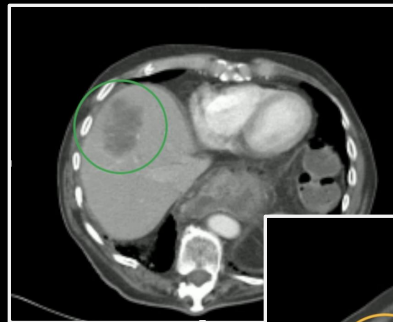
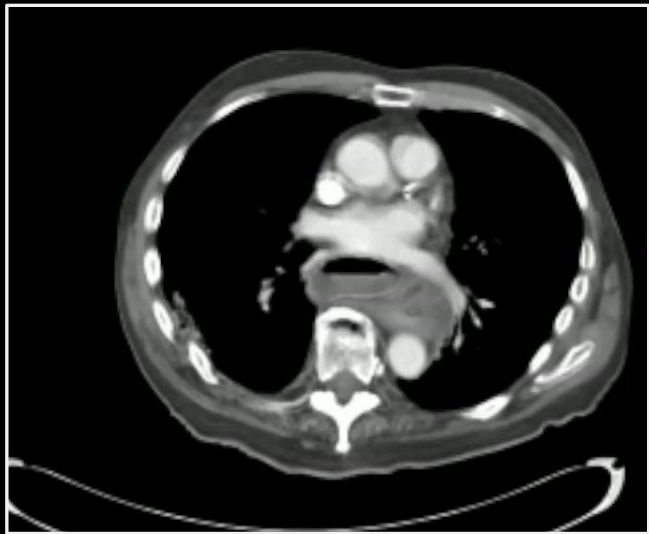Liver hypodensity  
Telescoped colon segment  
**Metastatic adenocarcinoma**

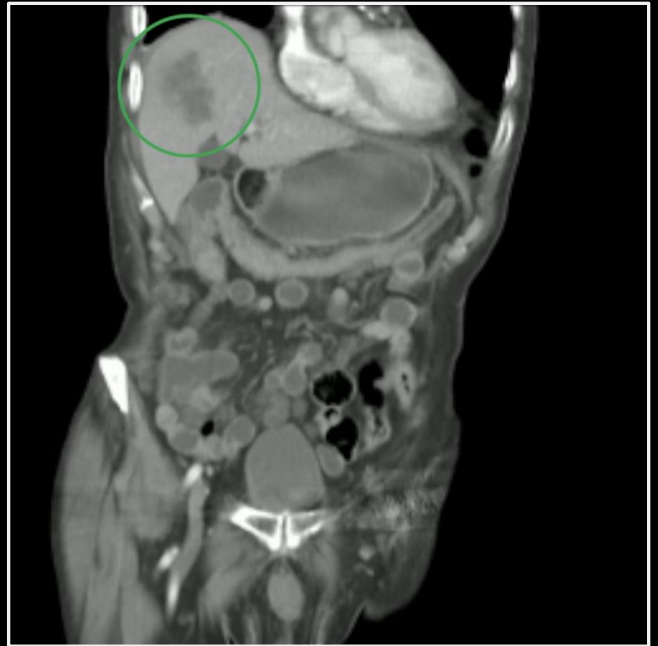

Liver hypodensity  
Telescoped colon segment  
**Metastatic adenocarcinoma**

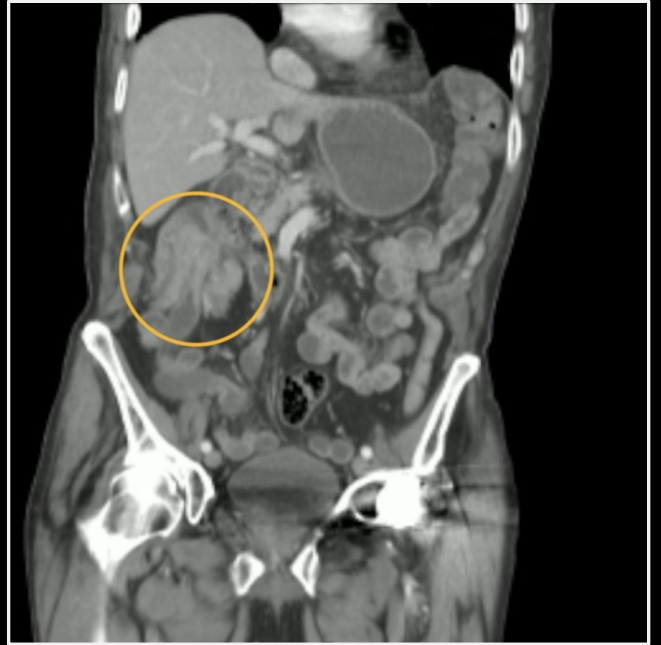

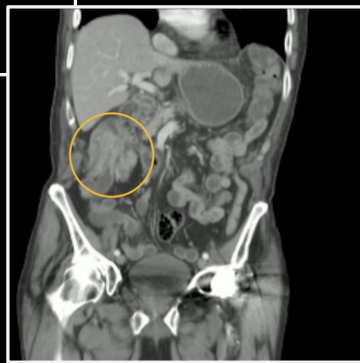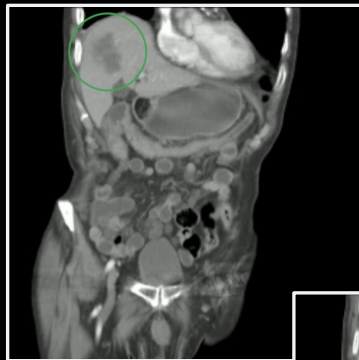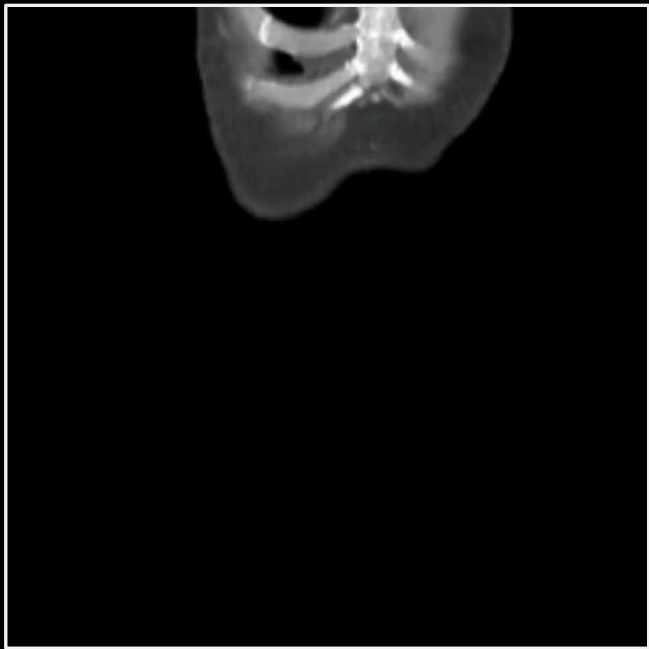


Liver hypodensity  
Telescoped colon segment  
**Metastatic adenocarcinoma**



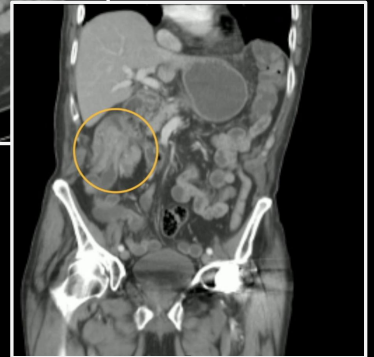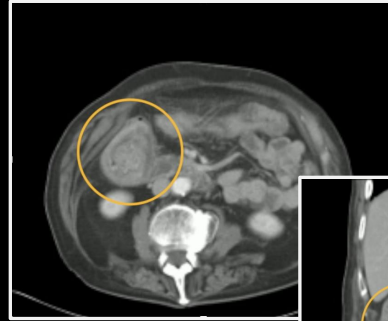
Liver hypodensity  
Telescoped colon segment  
**Metastatic adenocarcinoma**







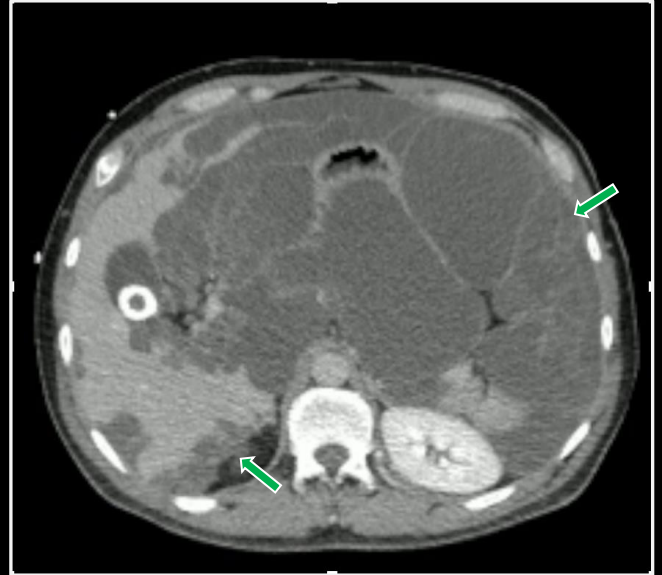
Liver hypodensity  
Telescoped colon segment  
Metastatic adenocarcinoma





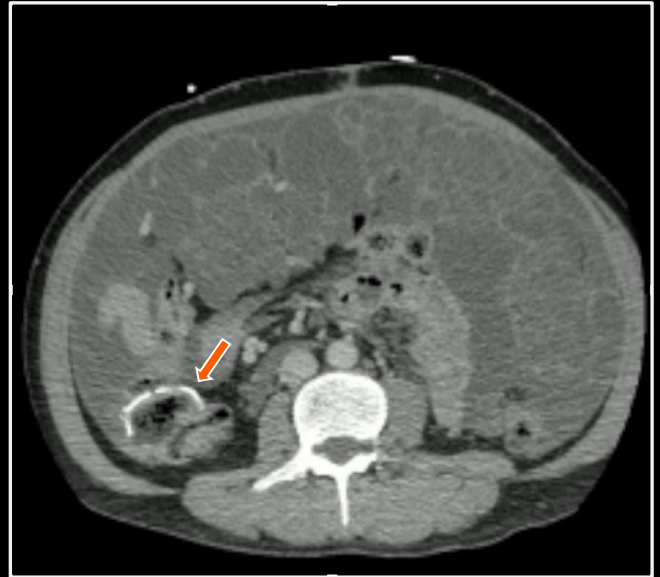Hypodense intraperitoneal masses with hepatic scalloping  
Colectomy

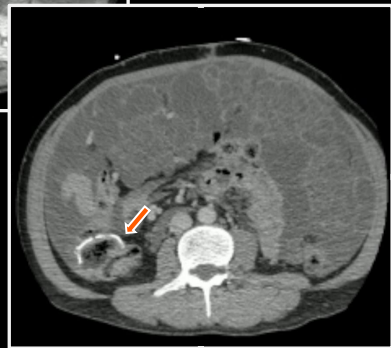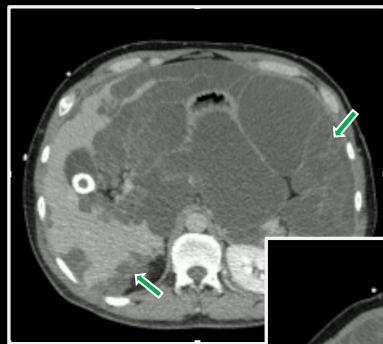
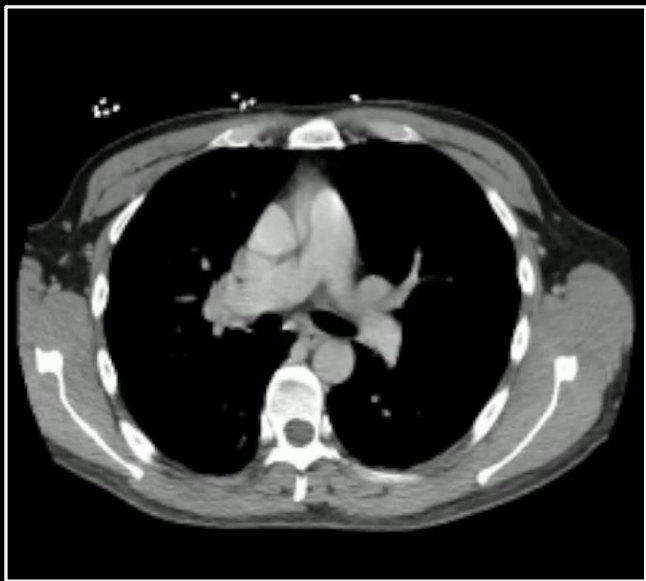**Colon carcinoma recurrence,  
pseudomyxoma peritonei**



Hypodense intraperitoneal  
masses with hepatic scalloping  
**Colectomy**

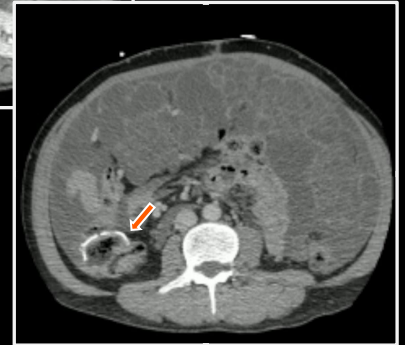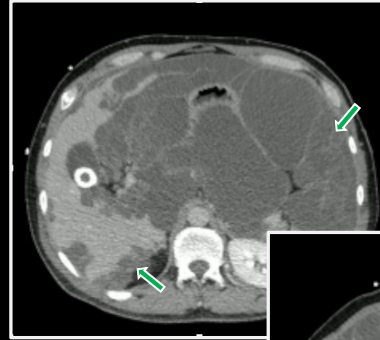
**Colon carcinoma recurrence,  
pseudomyxoma peritoneii**





Hypodense intraperitoneal  
masses with hepatic scalloping  
**Colectomy**

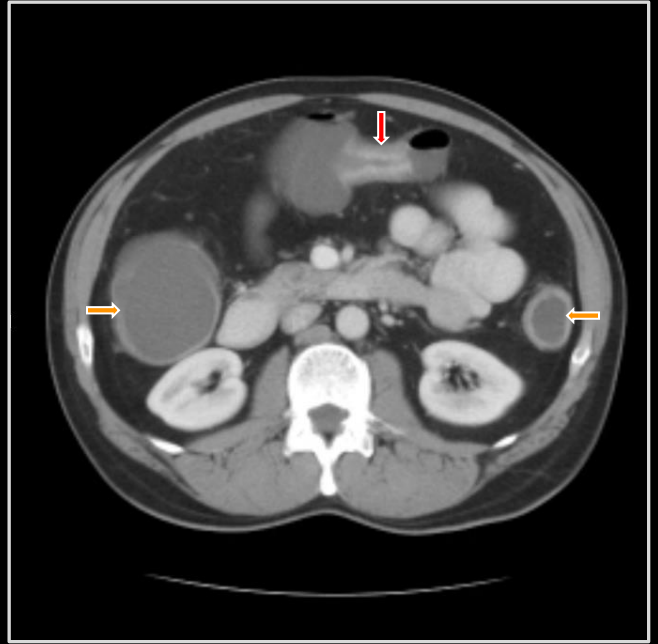
**Colon carcinoma recurrence,  
pseudomyxoma peritoneii**





Featureless/ahaustral colon  
Enhancing colon stricture

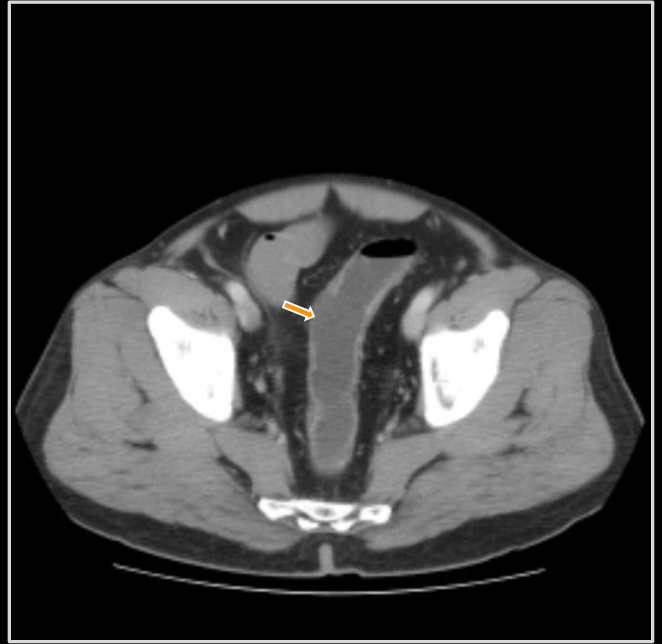
**Ulcerative colitis**

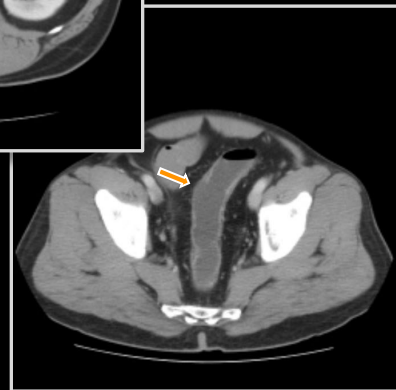
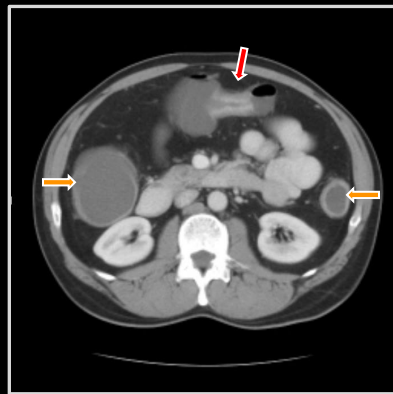
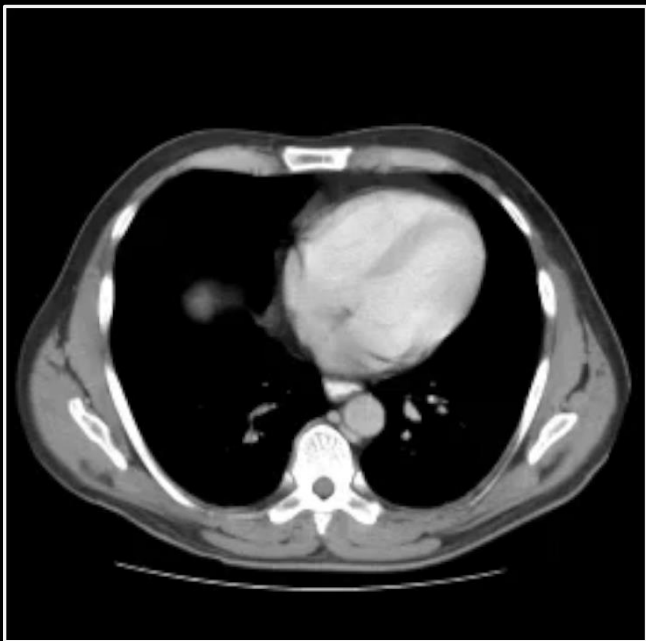




Featureless/ahaustral colon  
Enhancing colon stricture

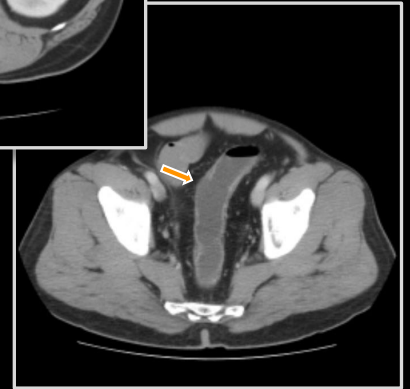
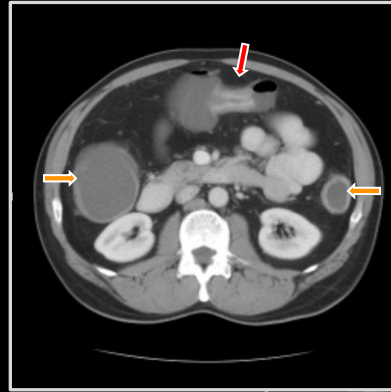
**Ulcerative colitis**





Featureless/ahaustral colon  
Enhancing colon stricture

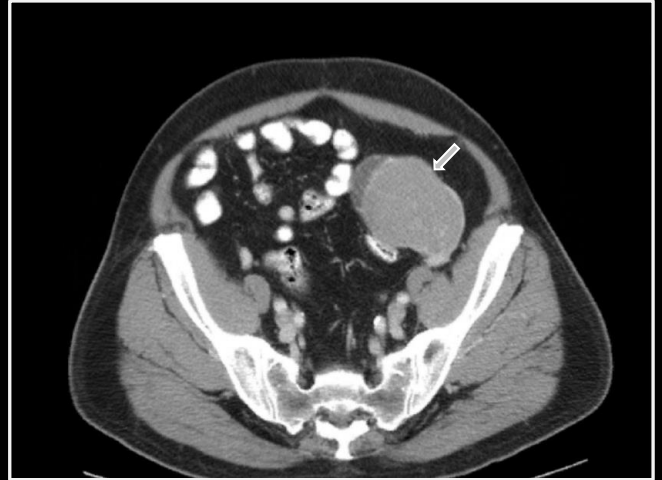**Ulcerative colitis**





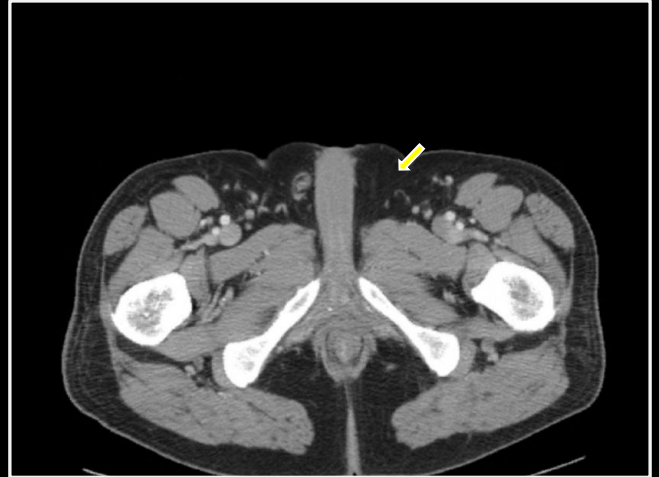
Pelvic mass  
Absent left spermatic cord

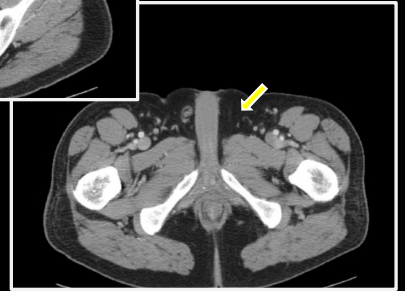
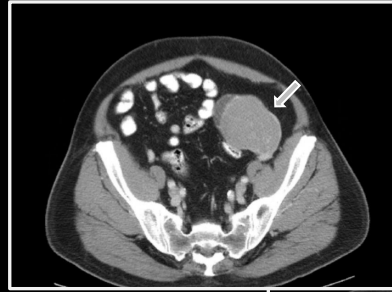
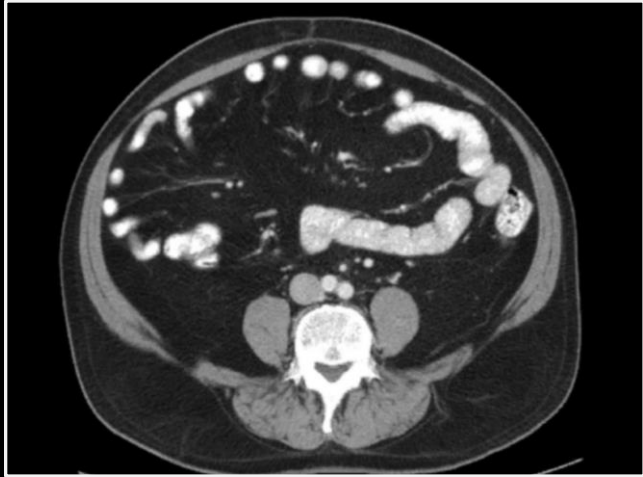**Seminoma**



Pelvic mass  
**Absent left spermatic cord**

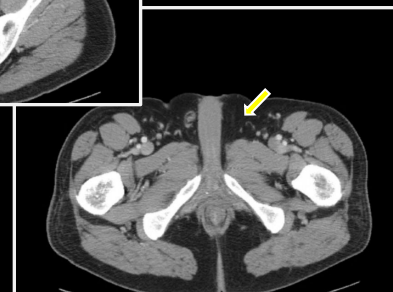
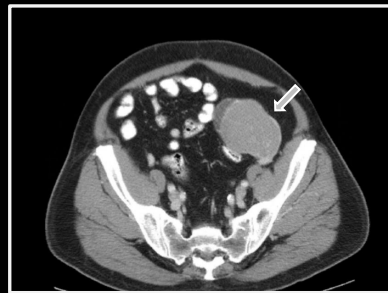**Seminoma**





Pelvic mass  
**Absent left spermatic cord**

**Seminoma**

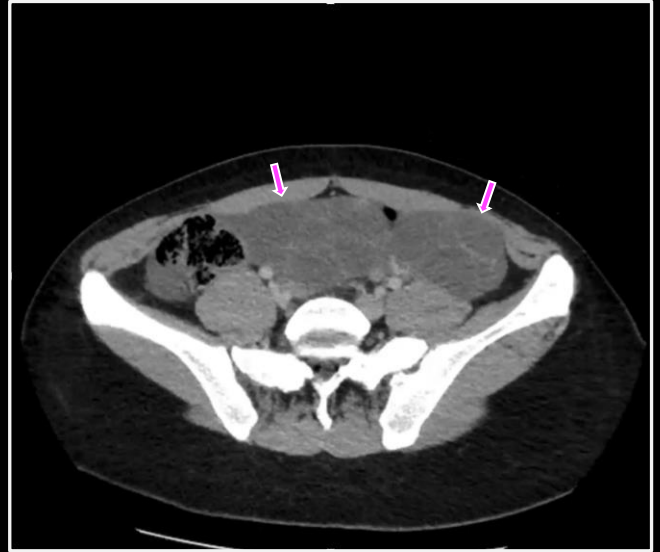






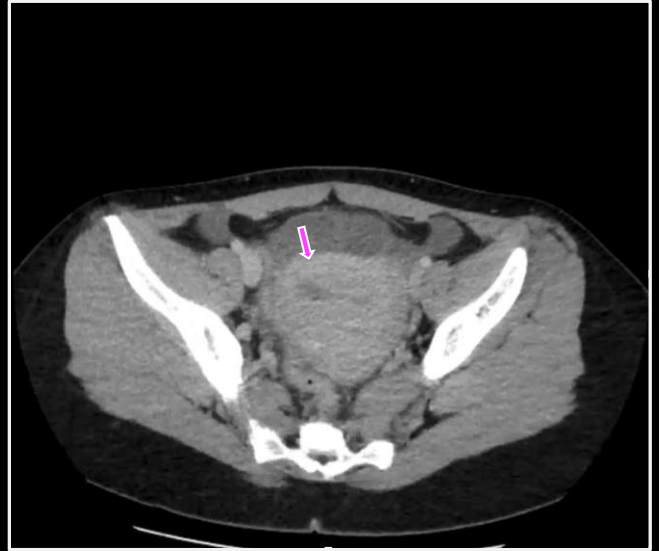Large ovaries and follicles  
Uterine mass with central cleft

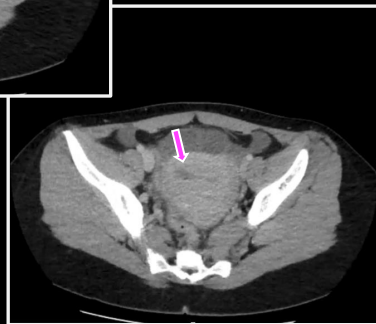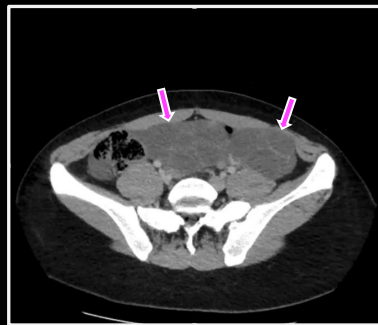
**Mole with hyperstimulation**



Large ovaries and follicles  
Uterine mass with central cleft

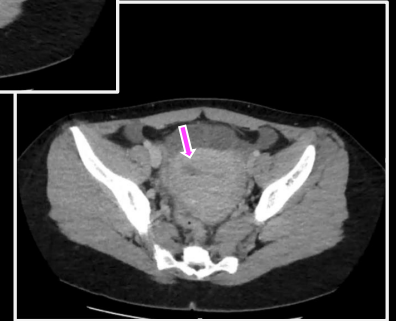
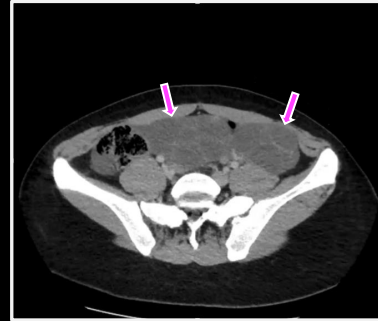
**Mole with hyperstimulation**





Large ovaries and follicles  
Uterine mass with central cleft

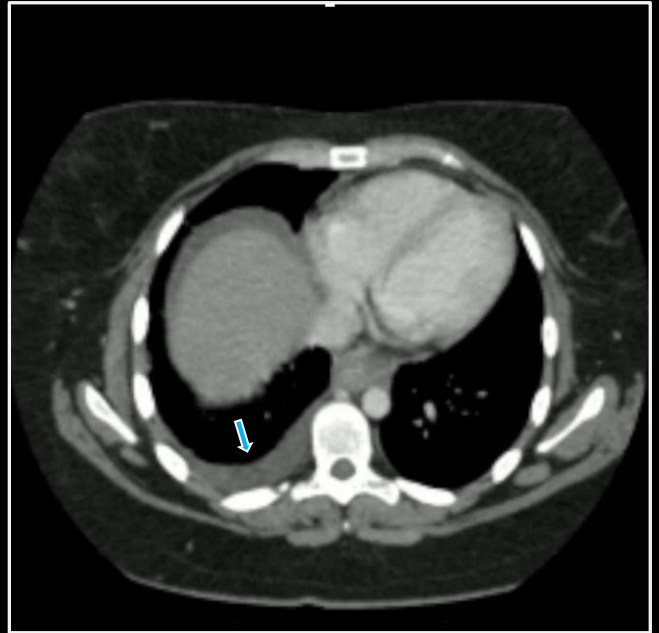
**Mole with hyperstimulation**





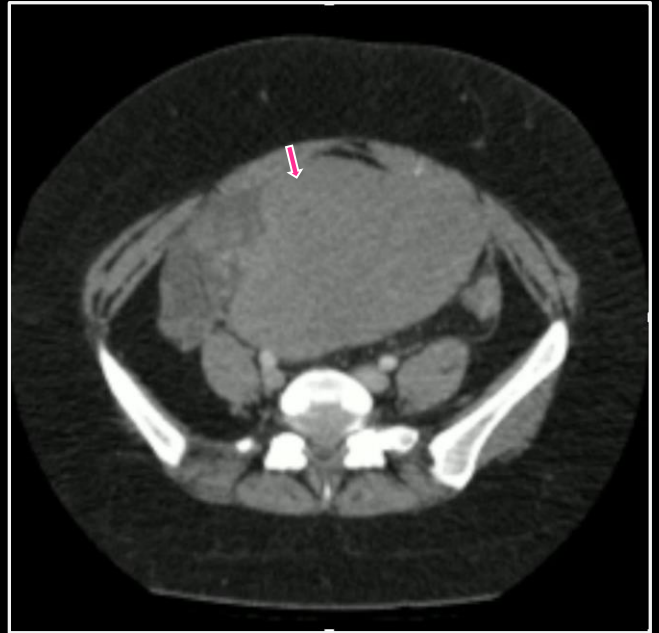
Pleural effusion  
Solid ovarian mass  
Ascites

**Meig syndrome**



Pleural effusion  
Solid ovarian mass  
Ascites

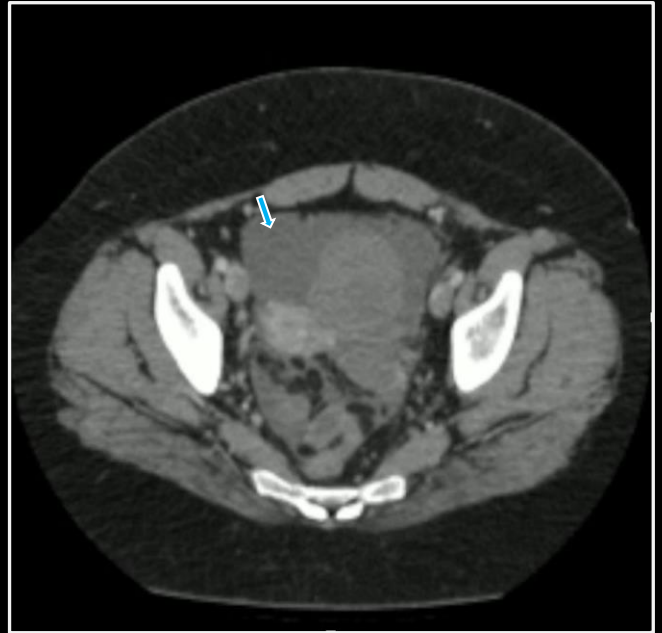
**Meig syndrome**

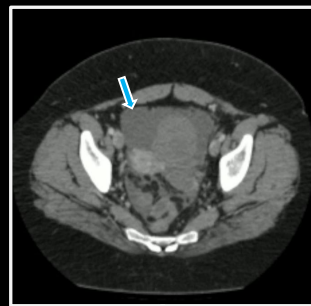
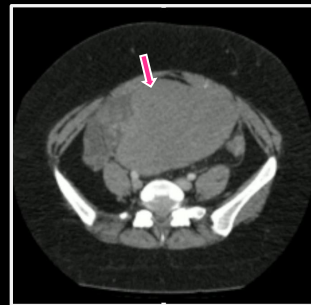
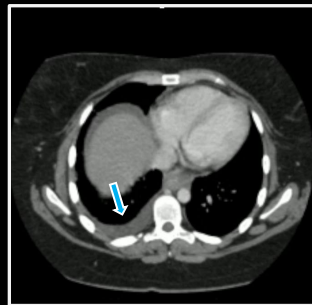
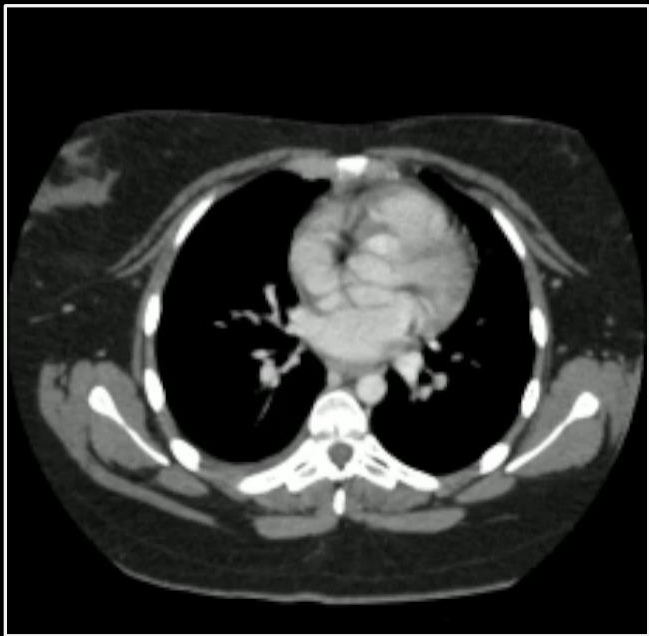




Pleural effusion  
Solid ovarian mass  
Ascites

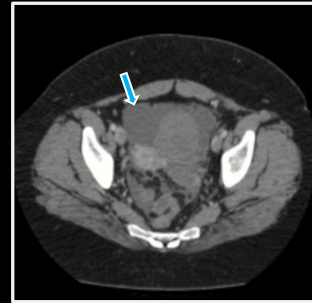
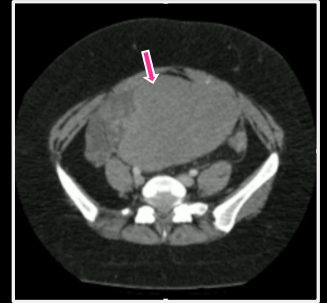
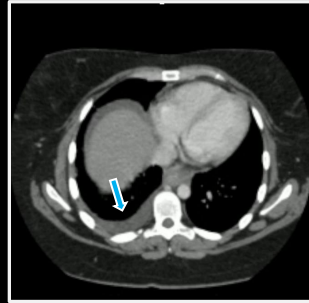
**Meig syndrome**





Pleural effusion  
Solid ovarian mass  
Ascites

**Meig syndrome**



# **“Instant Diagnosis” Neoplasms**

**Benjamin W. Strong, MD**