

# Musculoskeletal infections

Manickam “Nicks” Kumaravel MD

Professor of Radiology & Orthopedics

Sports, Orthopedic & Emergency Imaging

# Disclosure

No financial conflict of interest

# Objectives

- Understand the pathophysiology of MSK infections - soft tissue/bone/joint
  - Proficient in interrogating cross-sectional imaging for MSK infections *MRI*
  - Making the call – when to reach for the phone?
  - ***Clinical focus***
-

# MSK infections!

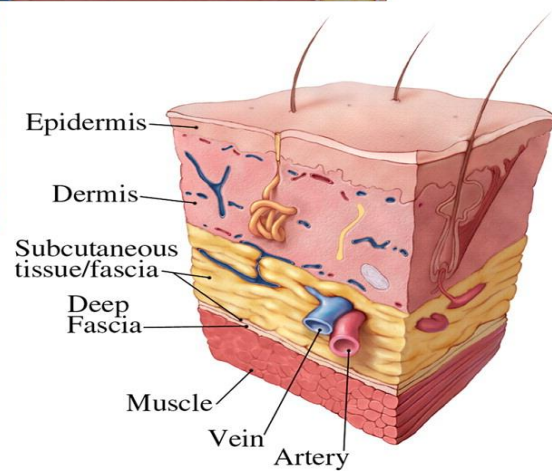
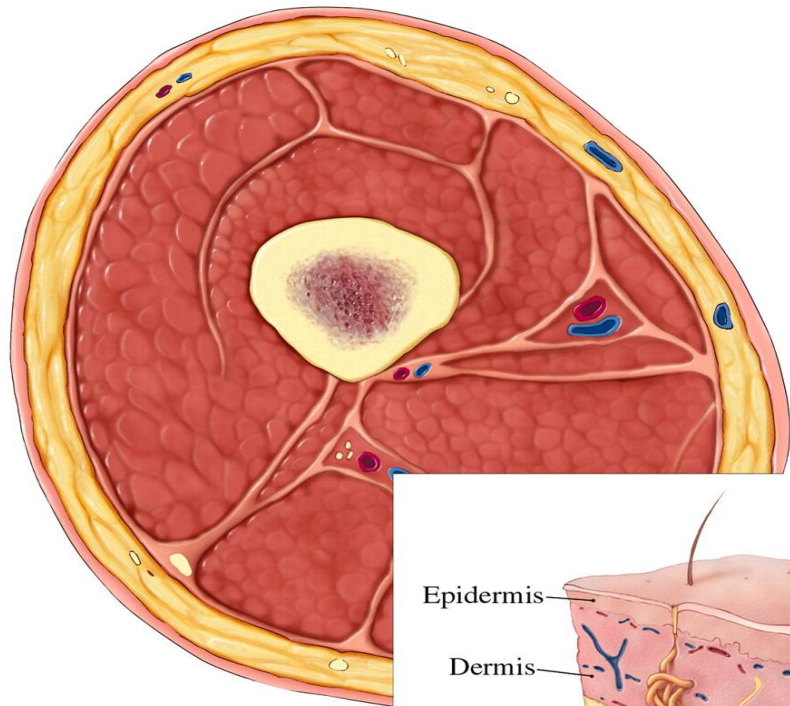
- Superficial cellulitis
- Necrotizing fasciitis
- Myositis
- Pyomyositis
- Soft tissue abscess
- *Osteomyelitis*
- *Septic arthritis*

# Soft tissue infections

---

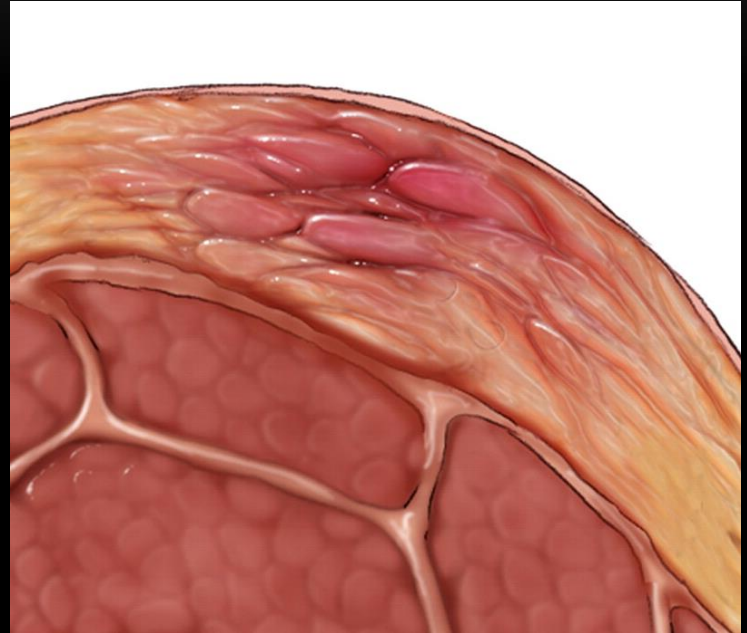
# Soft tissue infections!

- Superficial cellulitis
  - Necrotizing fasciitis
  - Myositis / Pyomyositis
  - Soft tissue abscess
-

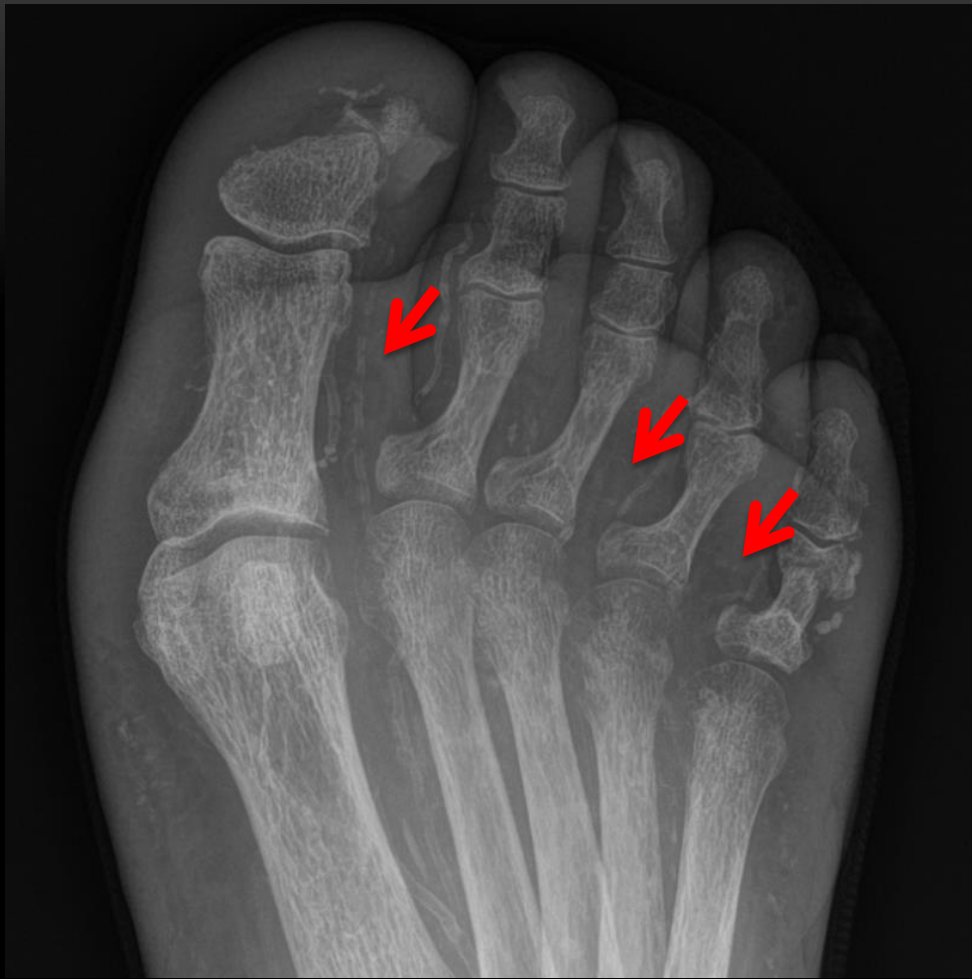

# Cellulitis

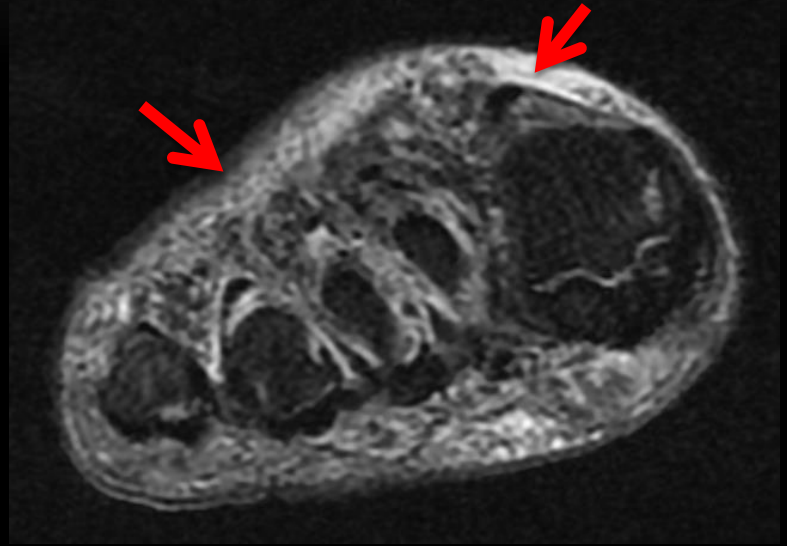
- Pain, erythema, warmth
- Staphylococcus aureus
- Risk = HIV, Diabetes, peripheral vascular disease
- Skin breach
- Rx – antibiotics, review





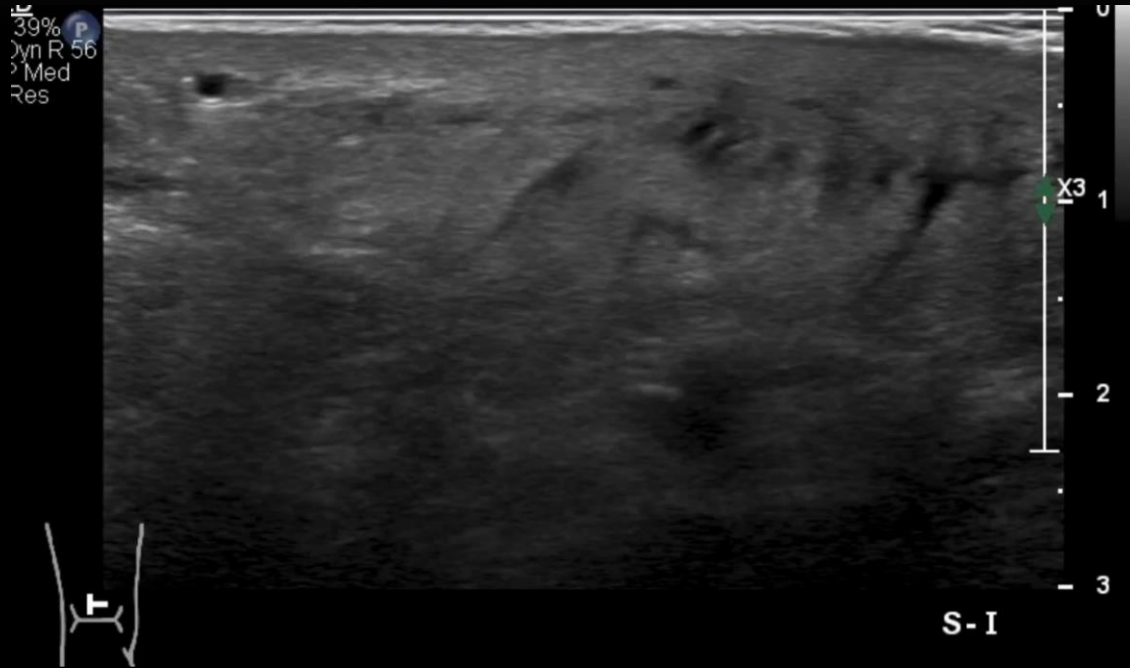


# Cellulitis



# Cellulitis - Ultrasound

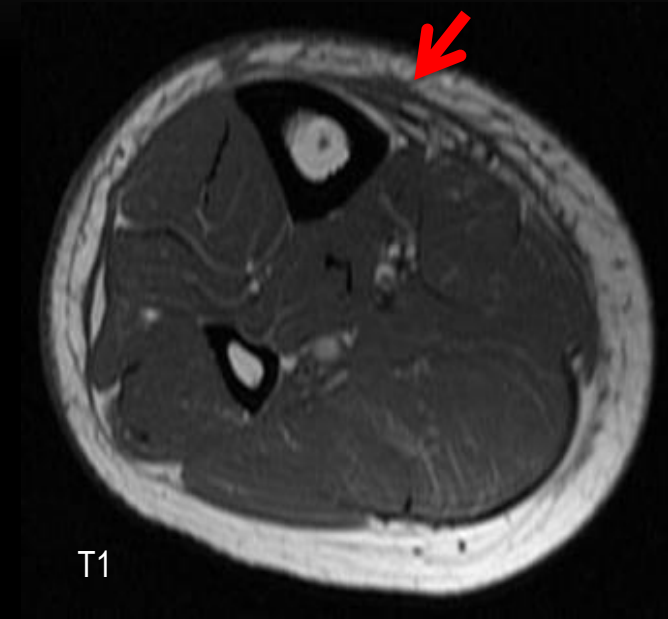
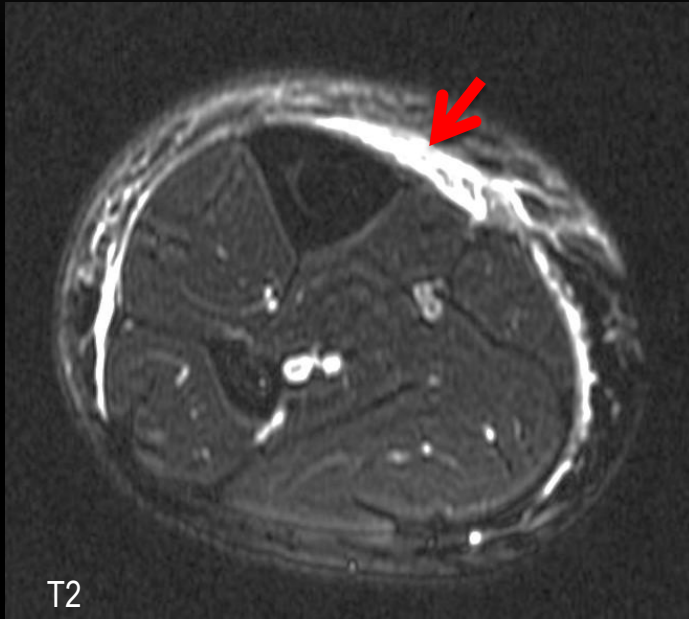
- Cobblestone appearance



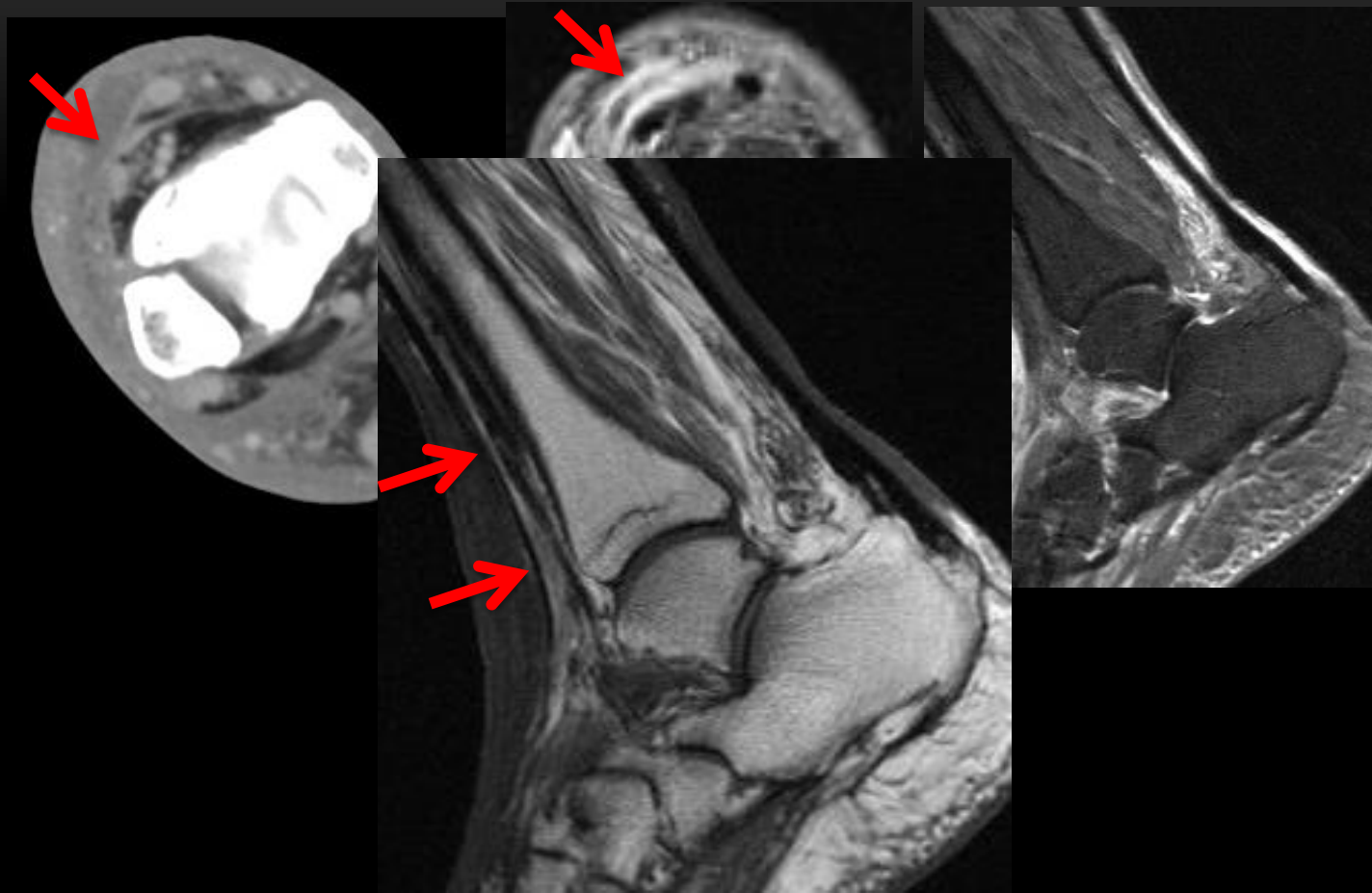
# Cellulitis - Imaging

- MRI
    - T2 increase signal
    - T1 hypointense
    - Increase sub Q enhancement with contrast
    - No **deep fascial** involvement
-

# Cellulitis



# Cellulitis + sub q fluid

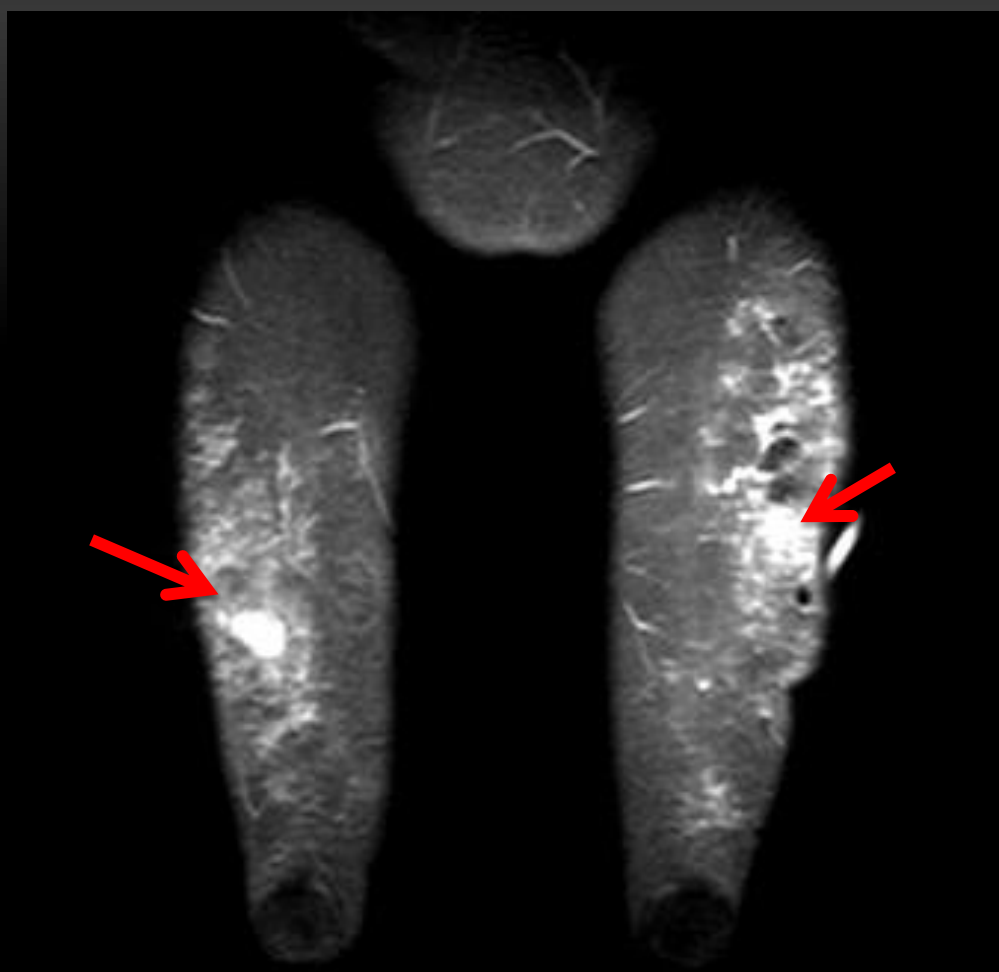


# What the clinicians what to know?

- Cellulitis
  - Extent
  - Any fluid collections superficial to deep fascia -  
? drainable
  - If follow up – progression / regression

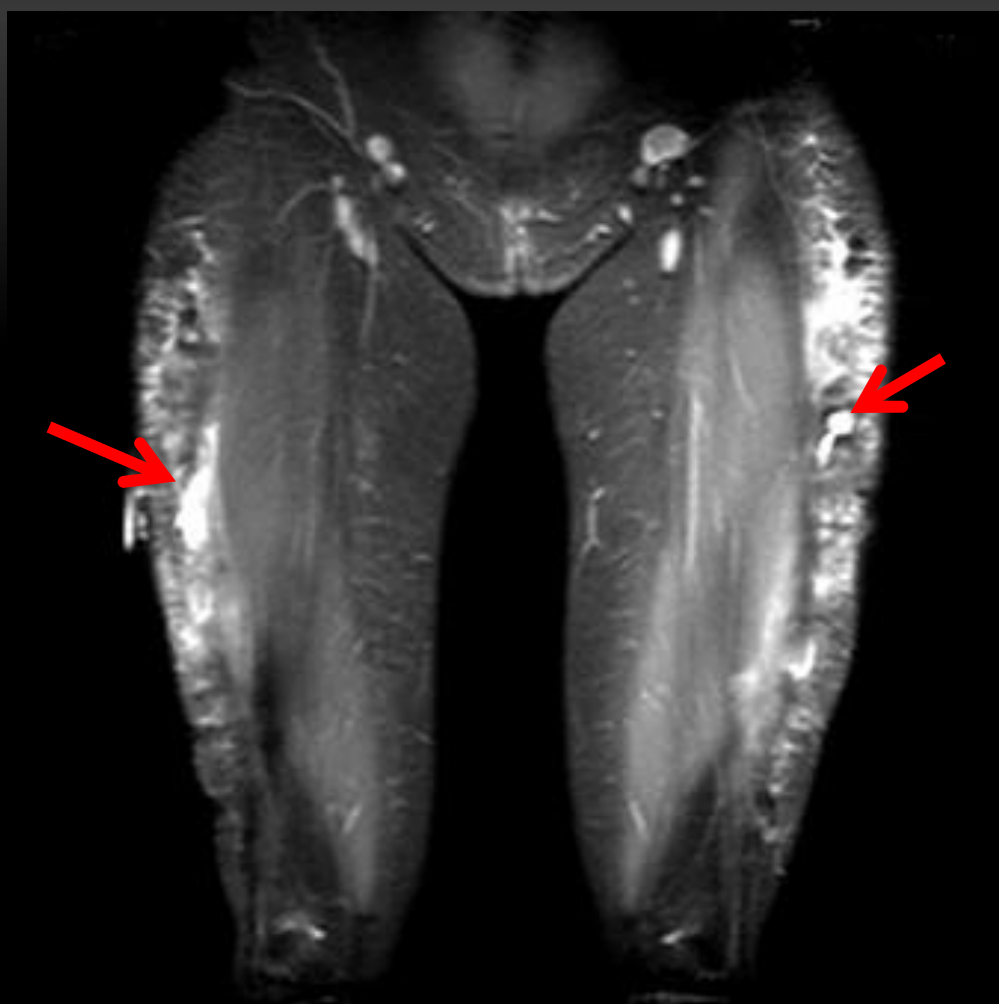
So what happens if the cellulitis  
spreads?

---

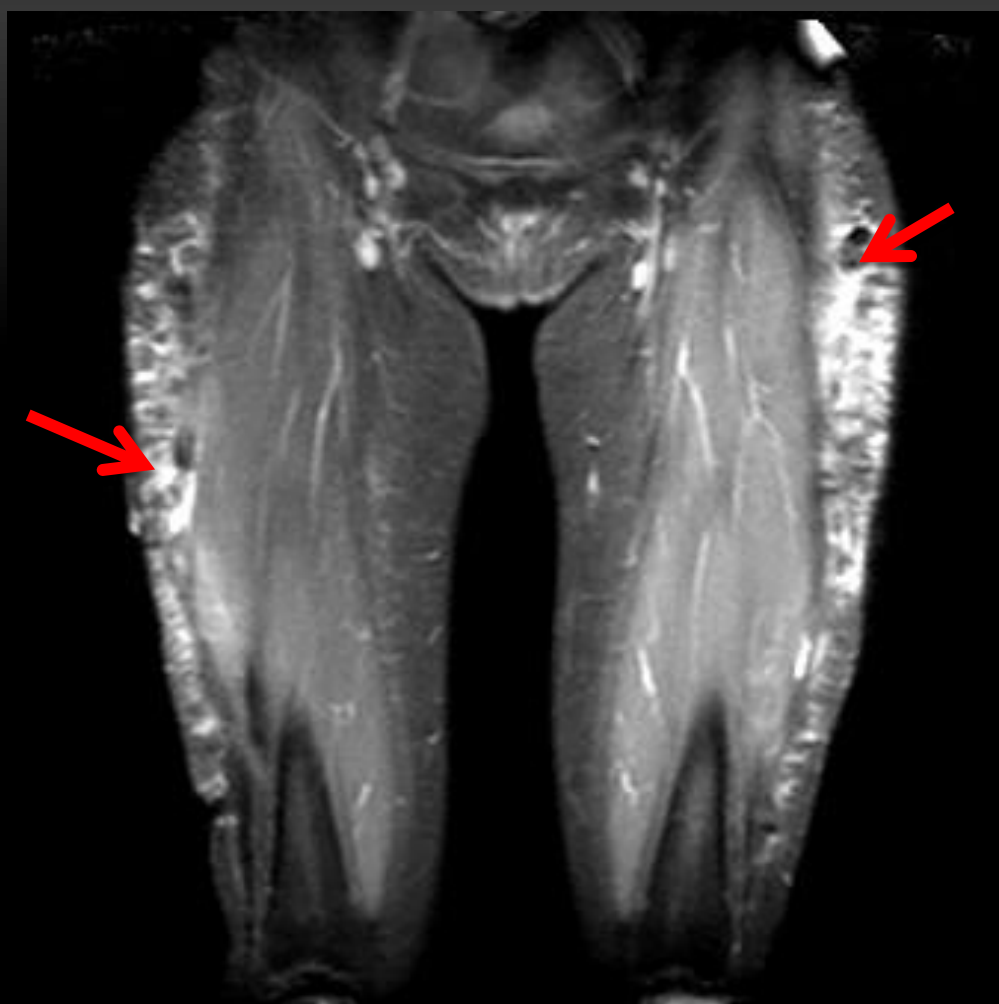


*33 yr old female*

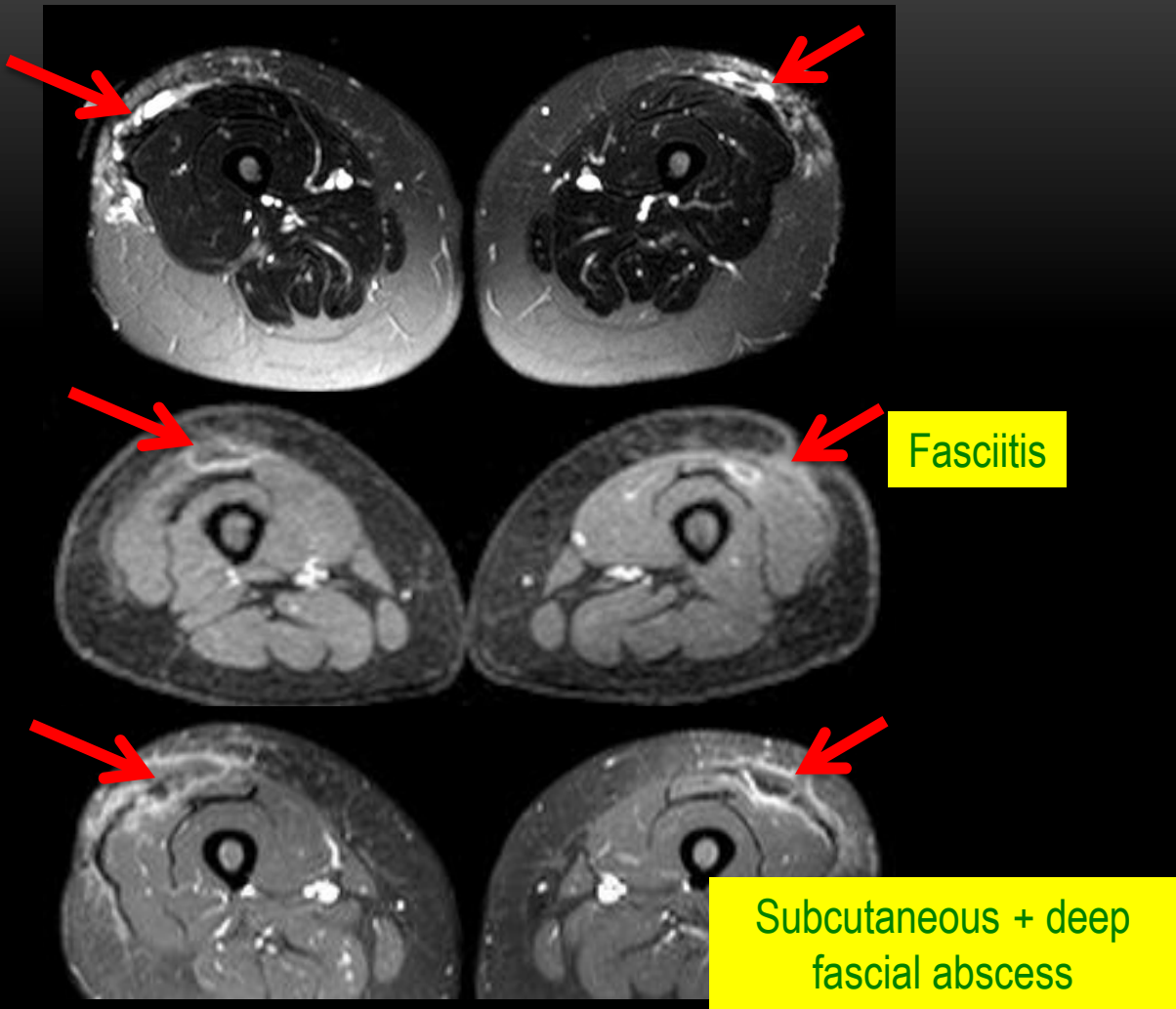




*33 yr old female*



*33 yr old female*



Fasciitis

Subcutaneous + deep fascial abscess

So now that we have breached the  
fascia.....

# Man contracts flesh-eating bacteria while cleaning dock in North Fort Myers

by Sarah Metts — 7:56 PM EST, Fri January 27, 2023

AA

3 NEWS

NEWS

WEATHER

FEATURES

TRAFFIC

GAME CENTER

WATCH

LIVE

## Lawsuit: Las Vegas woman with flesh-eating

SECTIONS



NEW YORK POST

g photo  
ndow  
dible...



Two Holland  
America workers who  
died on cruise were...



Israel uncovers heavy  
weapons cache at  
Gaza's largest...



Skier survives  
buried under a  
avalanche for

## Deadly flesh-eating infection spreading at record levels in Japan, puzzling health officials

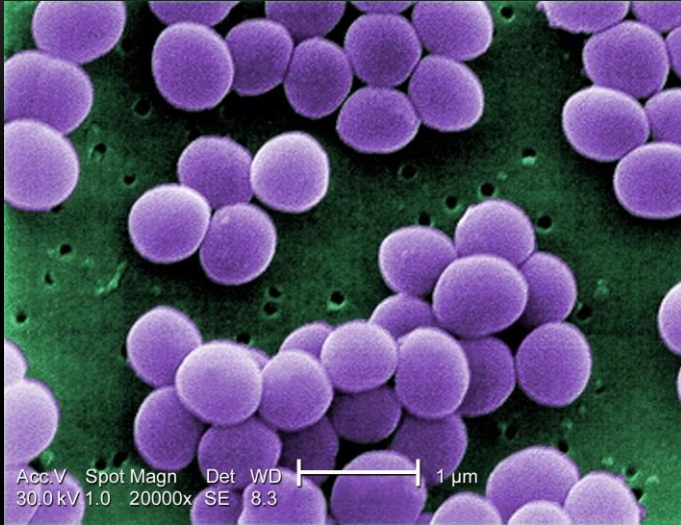
By Patrick Reilly

Published March 24, 2024, 2:17 a.m. ET

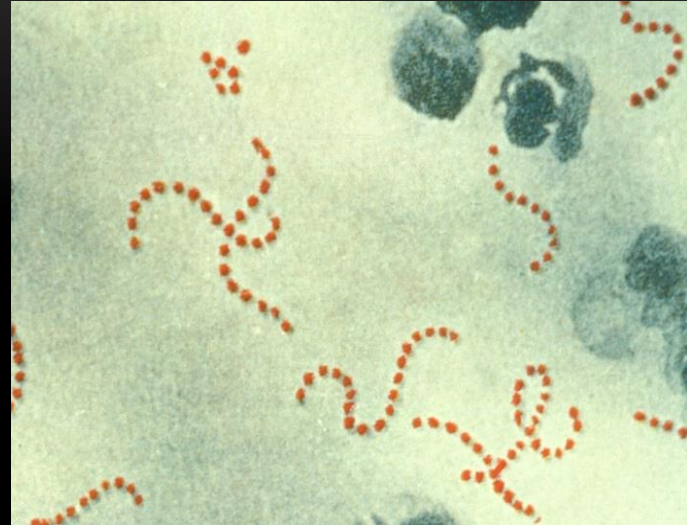So I guess I should pay more  
attention to these “flesh eating”  
monsters .....

---

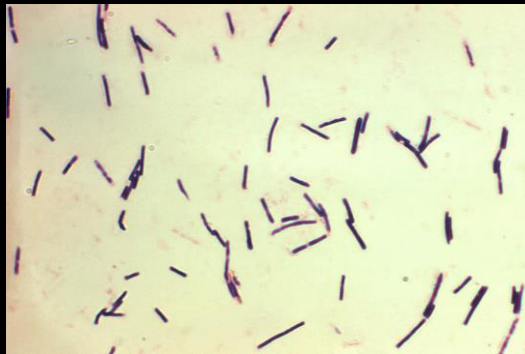# NECROTIZING FASCIITIS



Staph aureus



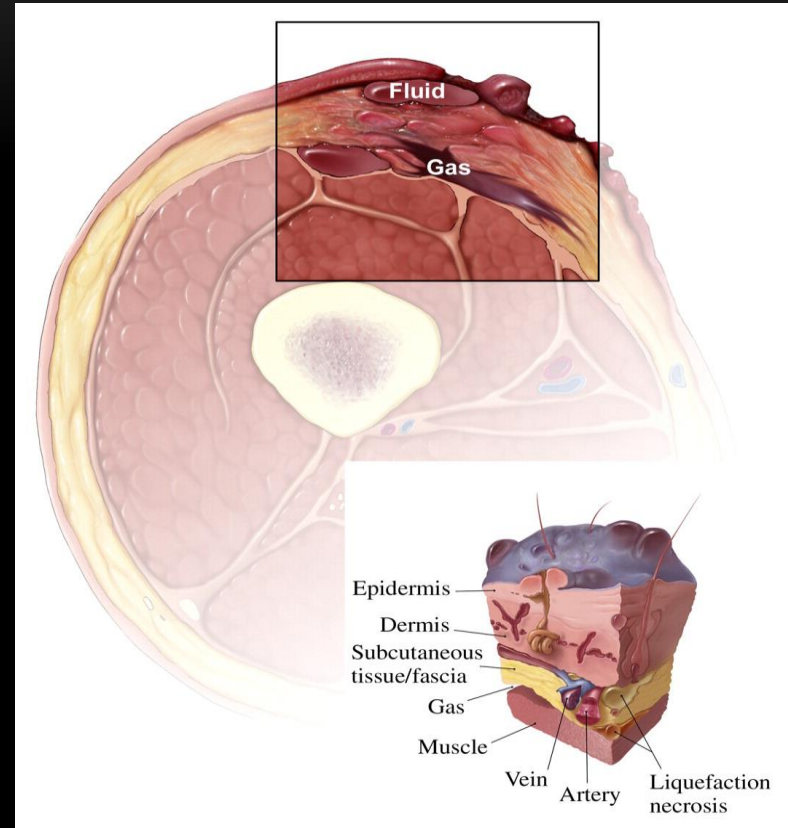
Strep pyogenes



Clostridium perfringens

# Necrotizing fasciitis

- Rapidly progressive infection of deep fascia
- Aerobic & gas forming anaerobic organisms
- Risk = HIV, diabetes, organ transplant, immunocompromised
- Morbidity & mortality – high 60 – 80%
- **DO NOT DELAY**

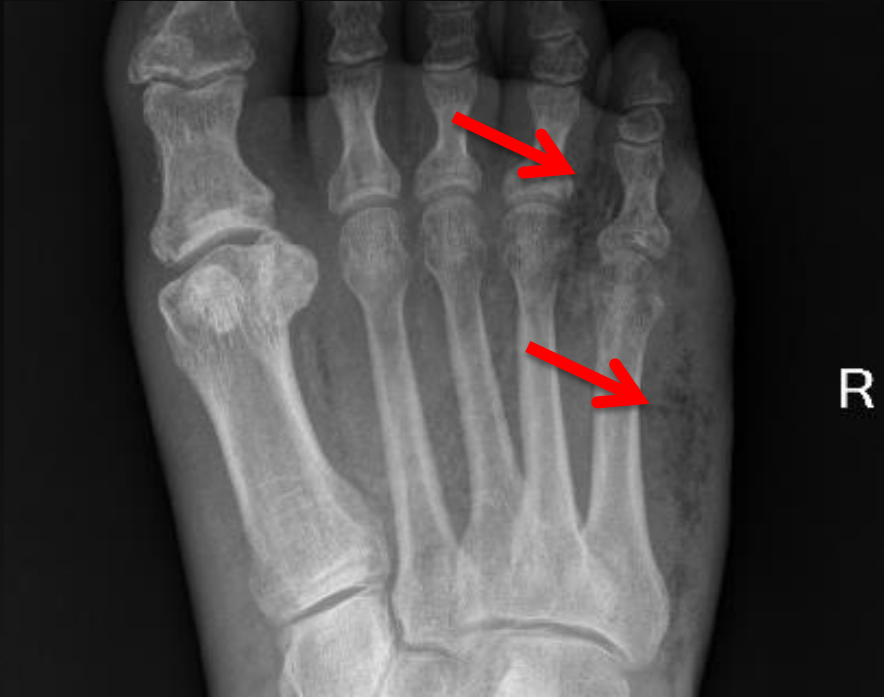
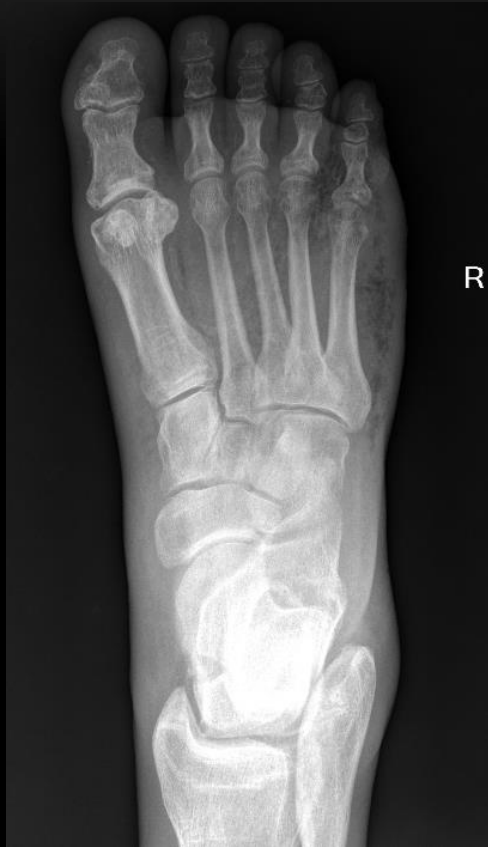


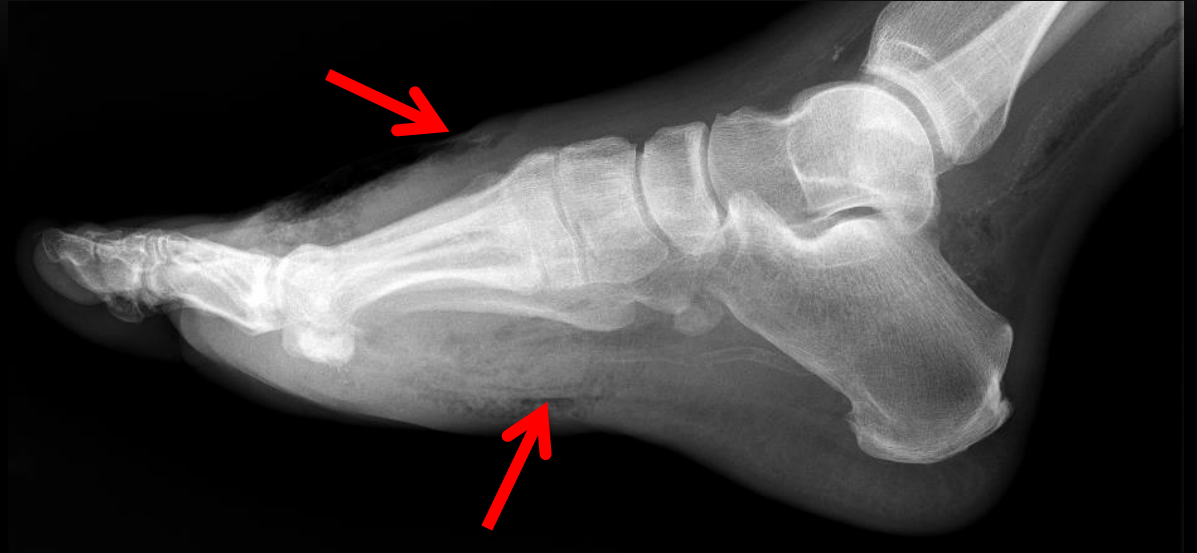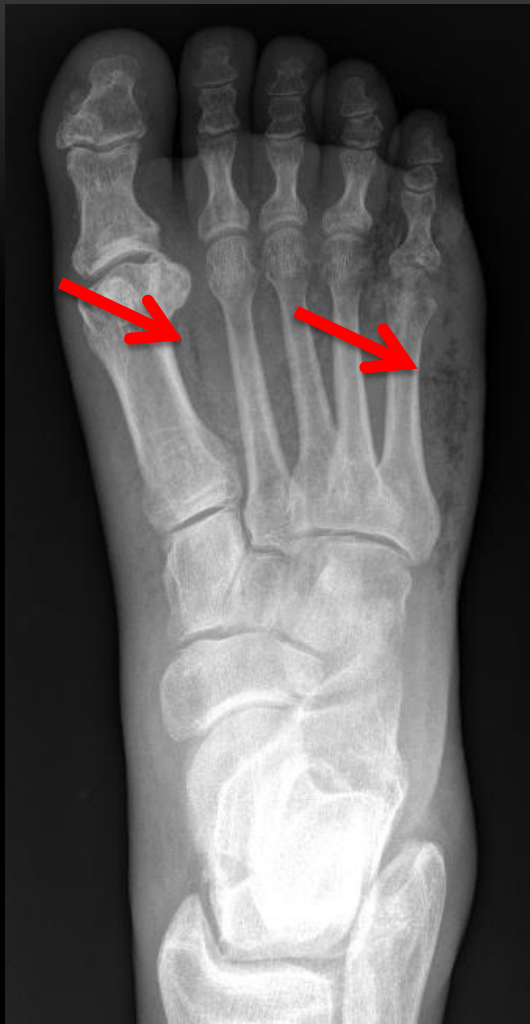# Necrotizing fasciitis ... clinical + lab

- Laboratory Risk Indicator for Necrotizing Fasciitis (LRINEC) score > 6 ( Sen 68.2% and Spec 84.8%)
  - C-reactive protein, WBC count, Hb, Na, glucose, creatinine
- Soft-tissue swelling, erythema, pain, tenderness, fever
- Pain out of proportion to clinical findings
- Tenderness extending beyond region of skin manifestation
- Wooden hard feel of subcutaneous tissues

# Necrotizing fasciitis ... Commonest scenario...

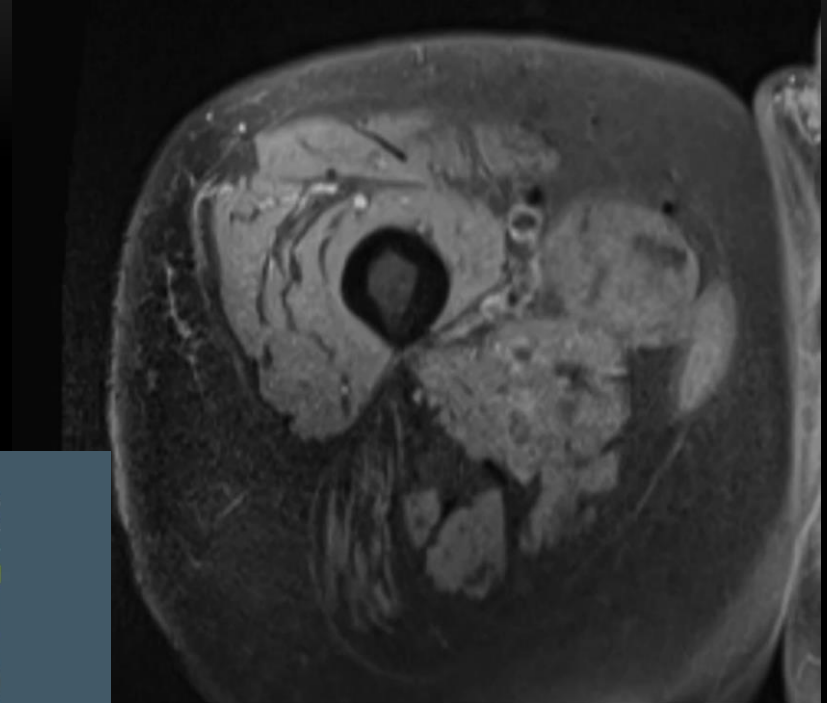
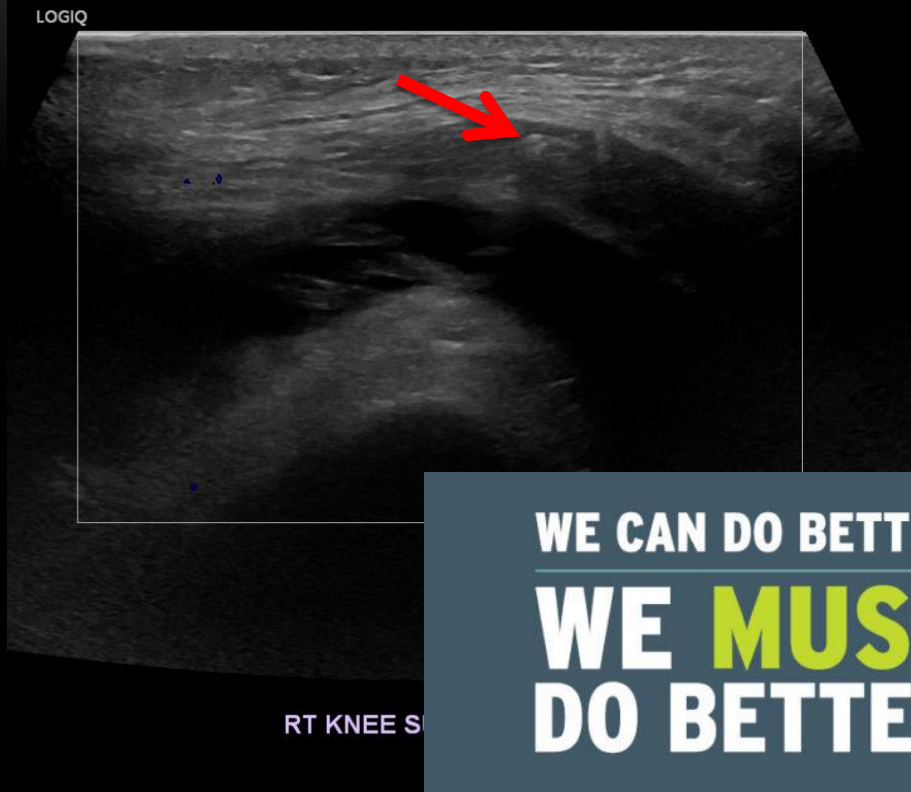


50-year male..... Diabetic



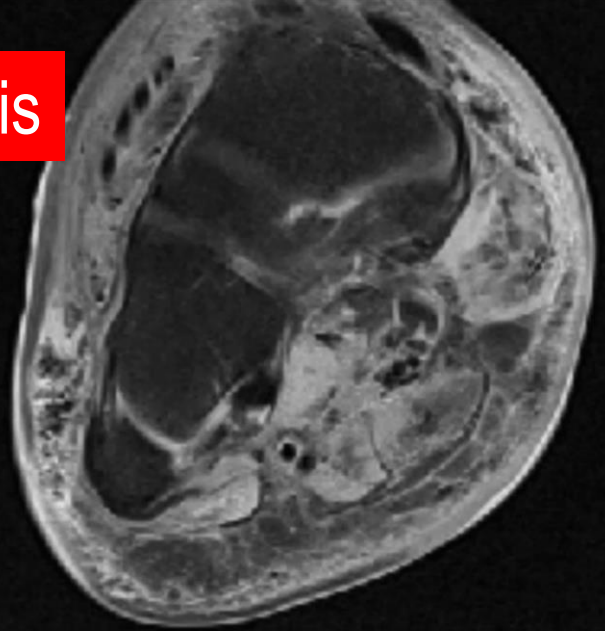
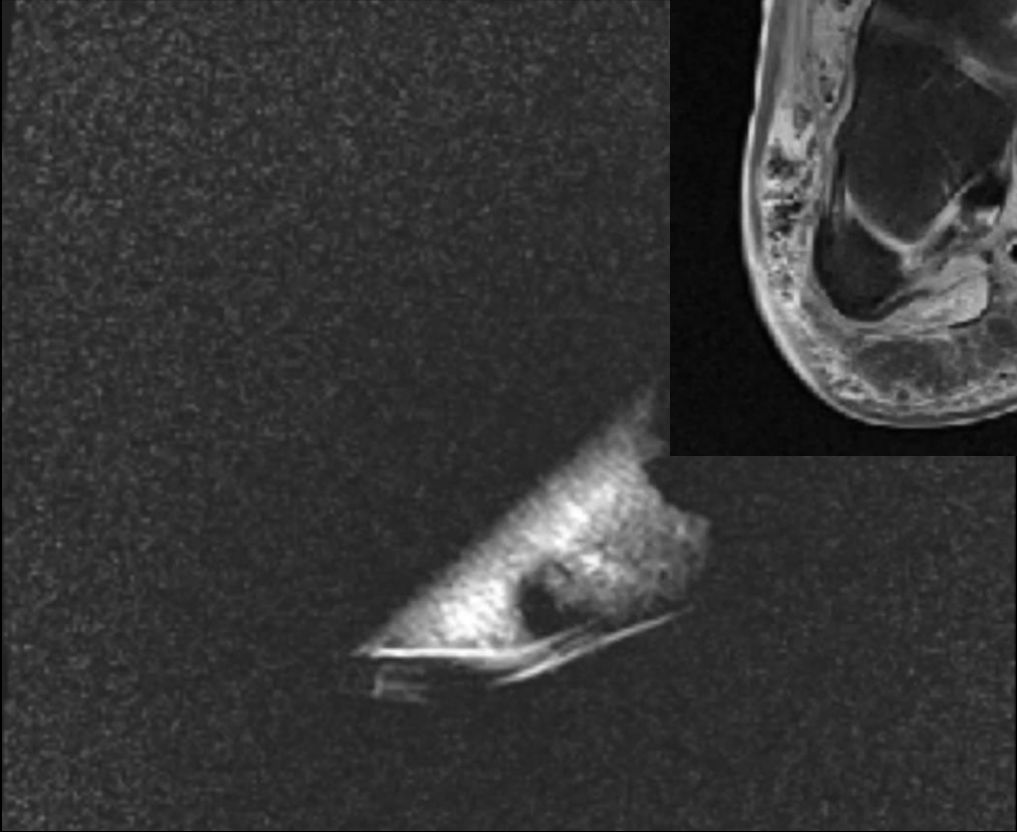
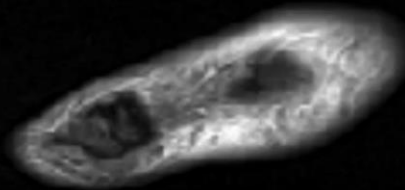
50-year male..... Diabetic

# Necrotizing fasciitis.. Gas in US and MRI



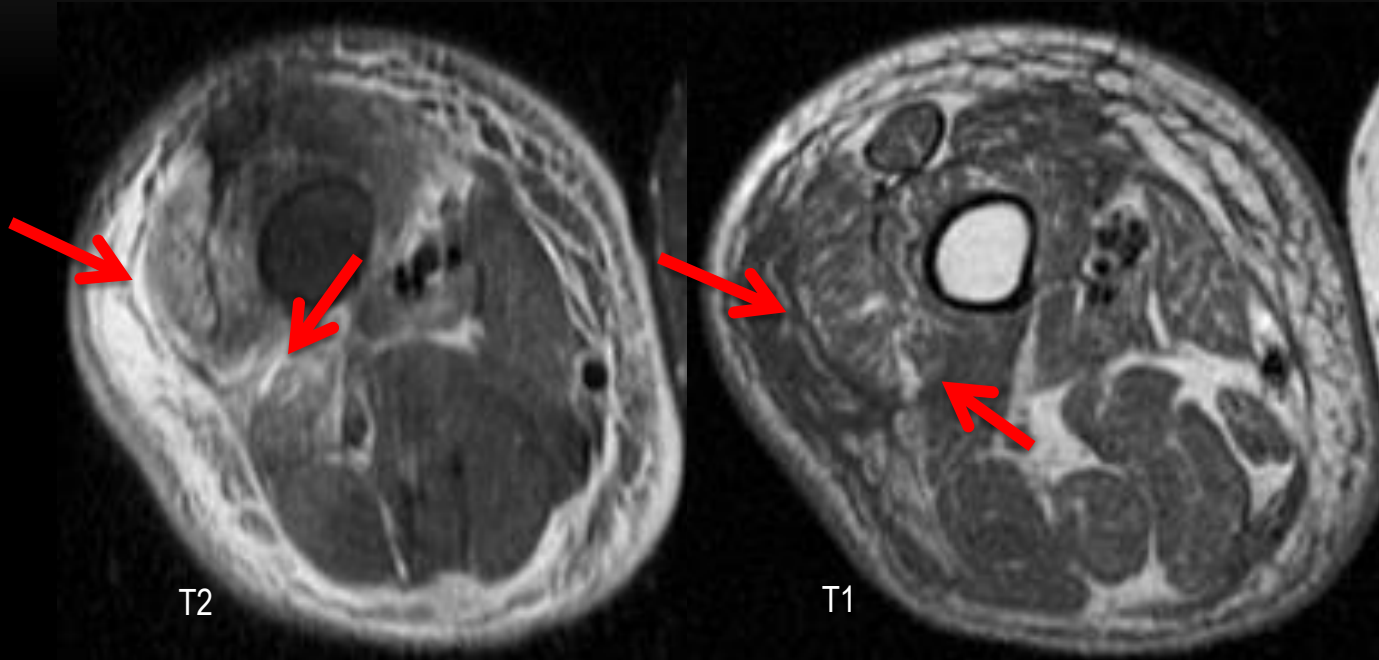
**WE CAN DO BETTER**  
**WE MUST**  
**DO BETTER**

# Necrotizing fasciitis

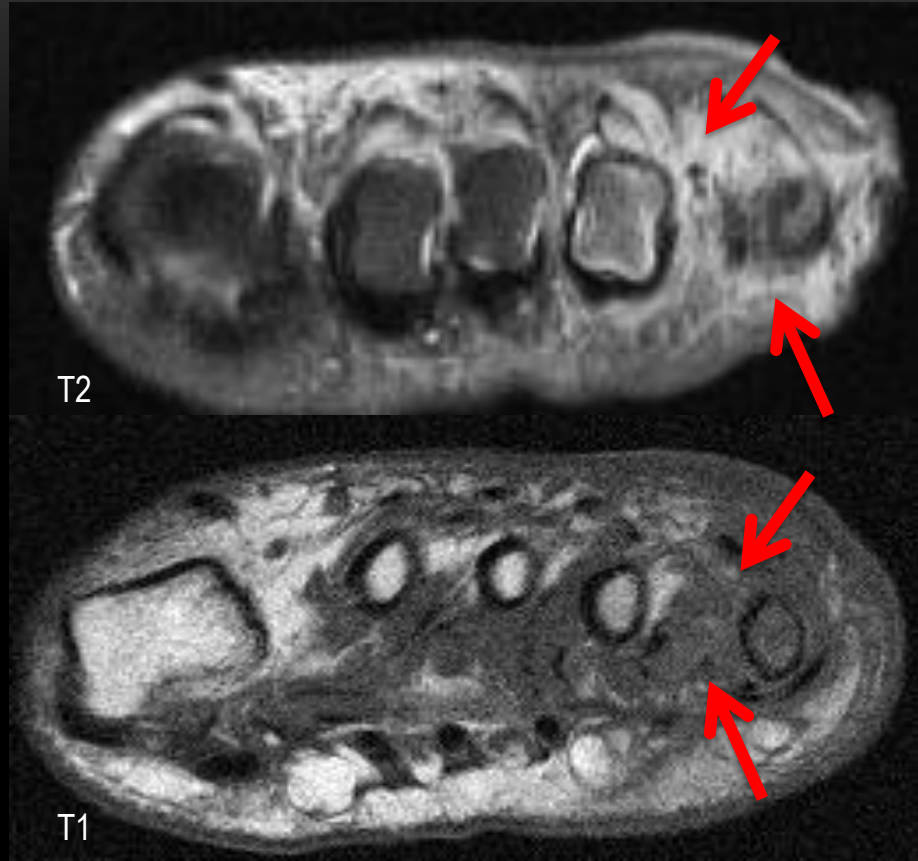
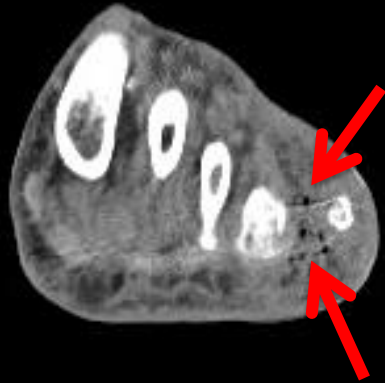
**MRI**

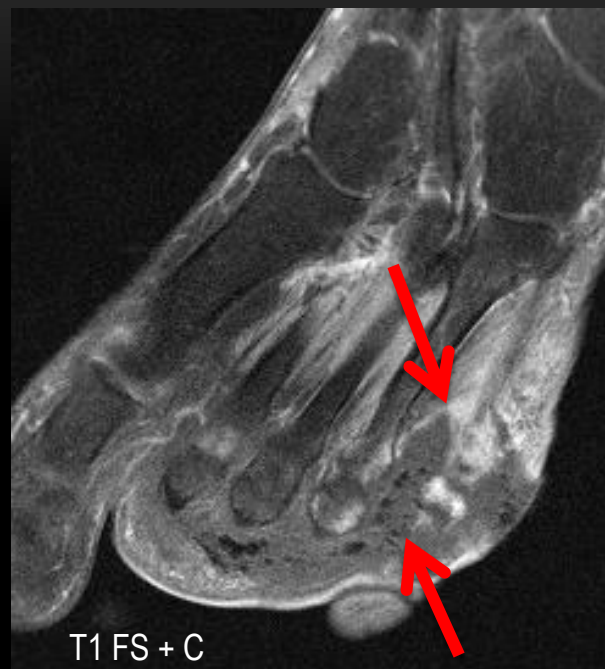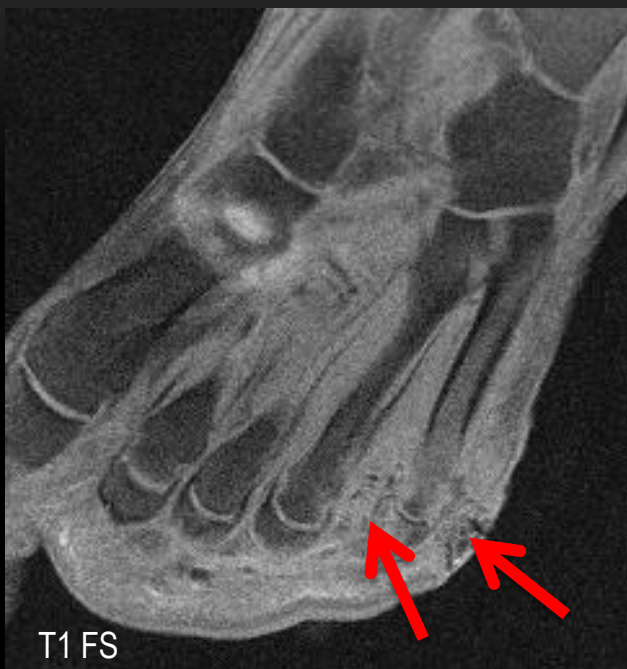# Necrotizing fasciitis



48 year male



56-year male..... Worsening process



Necrotizing fasciitis + myonecrosis + osteomyelitis

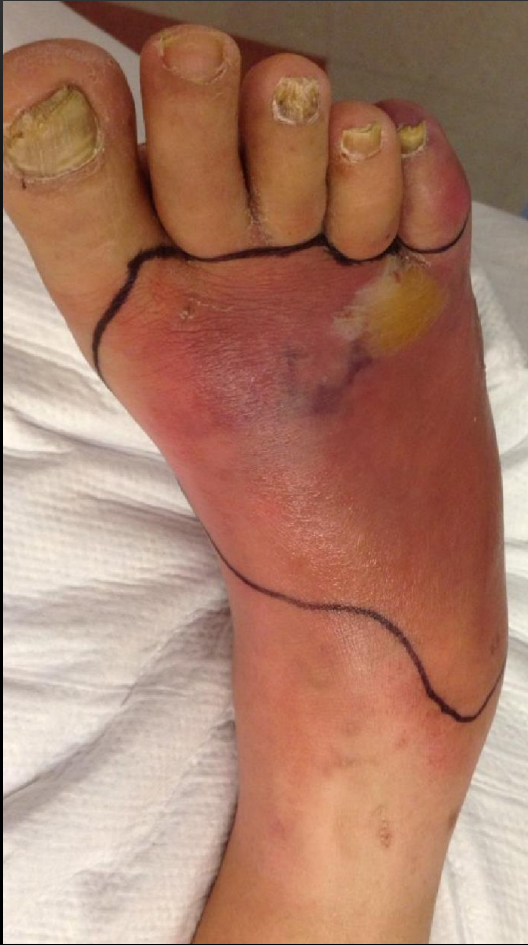.....56 year male



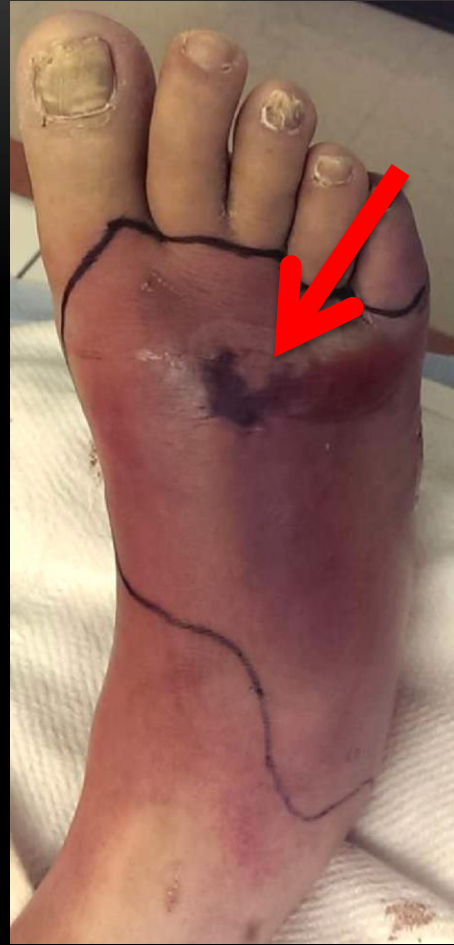# 58 year old Diabetic

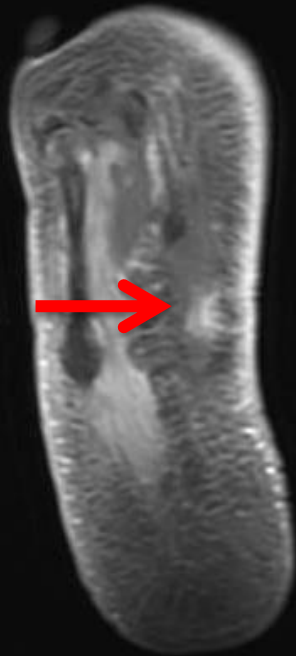Caution – Gross images !

---



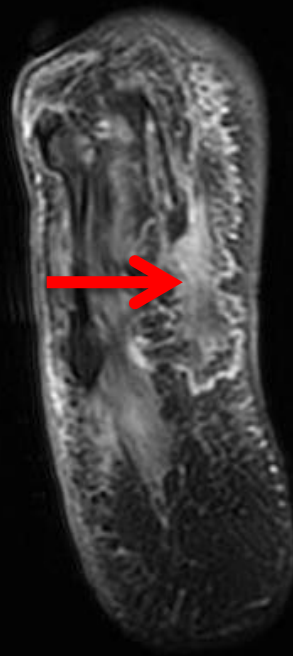
1 week





T1 FS + C

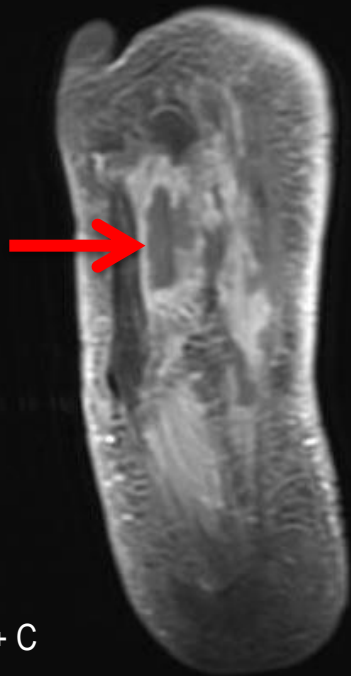: 11 of 36



T2 FS

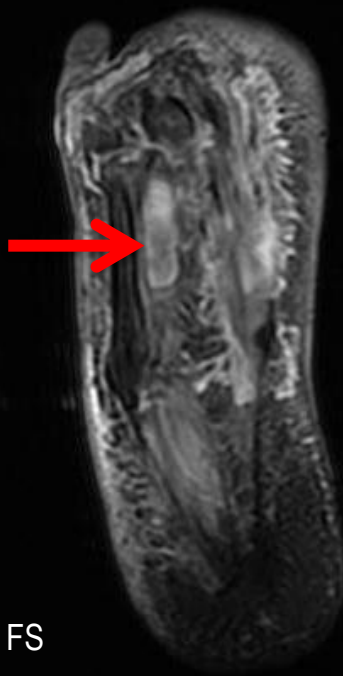
: 11 of 36

IM:11 4



T1 FS + C

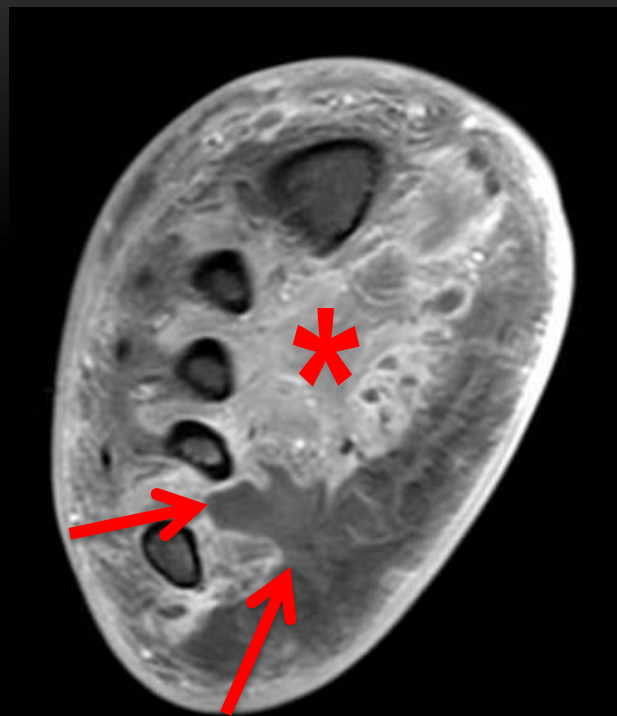
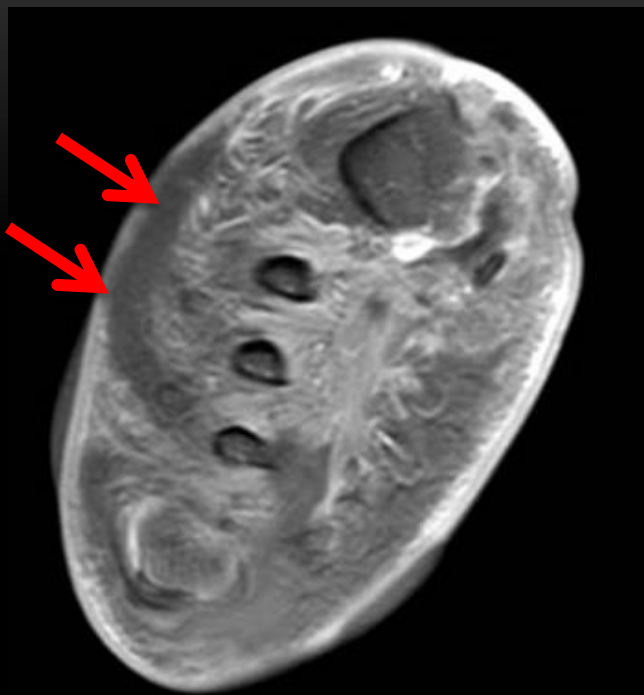: 12 of 36



T2 FS

: 12 of 36

IM:12



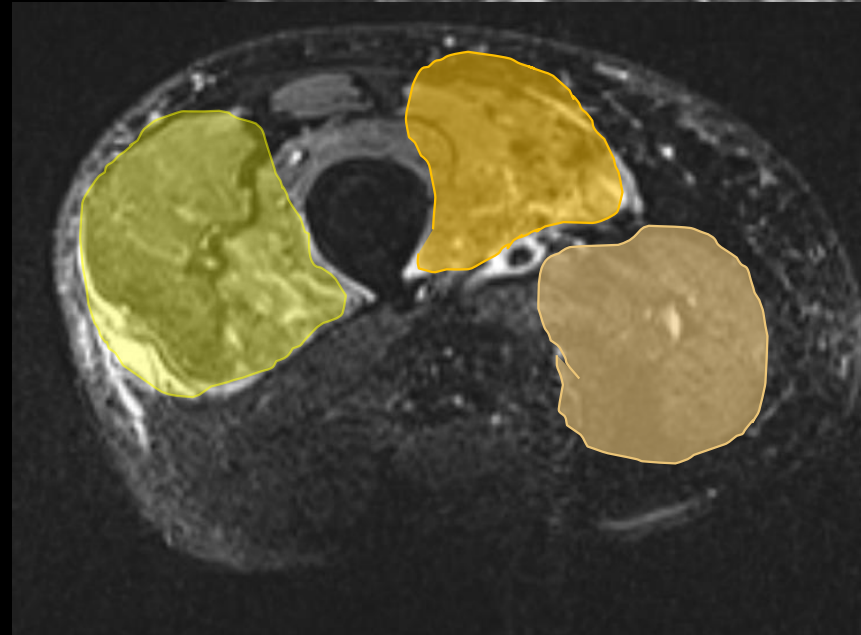
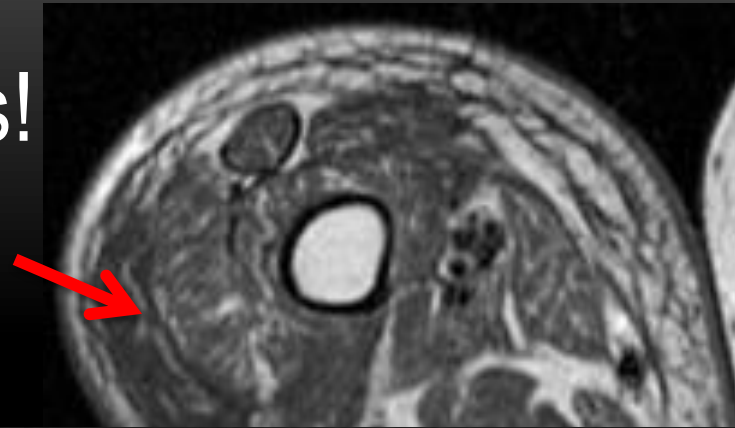
Necrotizing fasciitis



Amputation

# Necrotizing fasciitis – essentials!

- Thickening of deep fascia >3mm
- Fluid intermuscular
- 3 compartments
- Variable enhancement
- *Gas*
- Lab +MRI Sen 96% , Spec 60%



# What the clinicians what to know?

- Necrotizing fasciitis
  - Extent
  - Associated myonecrosis , osteomyelitis
  - Ominous signs – gas , abscess formation

Moving on to something that could be  
anywhere ..... literally

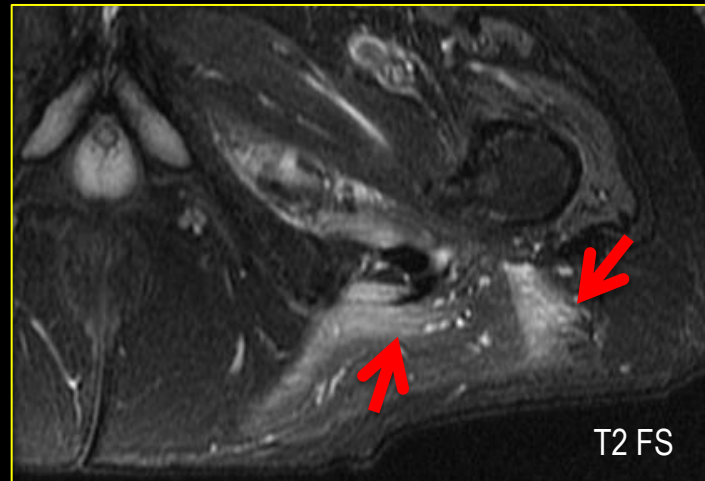
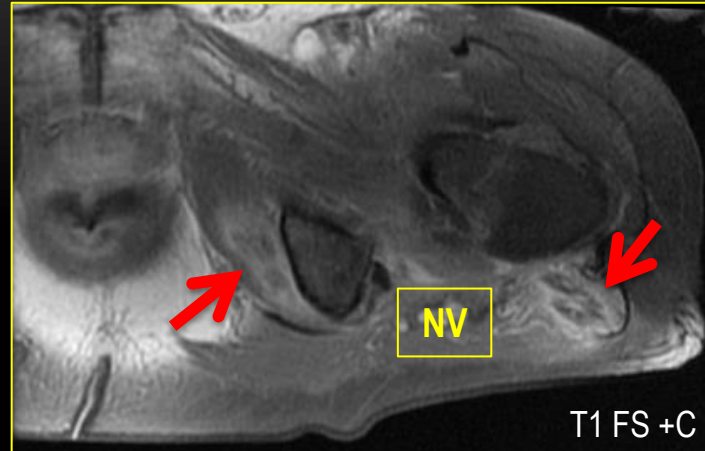
---



# Soft tissue abscess

68 yr old

- Staph aureus
- MRSA
- Immuno compromised
- What the clinicians want to know
  - Extent
  - Planes involved
  - Neurovascular structures
  - Walled off ?
  - Single / multiple



# What about diffusion-weighted imaging?

- Apparent Diffusion Coefficient (ADC) = quantitative parameter derived from DWI representing the degree of water molecule diffusion
- Osteomyelitis:  $0.9 - 1.5 \times 10^{-3} \text{ mm}^2/\text{s}$
- Septic arthritis:  $1.0 - 2.0 \times 10^{-3} \text{ mm}^2/\text{s}$
- Abscess:  $1.2 - 2.2 \times 10^{-3} \text{ mm}^2/\text{s}$

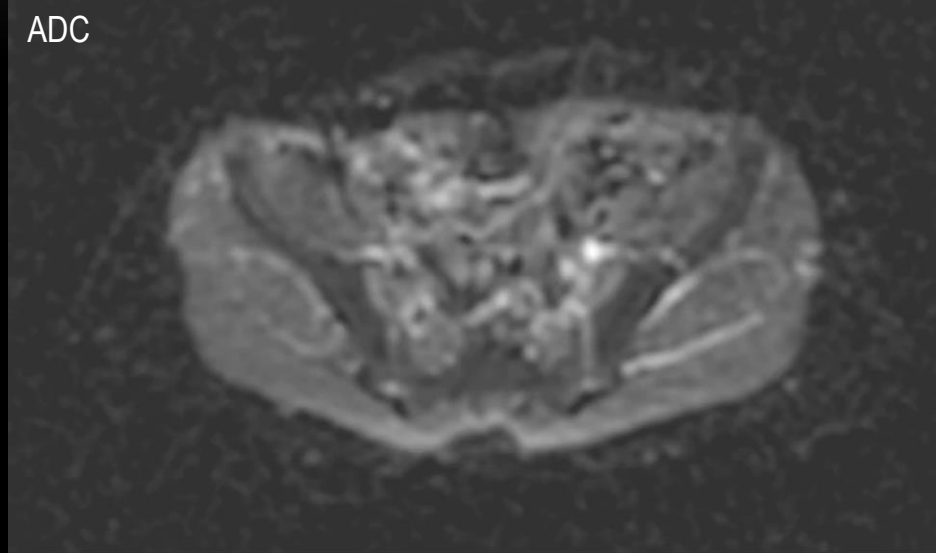
# Diffusion weighted imaging

*10 yr old*

DWI b750



ADC



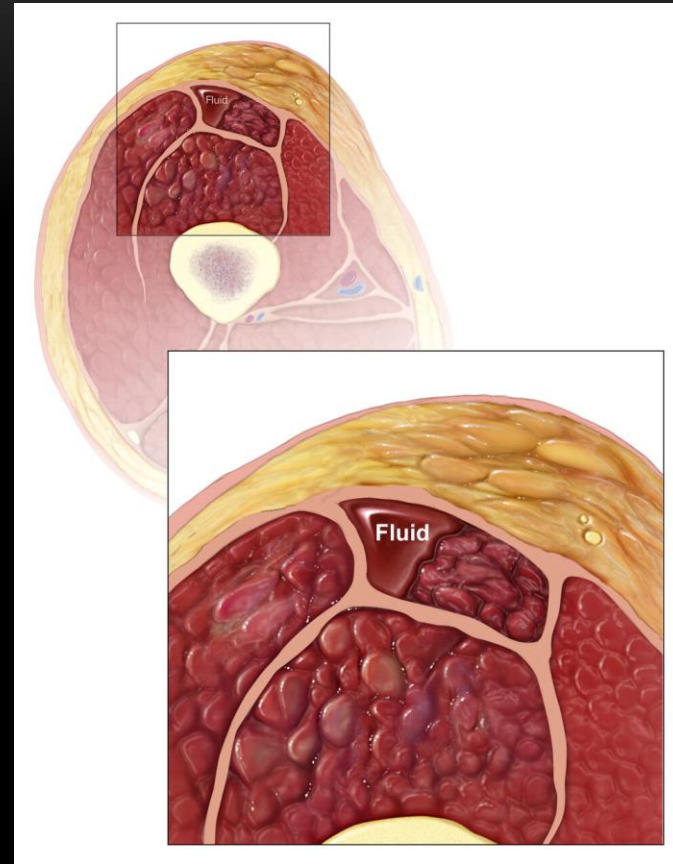
Right Quad plate osteo + early Obt internus abscess

Moving on to muscle.....

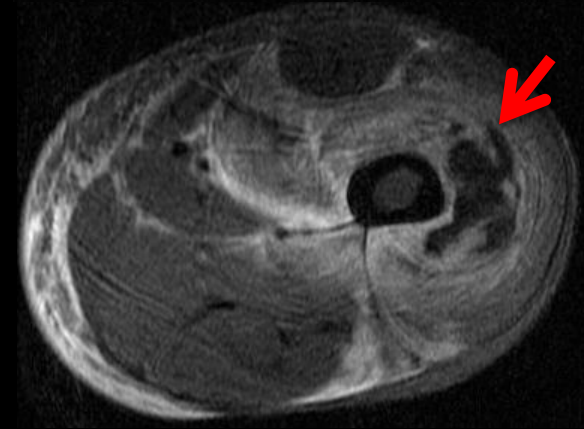
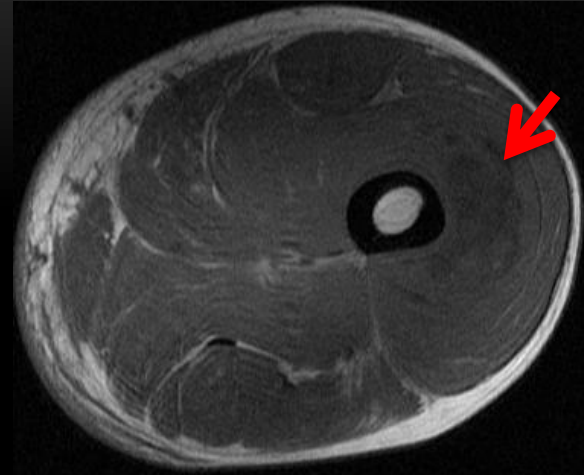
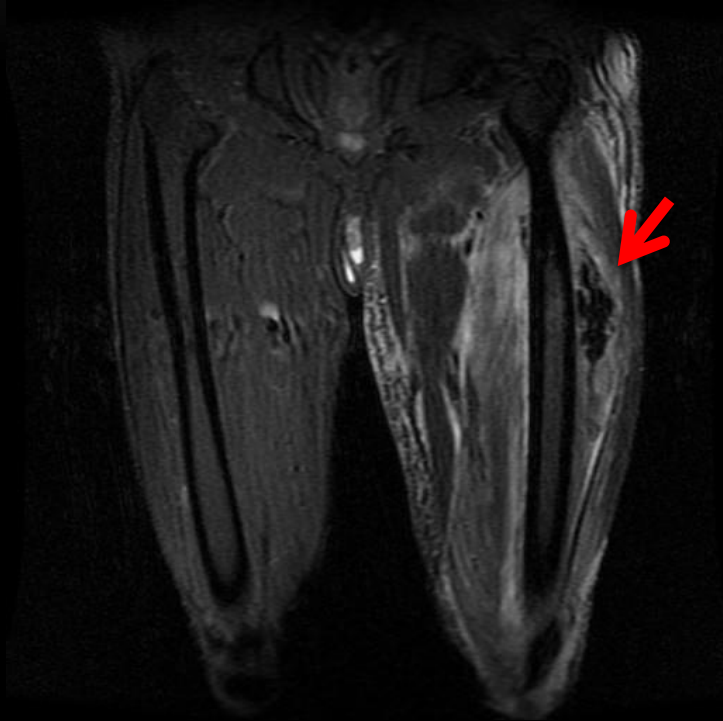---

# Myositis / pyomyositis

- Staph aureus
- Invasive → Suppurative  
→ bacteremia / septic
- Immunocompromised,  
muscle trauma,  
injections predispose

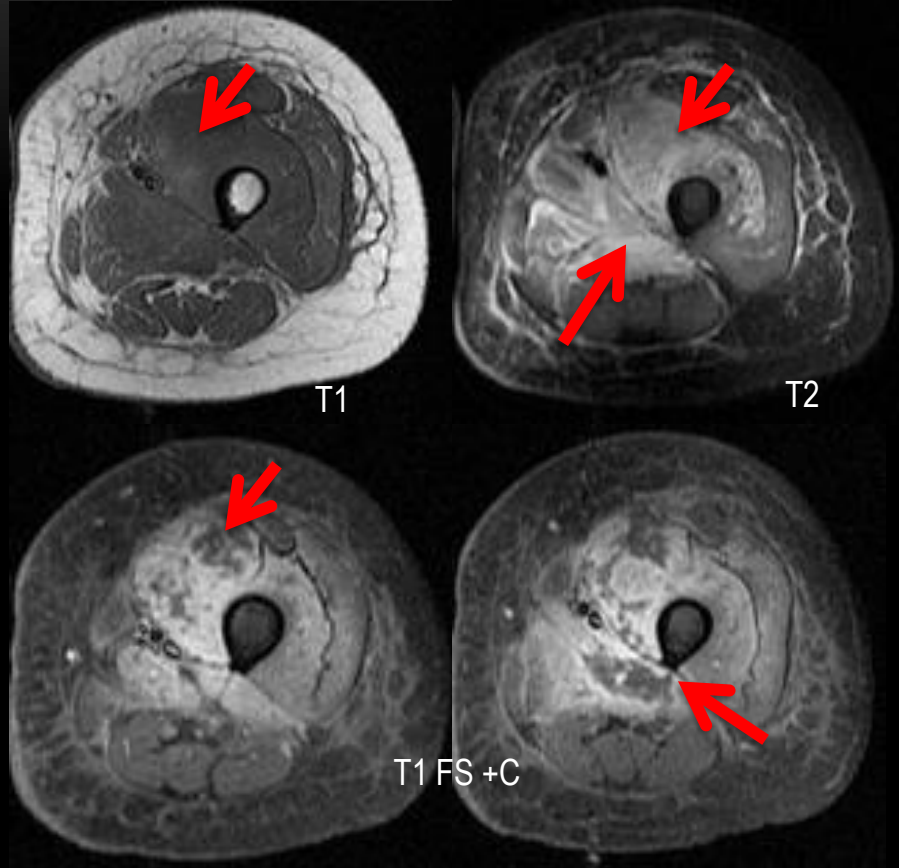
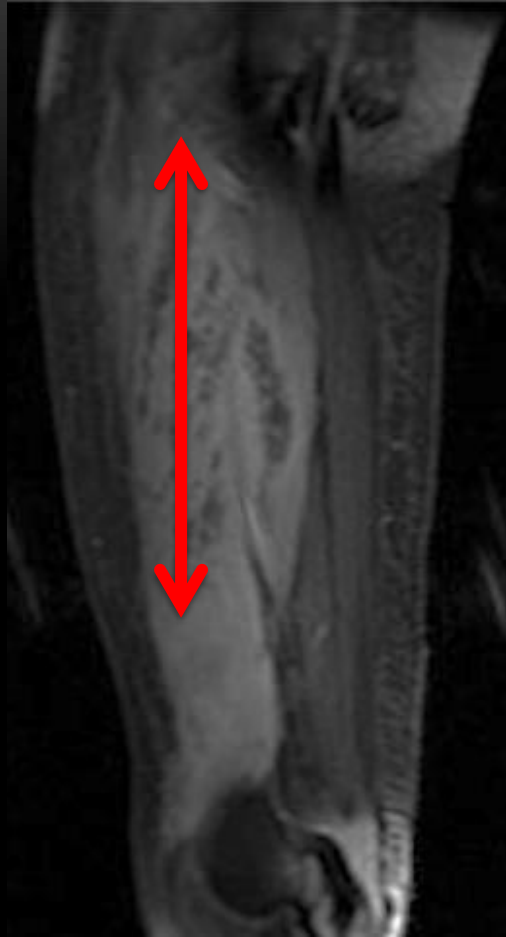

# Pyomyositis

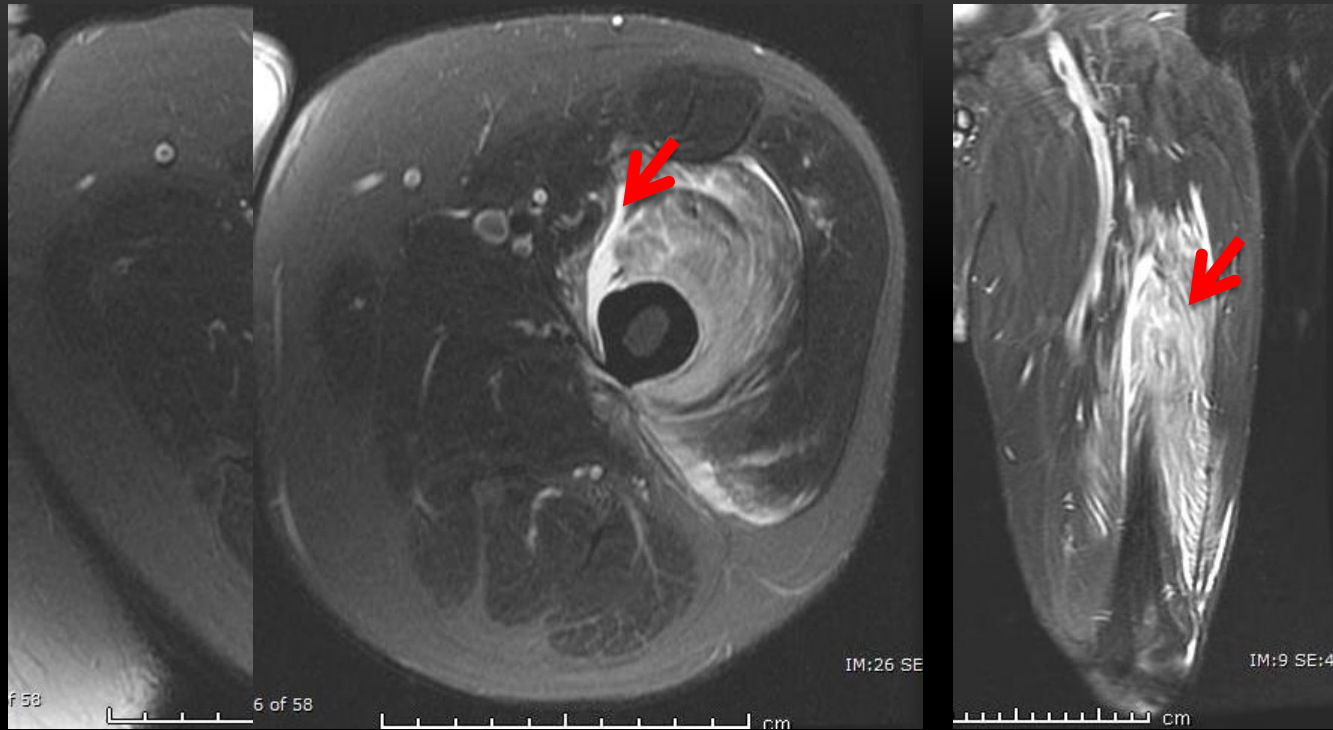


*67 yr old male*

# Pyomyositis



***29 yr old female Post MVC trauma !***

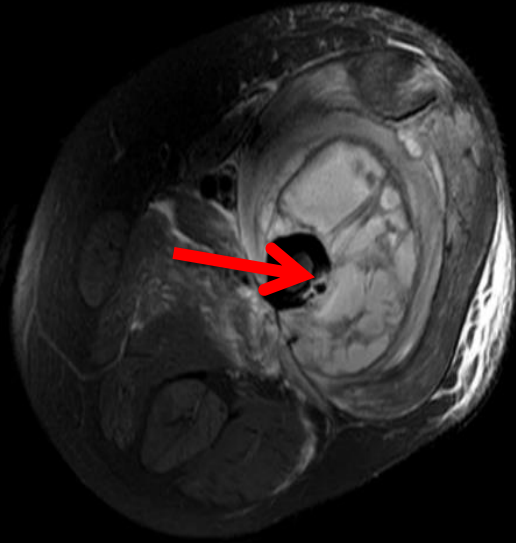
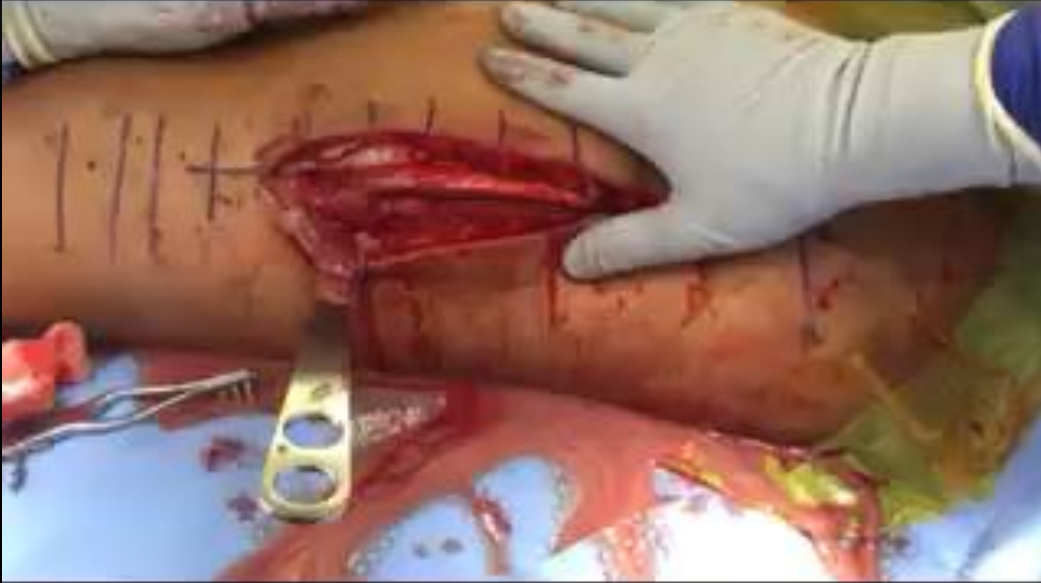

***34 yr old male Post diving injury!***



Caution gross images!

3 weeks later !



**PYOMYOSITIS +  
OSTEOMYELITIS**

***34 yr old male Post diving injury!***

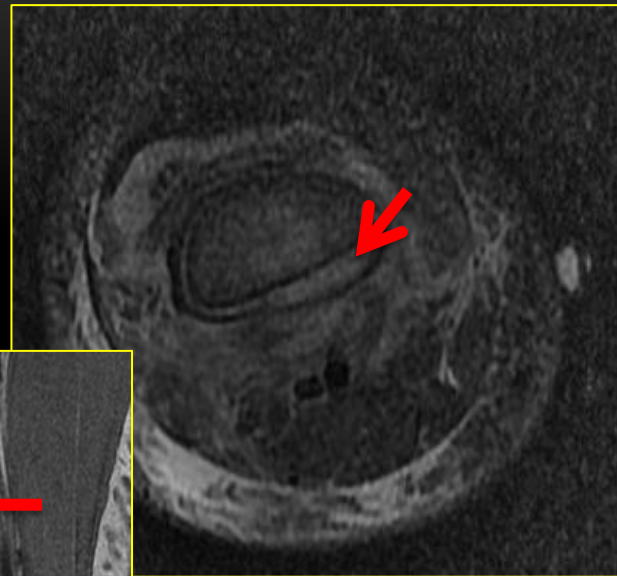
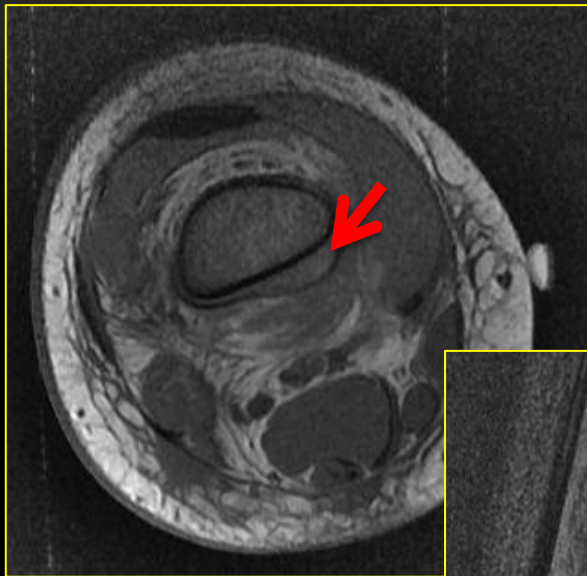
# What the clinicians what to know?

- Pyomyositis
    - Extent
    - Area of myonecrosis
    - Osteomyelitis if any
    - Neurovascular, other soft tissue involvement
-

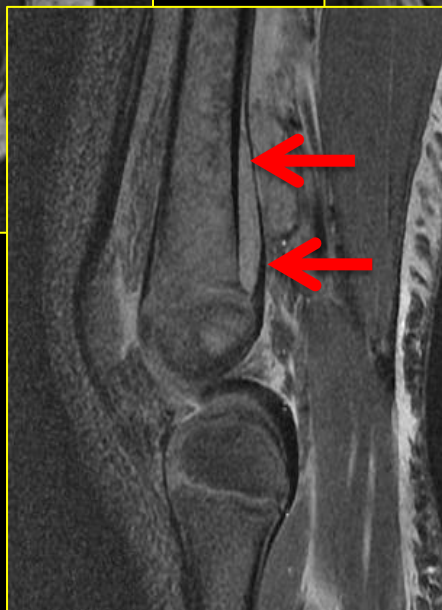Going a bit deeper!



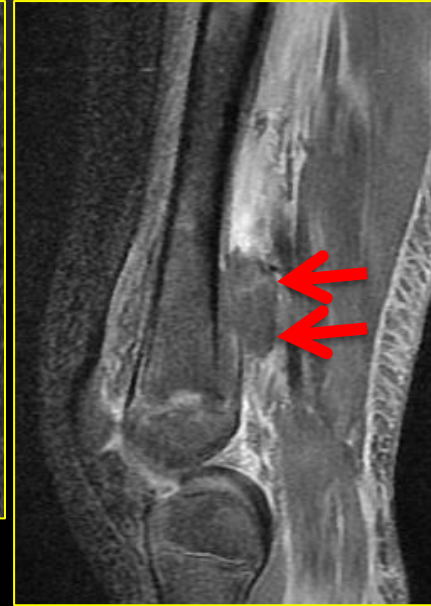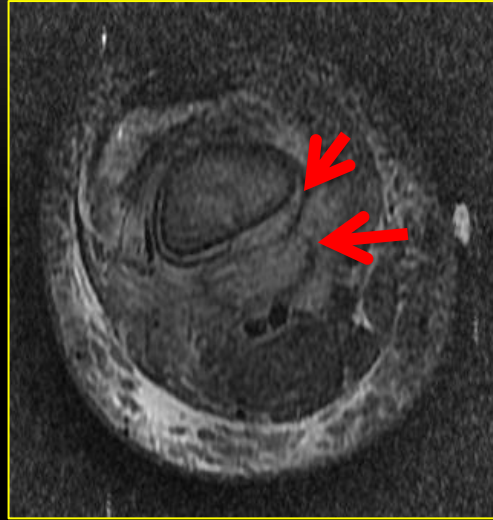
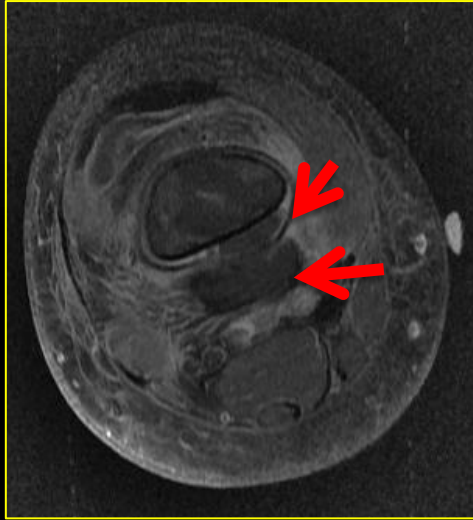
# Sub-periosteal abscess



*6 yr old*



# Sub-periosteal abscess – rupture!



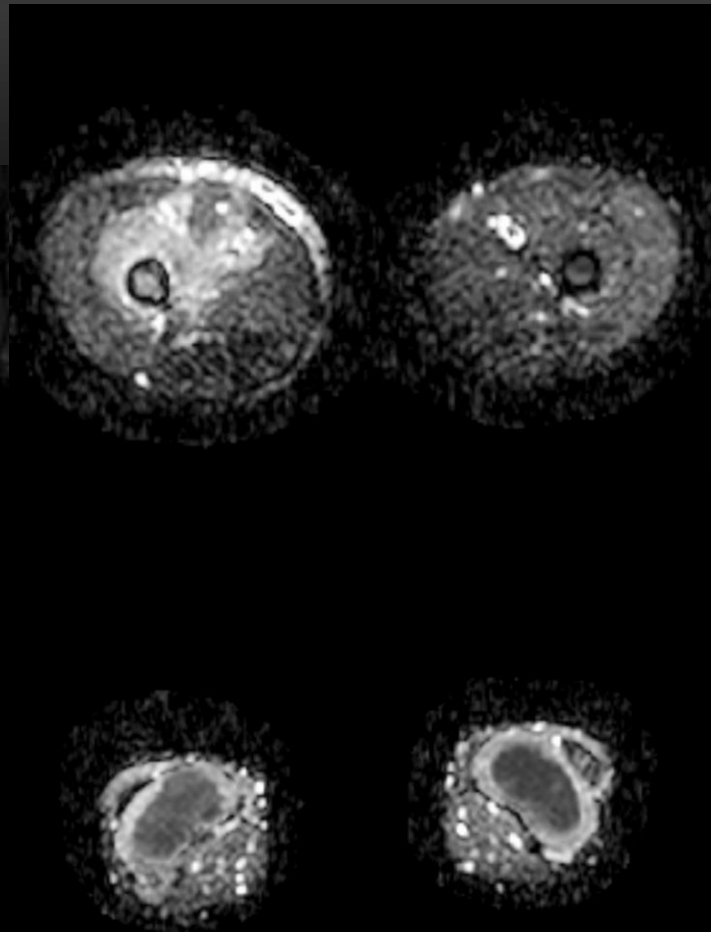
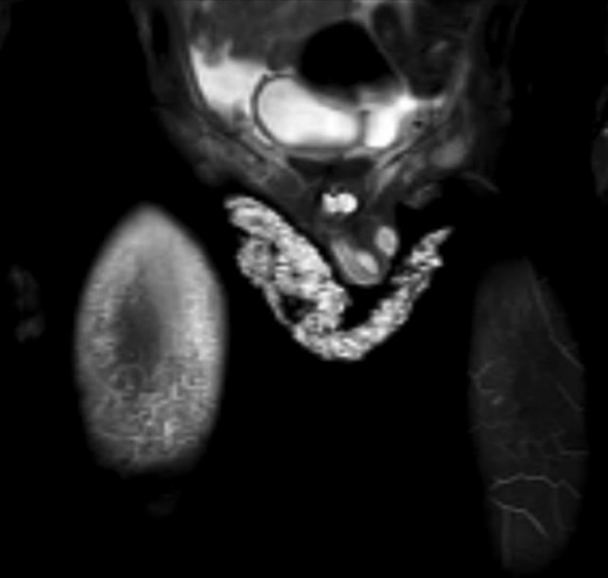
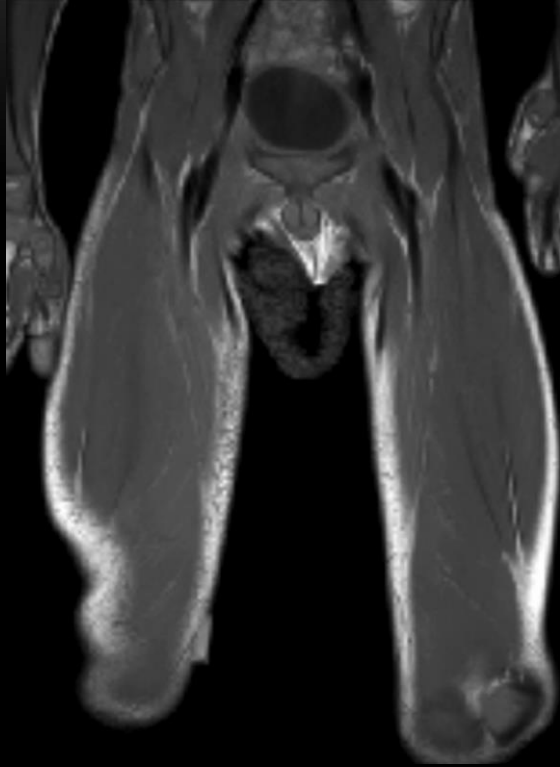
**3 days later**

Clinical  
relevance

- Confined to periosteum or rupture ?
- If rupture – extent into soft tissue?
- Associated osteomyelitis?



# Abscess.... Osteomyelitis

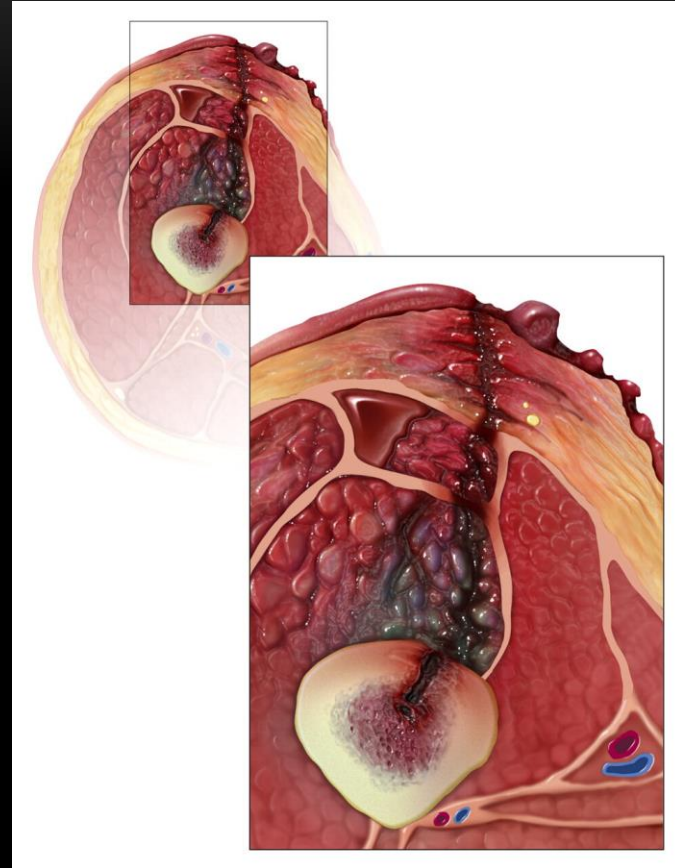

On to the bone!



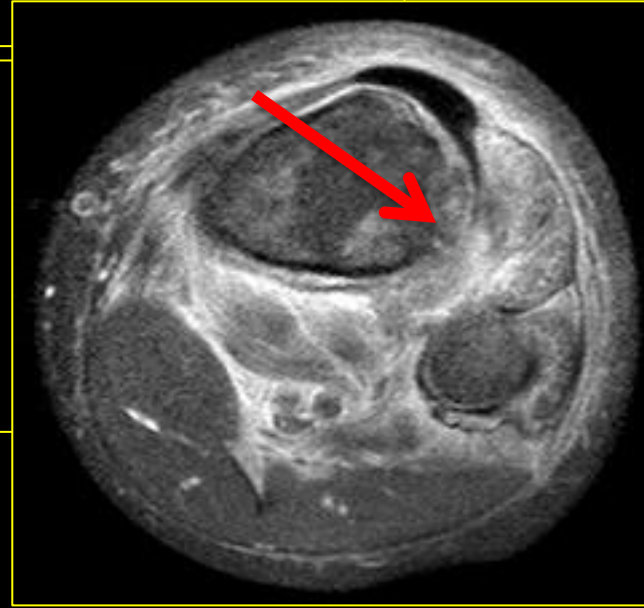
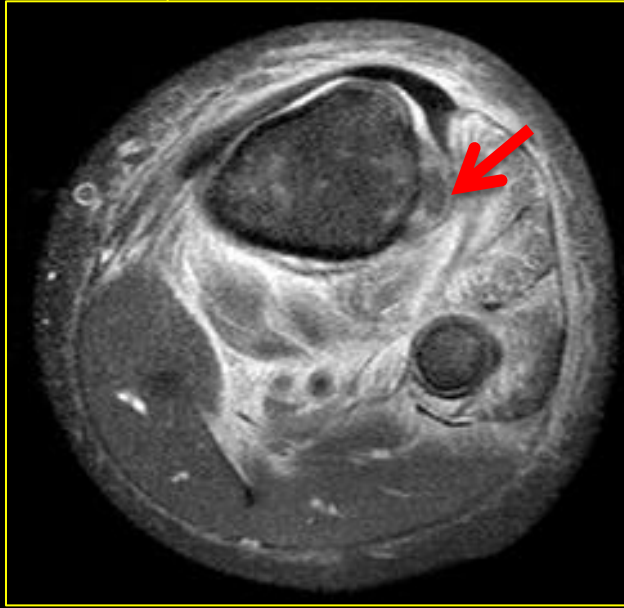
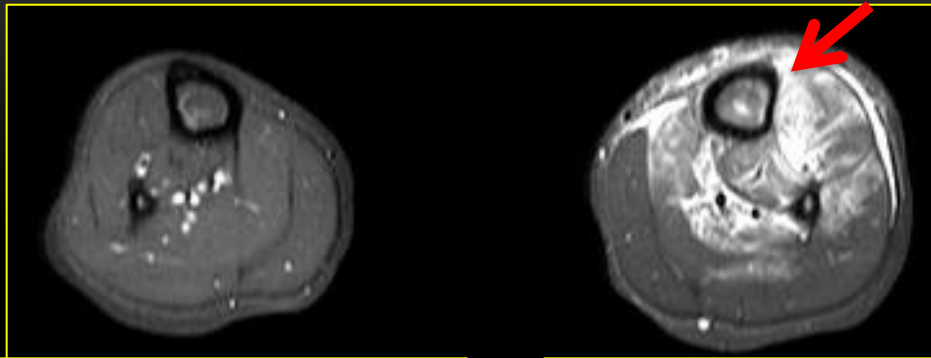
# Osteomyelitis - general

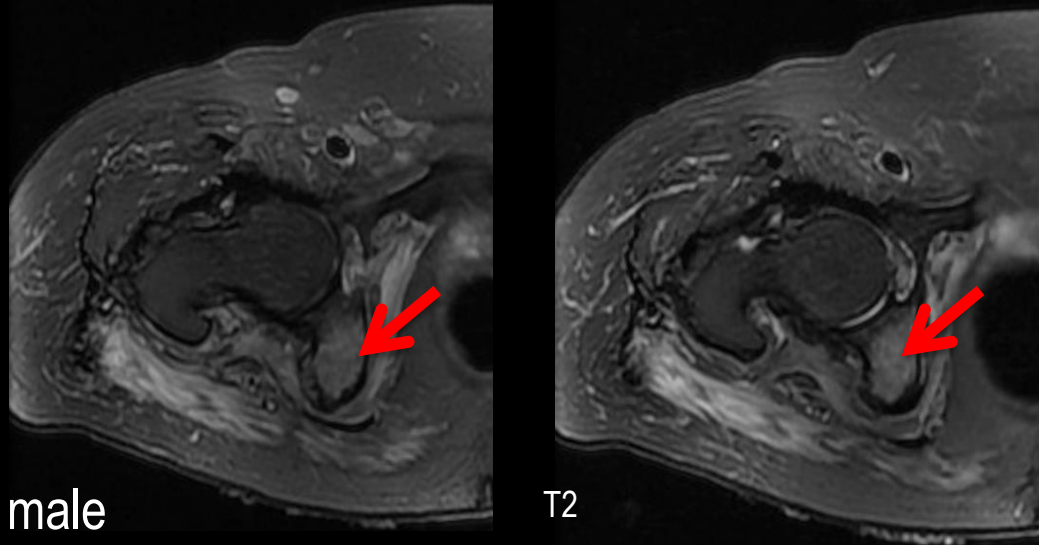
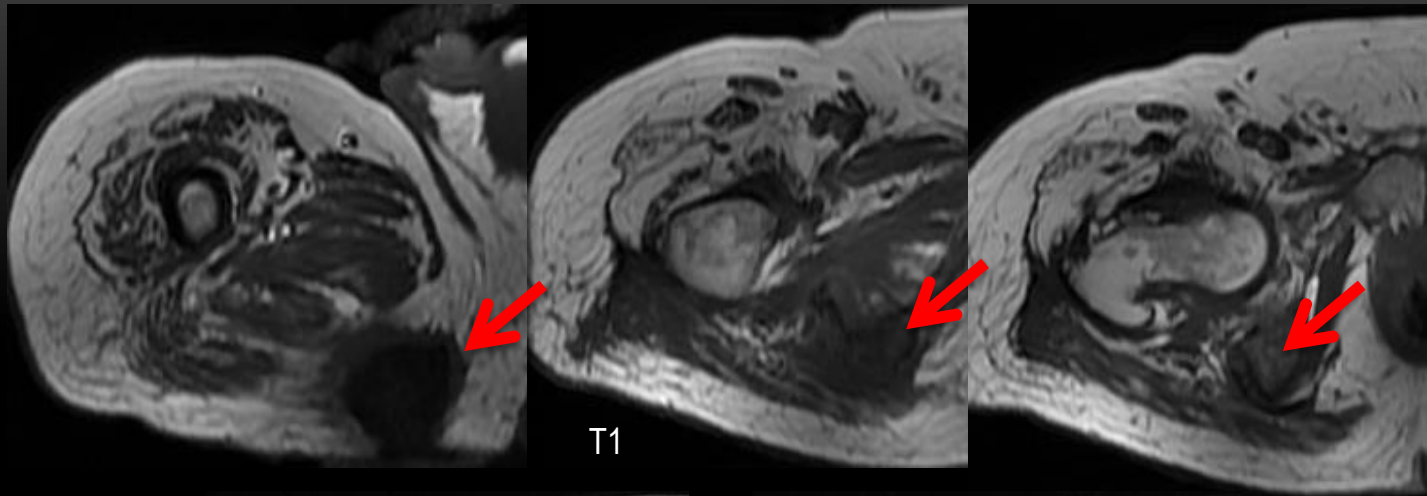
- Hematogenous spread – follows vascularity (children)
- Staph aureus
- Klebsiella, pseudomonas – IV drug abusers
- **skin ulceration** → direct seeding
- Diaphysis – also direct seeding



# Osteomyelitis

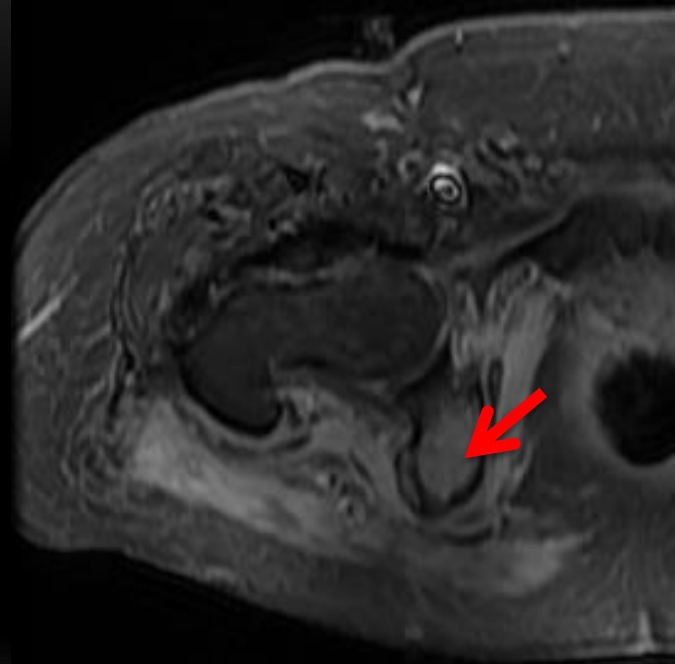
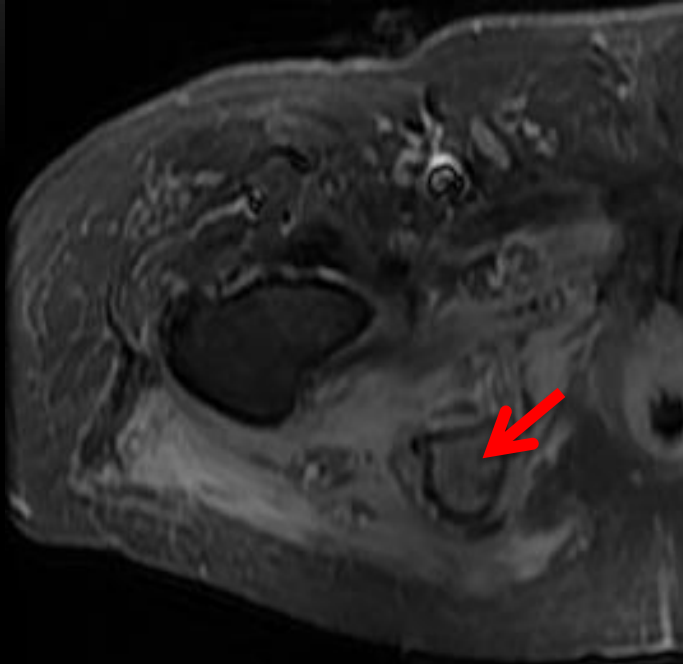
8yr old male





T1 is key  
Hypo intensity  
*Extent*

73yr old male



With contrast

OSTEOMYELITIS



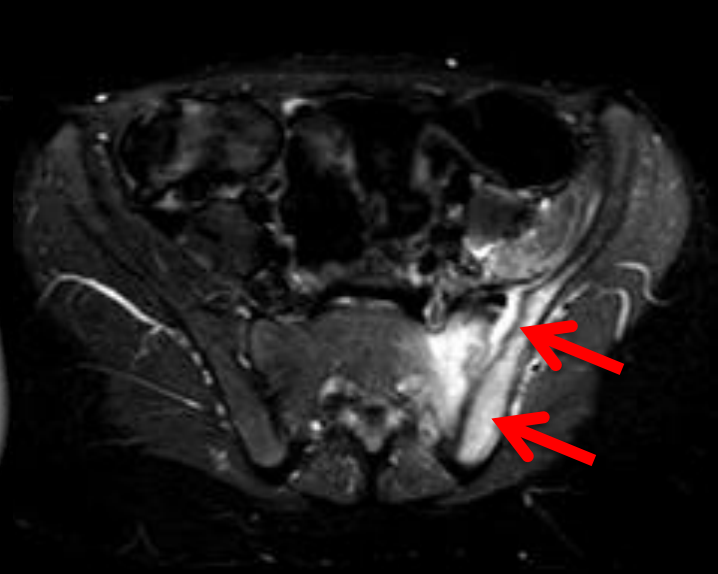
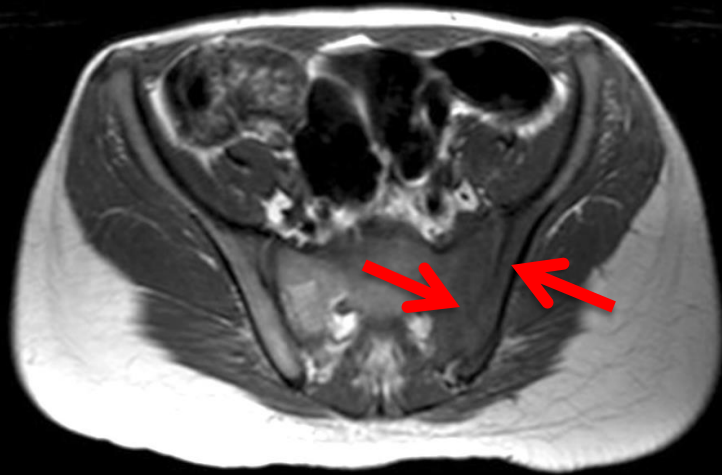# Septic arthritis

- Hematogenous spread
  - IV drug users, Immunocompromised
  - Knee , hip ( more in children)
  - Sternoclavicular joints in IV drug users
-

# Septic arthritis imaging

- T2 bright joint fluid (effusion)
  - Adjacent soft tissue and joint margin edema, synovial & peri synovial edema
  - T1 hypointense signal at articular margins and marrow hypointensity
  - Rx – urgent aspiration / arthrotomy
-

# Septic arthritis



12 yr male

# Summary

- Consider breach
    - cutaneous
    - deep fascia
    - Muscle
    - Skin ulceration in osteomyelitis
  - Extent = severity
  - A high degree of suspicion for Necrotizing Fasciitis
-



# References

- Lahham, S.; Shniter, I.; Desai, M.; Andary, R.; Saadat, S.; Fox, J.C.; Pierce, S. Point of care ultrasound in the diagnosis of necrotizing fasciitis. *Am. J. Emerg. Med.* **2022**, *51*, 397–400.
- Kwee, R.M.; Kwee, T.C. Diagnostic performance of MRI and CT in diagnosing necrotizing soft tissue infection: A systematic review. *Skelet. Radiol.* **2022**, *51*, 727–736.
- Chun, C.W.; Jung, J.-Y.; Baik, J.S.; Jee, W.-H.; Kim, S.K.; Shin, S.H. Detection of soft-tissue abscess: Comparison of diffusion-weighted imaging to contrast-enhanced MRI. *J. Magn. Reson. Imaging* **2018**, *47*, 60–68.
- Bierry G, Huang AJ, Chang CY, Torriani M, Bredella MA. MRI findings of treated bacterial septic arthritis. *Skeletal Radiol* 2012 Dec;41(12):1509-1516.
- Edlich RF, Cross CL, Dahlstrom JJ, Long WB,3rd. Modern concepts of the diagnosis and treatment of necrotizing fasciitis. *J Emerg Med* 2010 Aug;39(2):261-265.
- Garcia-Casares E, Mateo Soria L, Garcia-Melchor E, Riera Alonso E, Olive Marques A, Holgado Perez S, et al. Necrotizing fasciitis and myositis caused by streptococcal flesh-eating bacteria. *J Clin Rheumatol* 2010 Dec;16(8):382-384.
- Guillerman RP. Osteomyelitis and beyond. *Pediatr Radiol* 2013 Mar;43 Suppl 1:S193-203.
- Kim KT, Kim YJ, Won Lee J, Kim YJ, Park SW, Lim MK, et al. Can necrotizing infectious fasciitis be differentiated from nonnecrotizing infectious fasciitis with MR imaging? *Radiology* 2011 Jun;259(3):816-824.
- Maj L, Gombar Y,3rd, Morrison WB. MR imaging of hip infection and inflammation. *Magn Reson Imaging Clin N Am* 2013 Feb;21(1):127-139.
- Metwalli ZA, Kan JH, Munjal KA, Orth RC, Zhang W, Guillerman RP. MRI of suspected lower extremity musculoskeletal infection in the pediatric patient: how useful is bilateral imaging? *AJR Am J Roentgenol* 2013 Aug;201(2):427-432.
- Soldatos T, Durand DJ, Subhawong TK, Carrino JA, Chhabra A. Magnetic resonance imaging of musculoskeletal infections: systematic diagnostic assessment and key points. *Acad Radiol* 2012 Nov;19(11):1434-1443.



Thank you for your attention!

Nicks Kumaravel MD

@MKMSKER



McGovern  
Medical School

MEMORIAL  
HERMANN