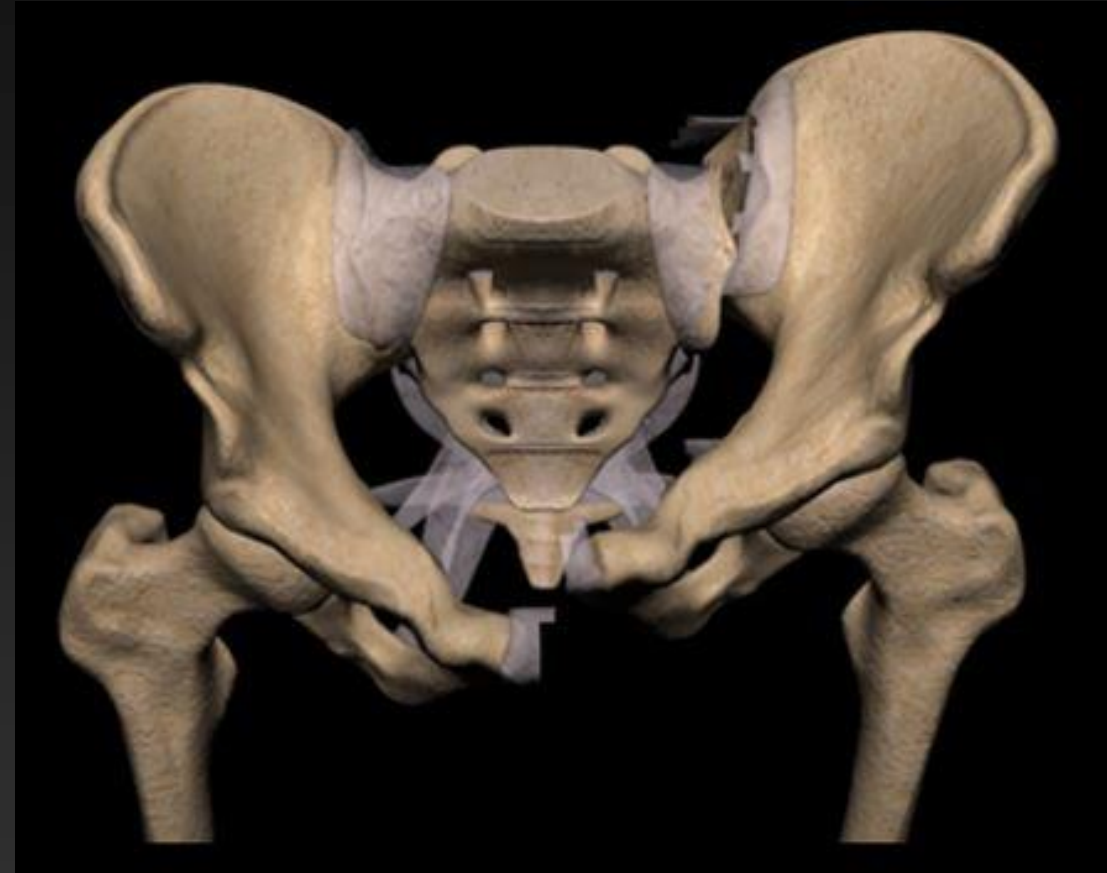


PELVIC TRAUMA



Bharti Khurana, MD, MBA, FACR, FASER
National Academy of Medicine Scholar in Diagnostic Excellence
Founder and Director, Trauma Imaging Research and Innovation Center
Department of Radiology and Medicine
Brigham and Women's Hospital
Associate Professor, Harvard Medical School

<https://bhartikhurana.bwh.harvard.edu/>

bkhurana@bwh.harvard.edu

@KhuranaBharti



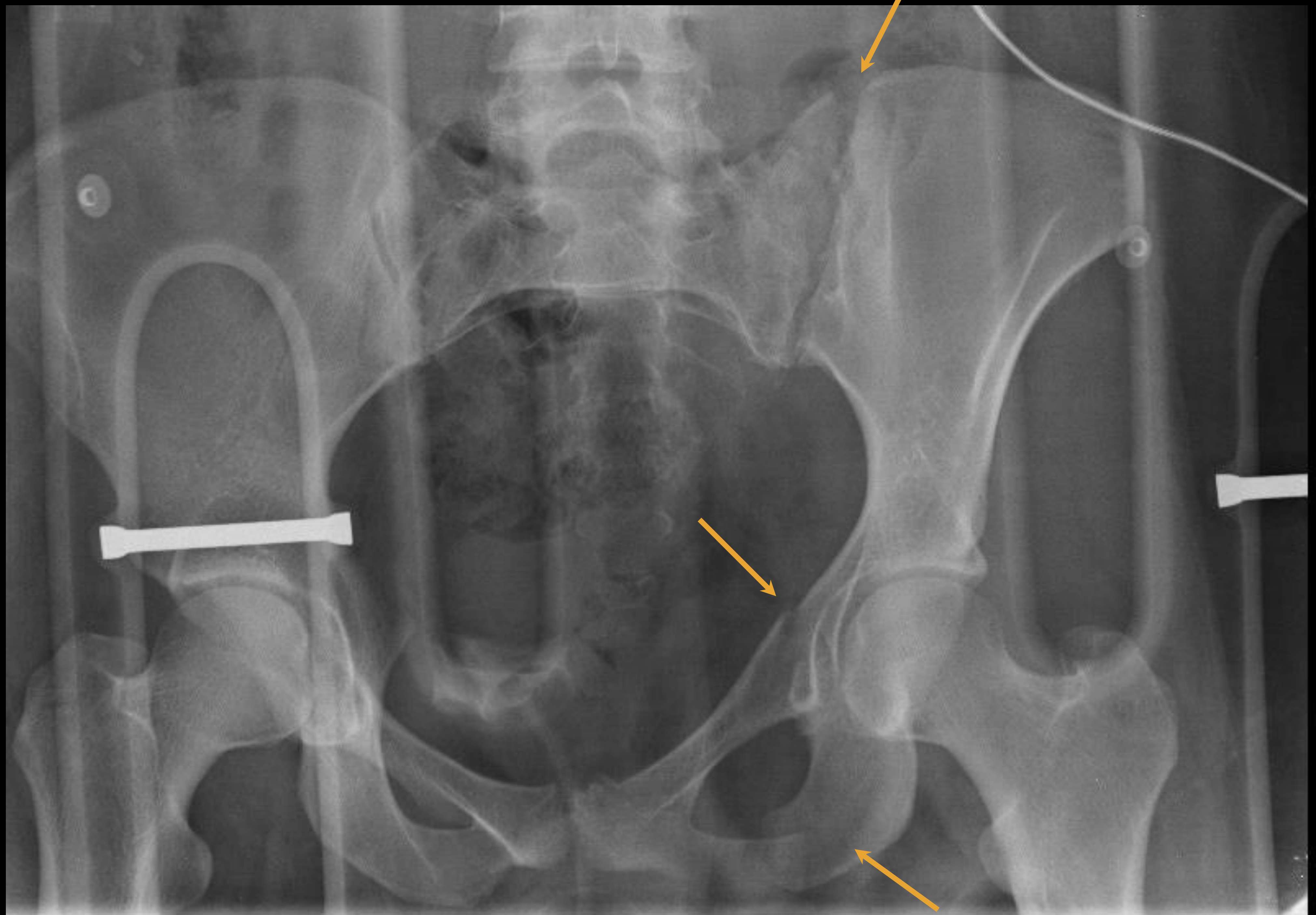
Financial Disclosures

Wolters Kluwer: *UpToDate* Emergency Radiology Section
Editor Royalties

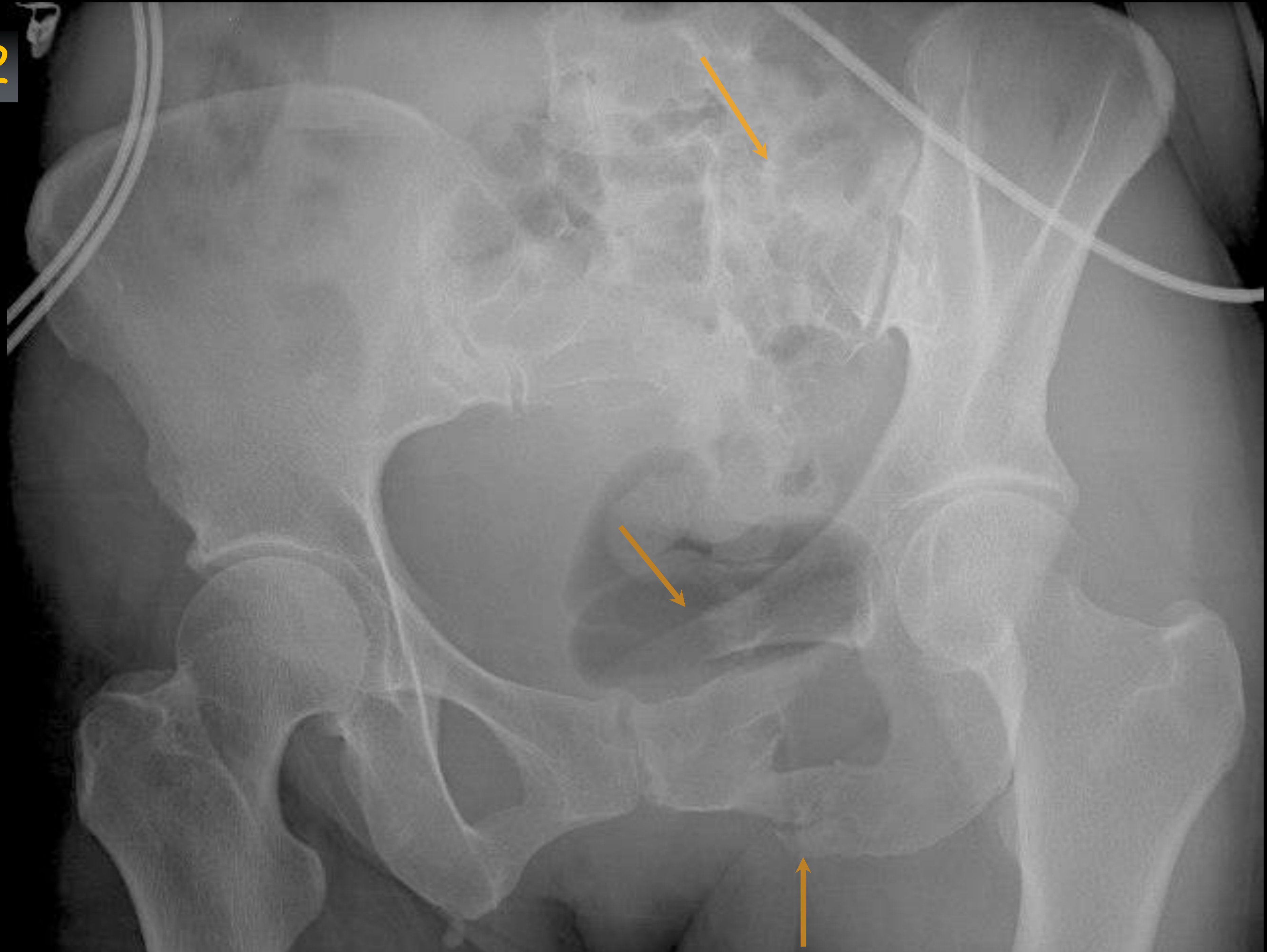
Cambridge University Press: COFFEE Editor Royalties

GE Healthcare Research Consultant

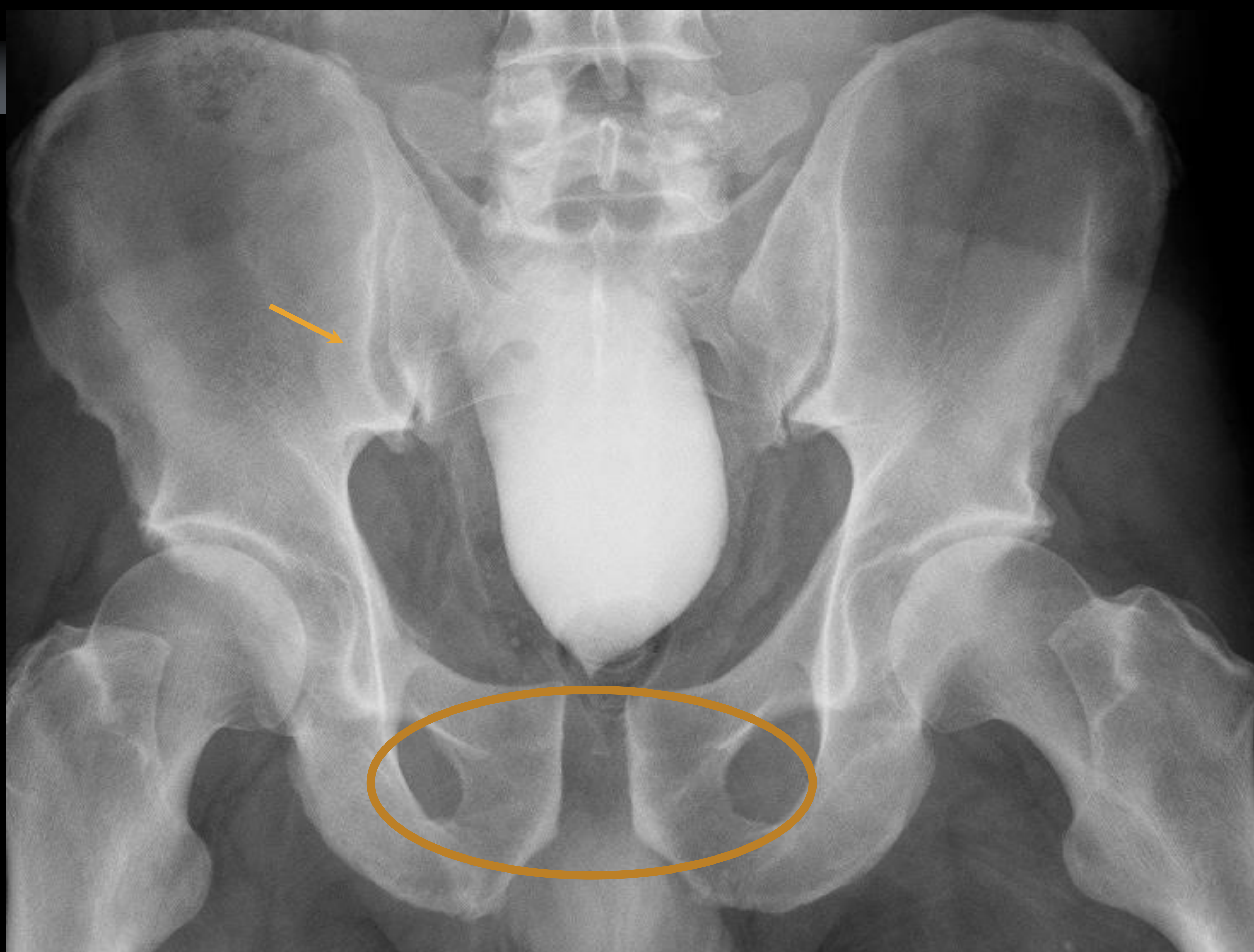
CASE 1



CASE 2



CASE 3



Pelvic Ring Fractures

- Displaced pelvic ring fractures indicate high energy trauma
- 60% MVA, 30% fall from height and 10% from crush injuries
- Increase in incidence
 - More high speed MVA
 - Increased survival rates
- Hemorrhage, urogenital and lumbosacral plexus injuries

Pelvic Stability

Ability of pelvis to withstand physiological forces without significant displacement or deformity over time

Rotational Stability

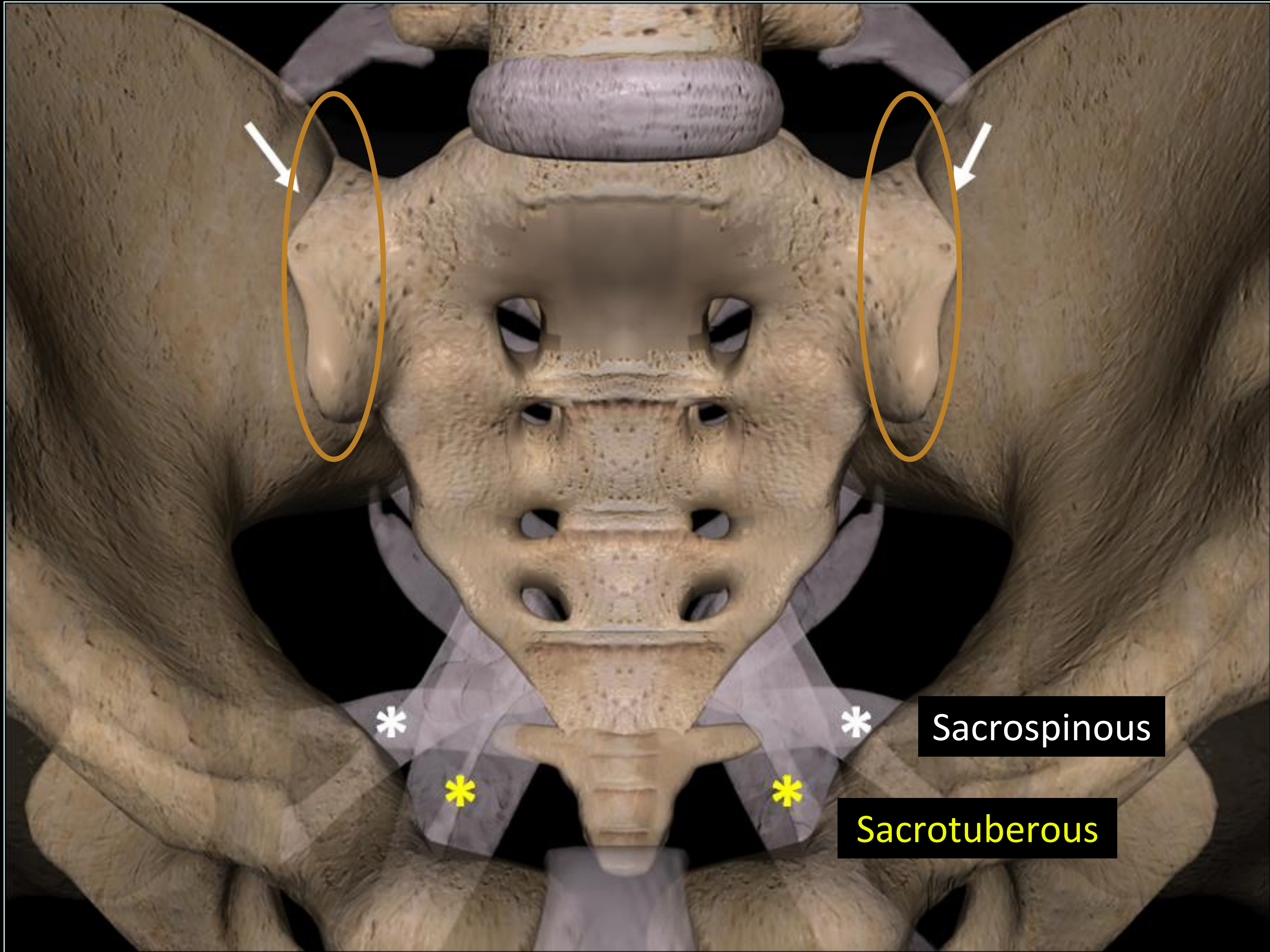
Opening and Closing of the pelvis

- Anterior SI ligament
- Sacrospinous ligament
- Posterior SI ligament

Vertical Stability

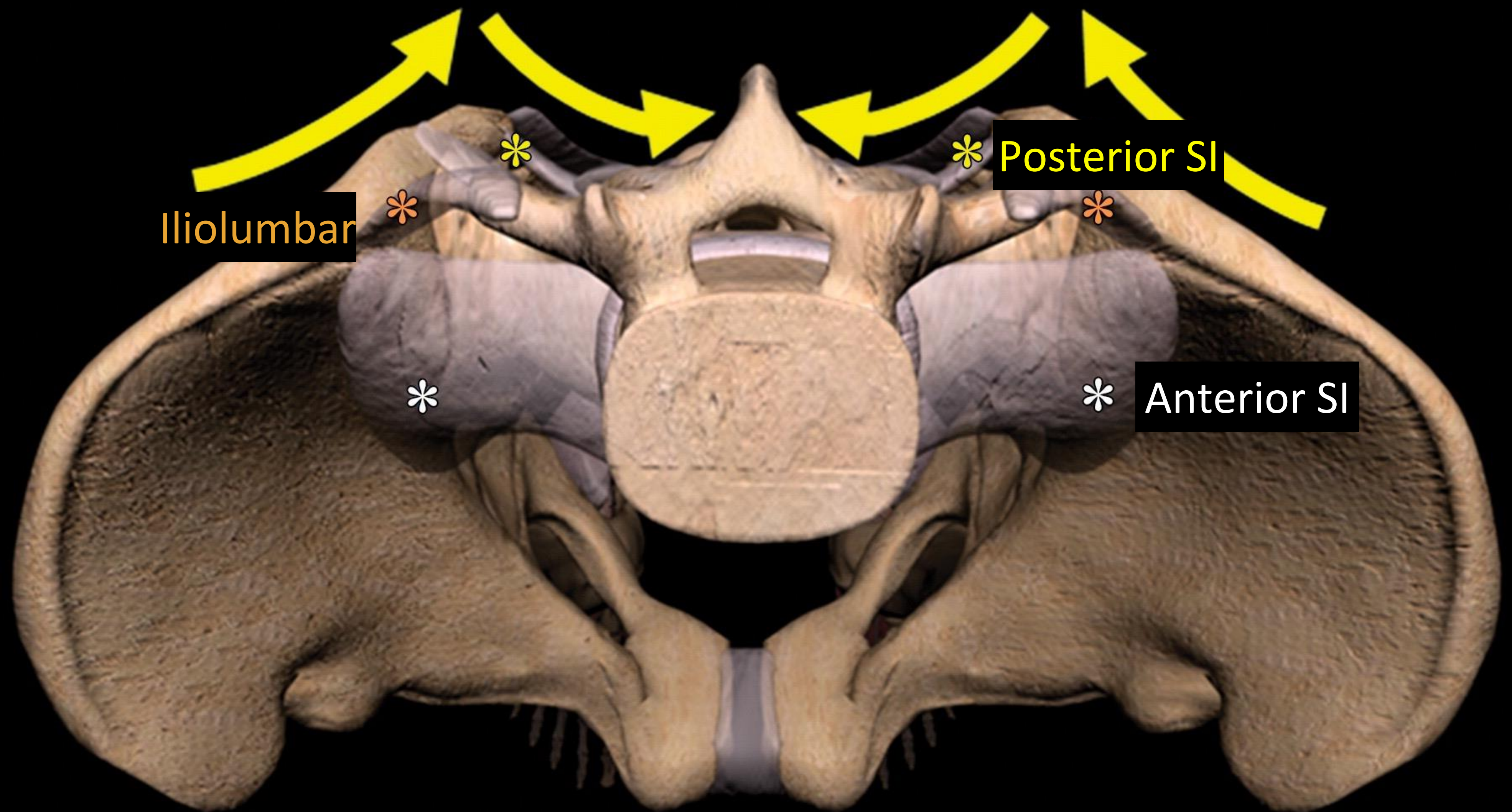

Cephalad displacement

- Posterior SI ligament



Sacrospinous

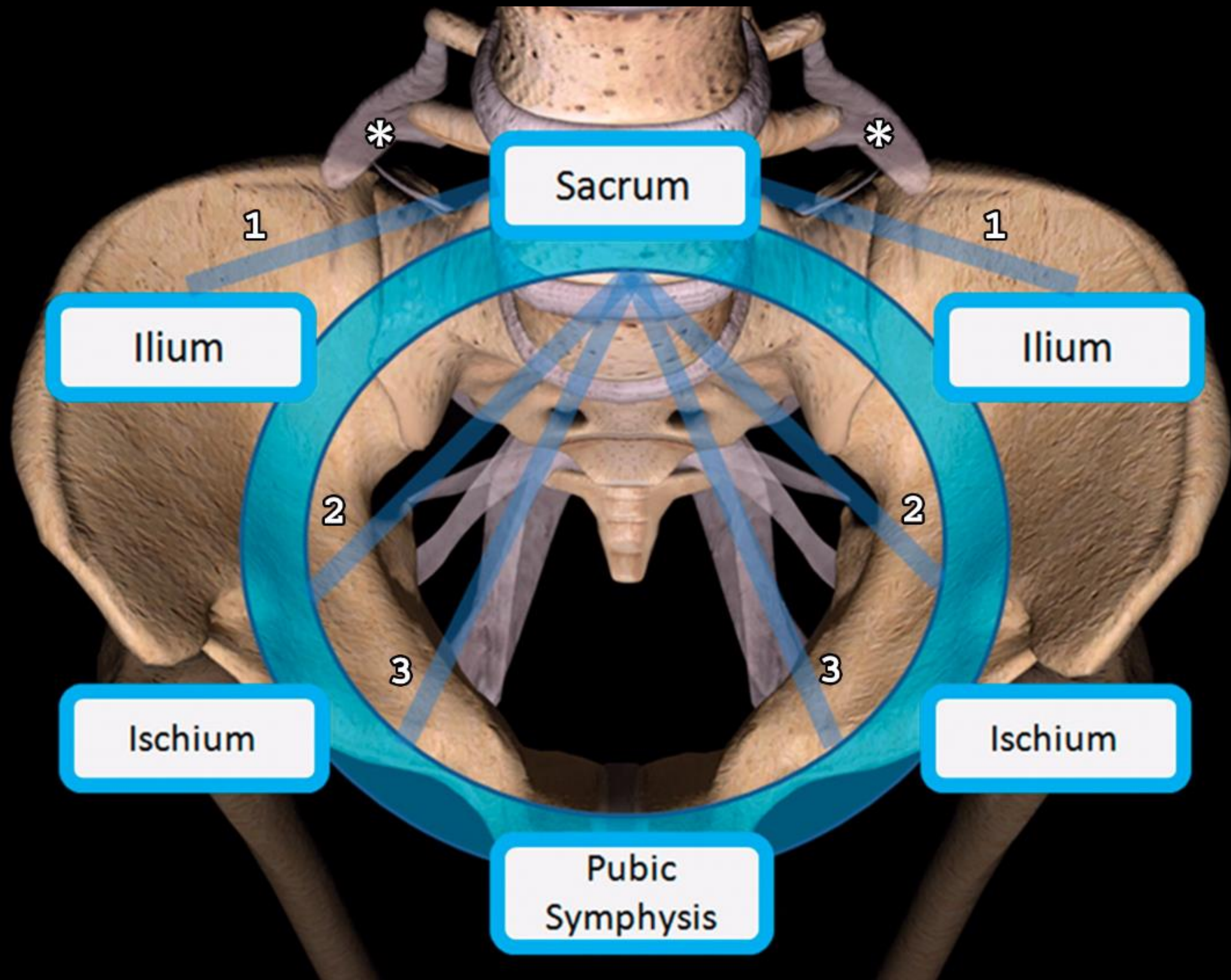
Sacrotuberous



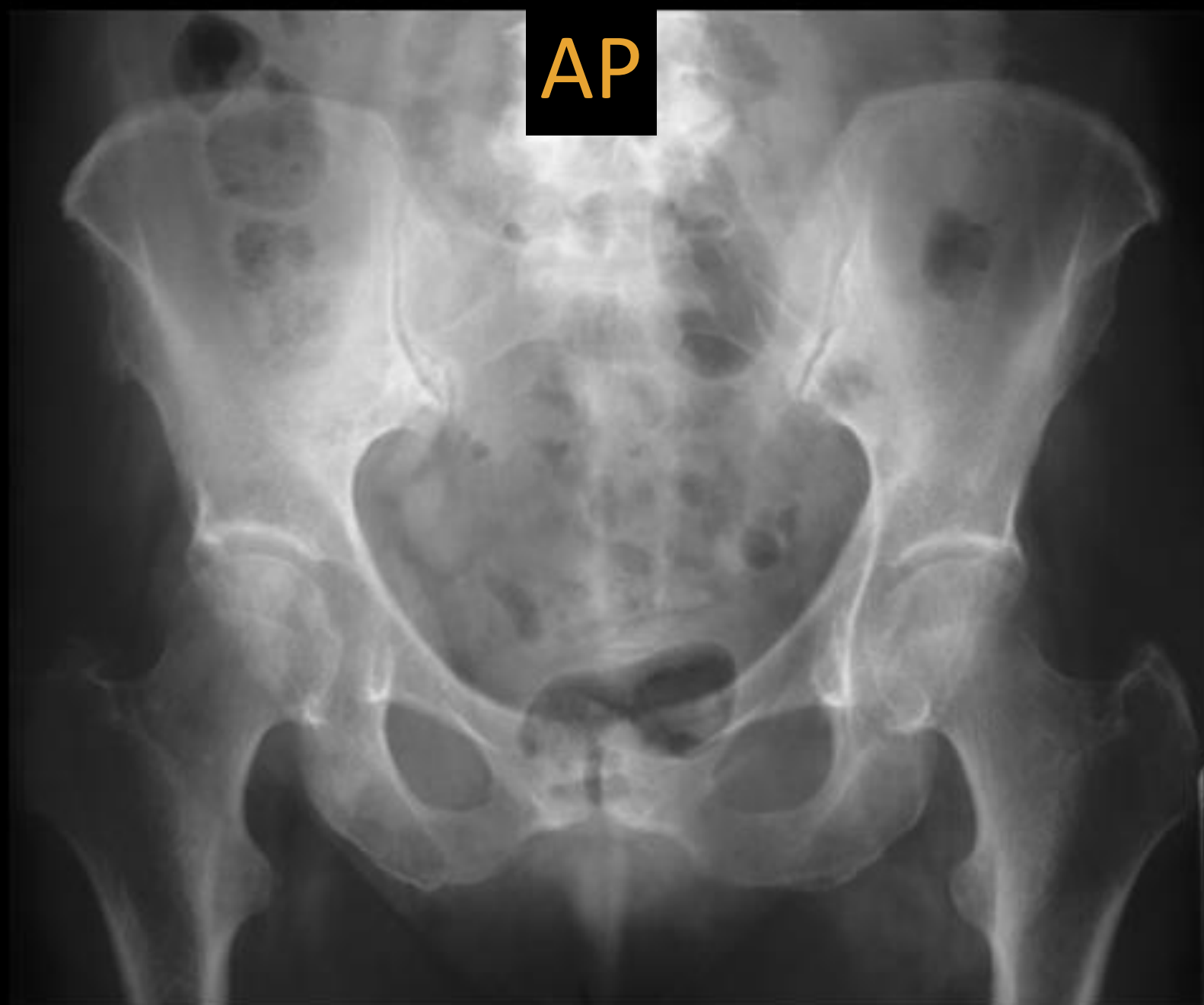
Iliolumbar

Posterior SI

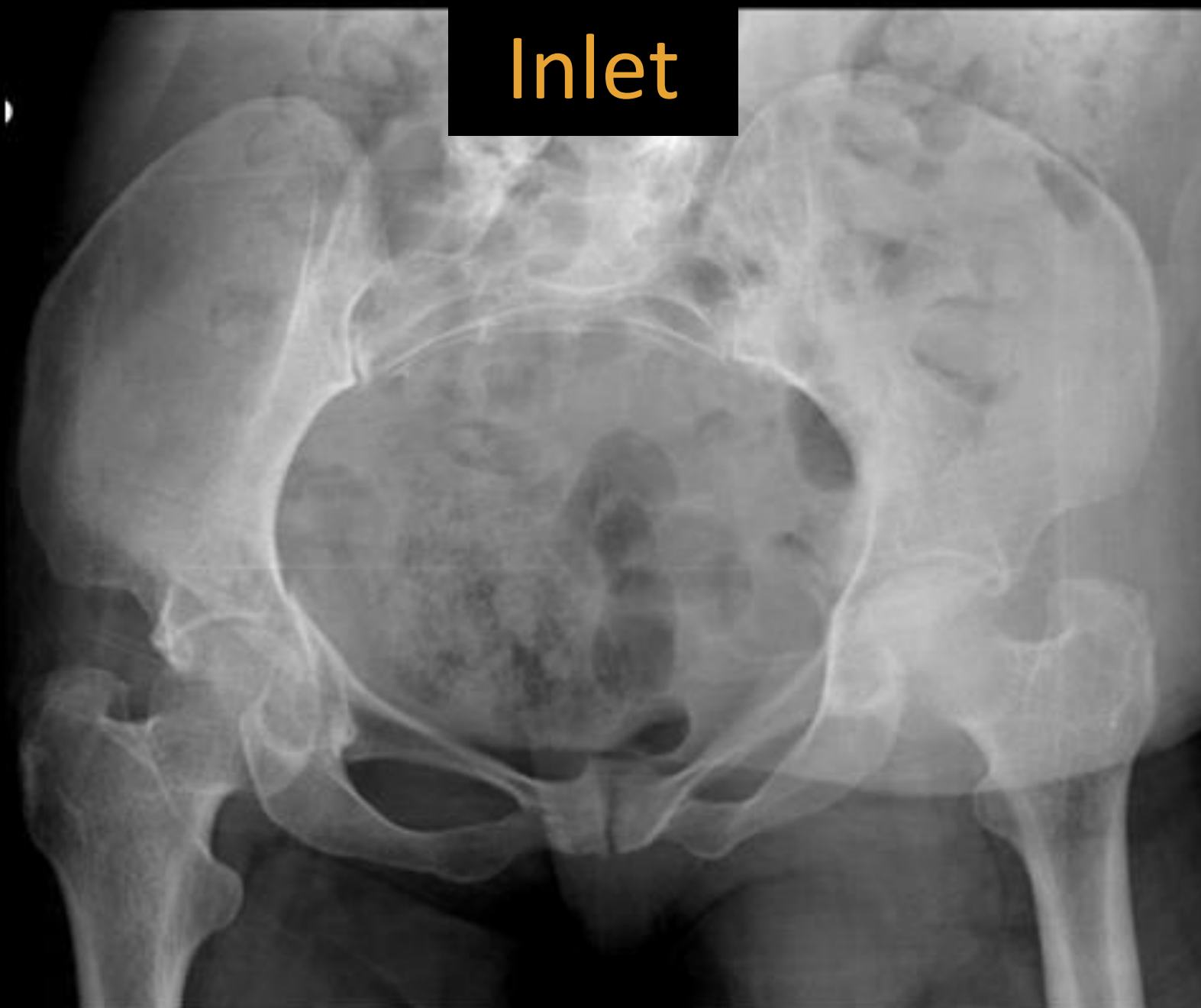
Anterior SI



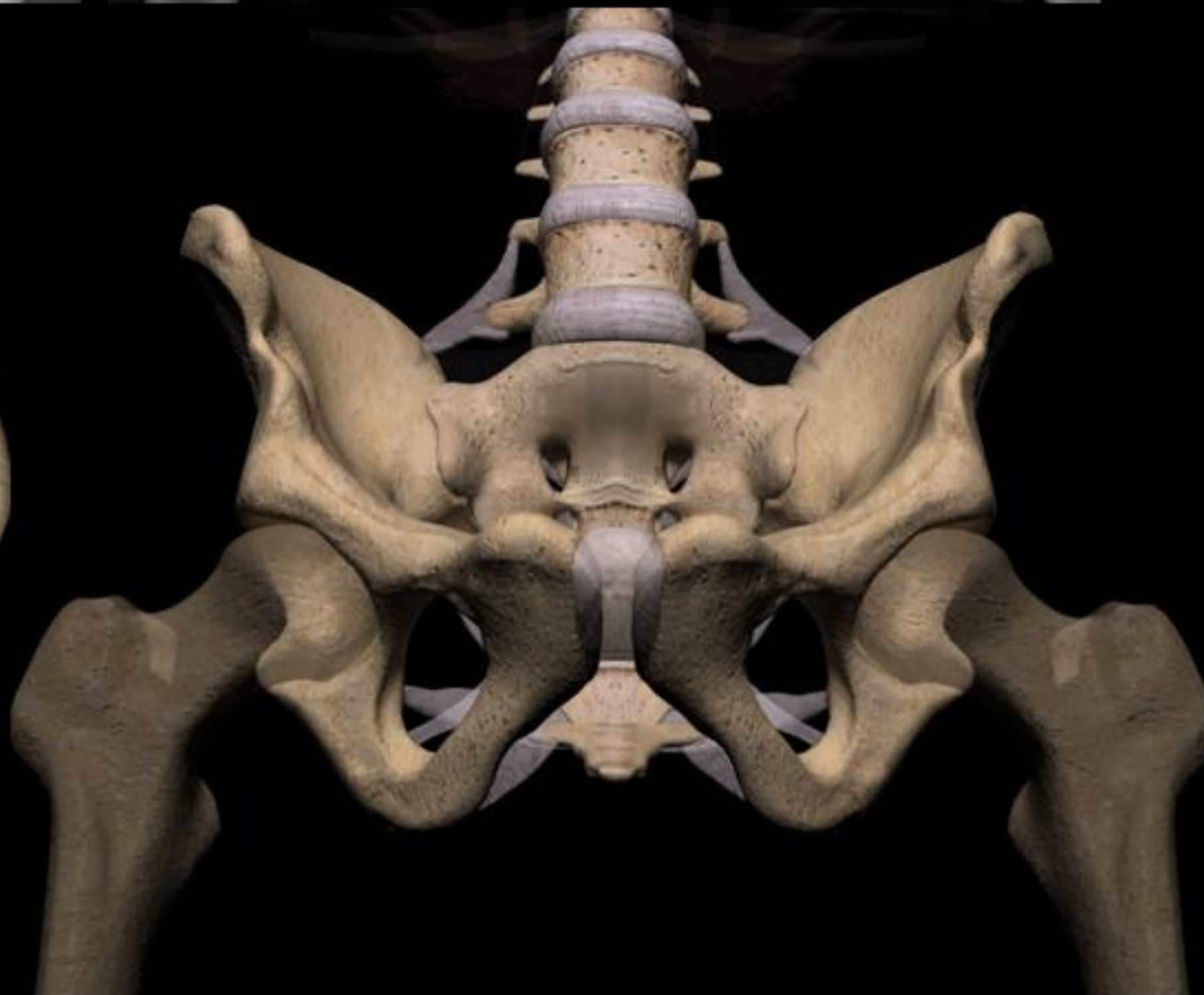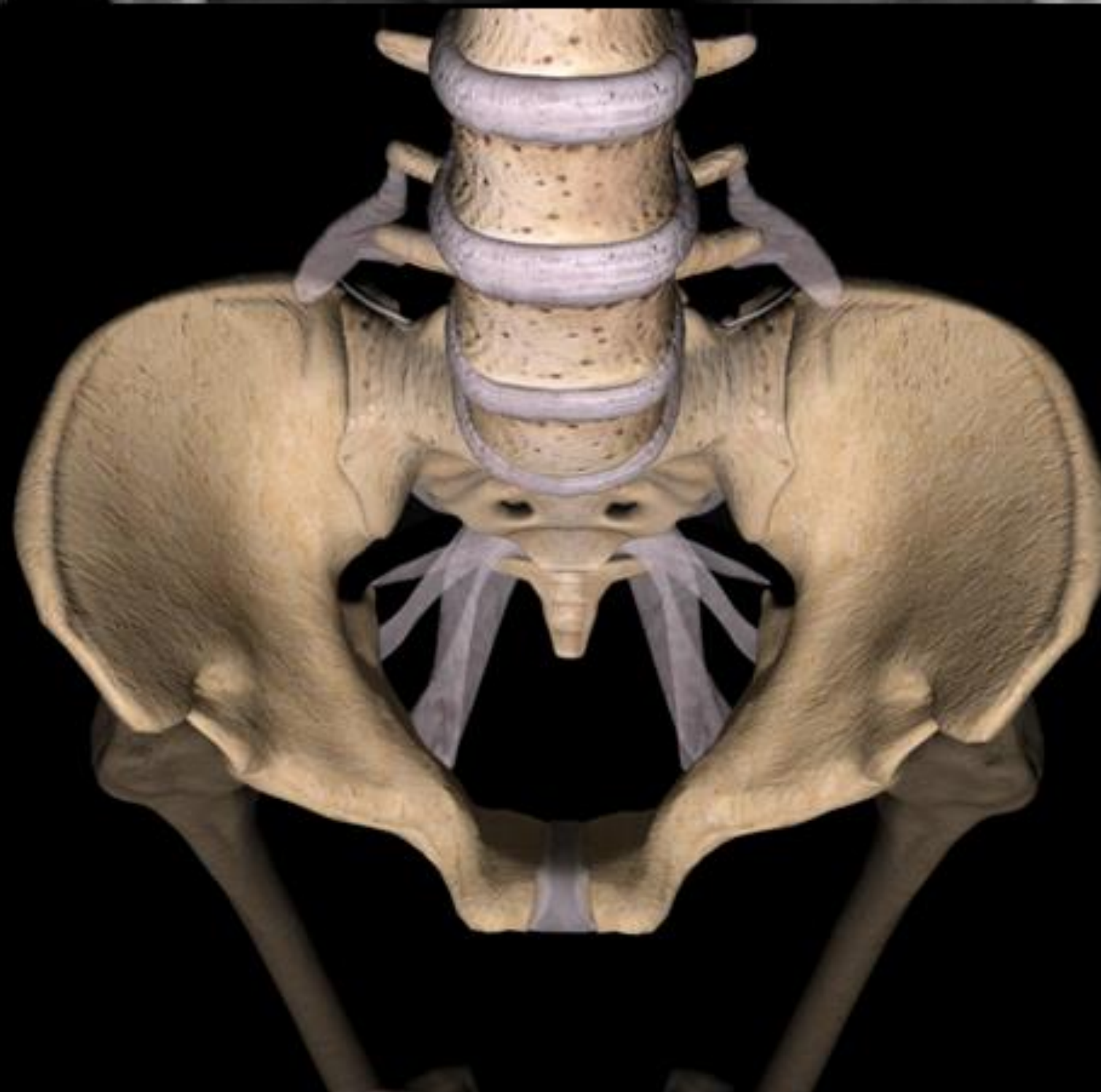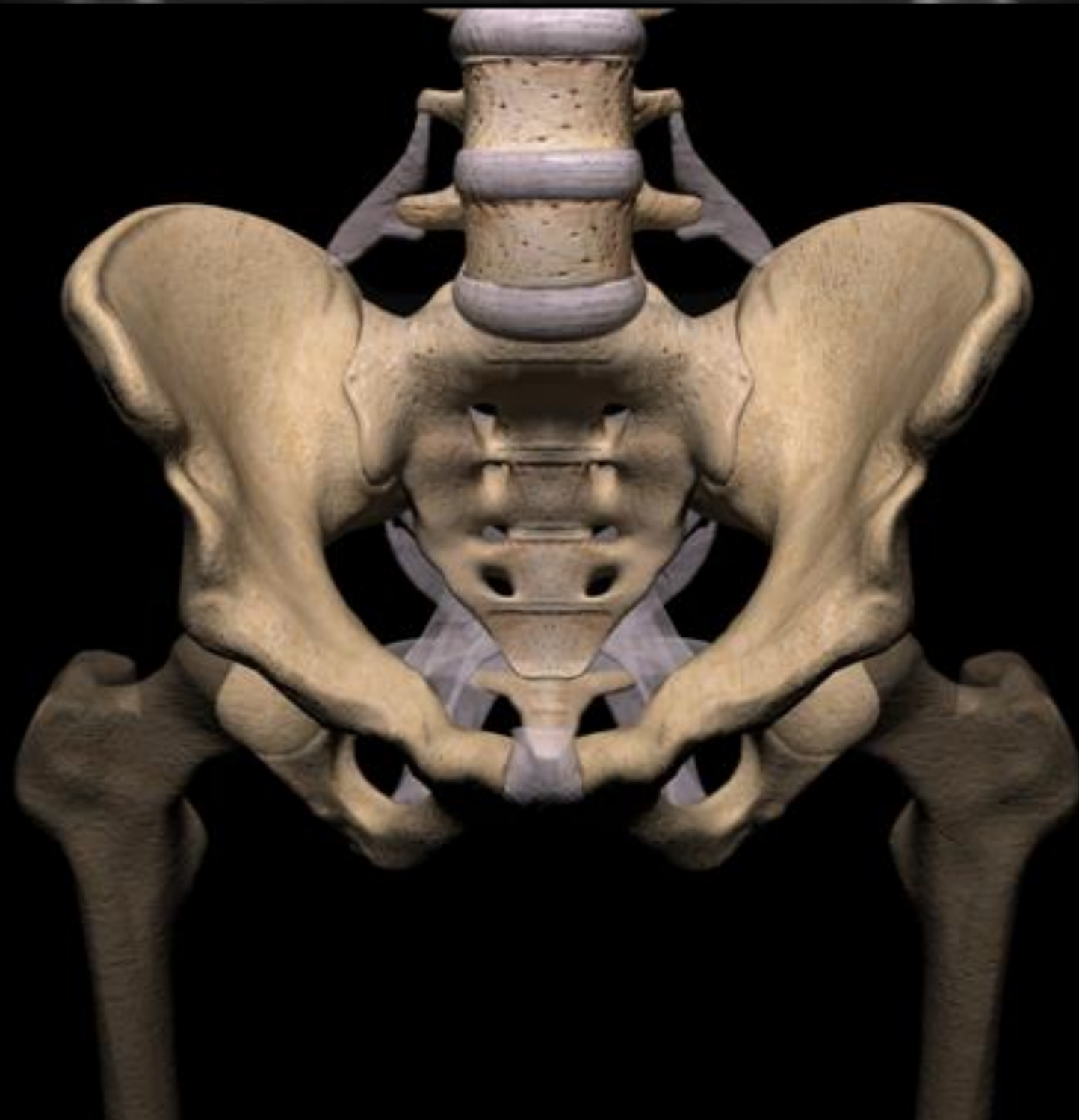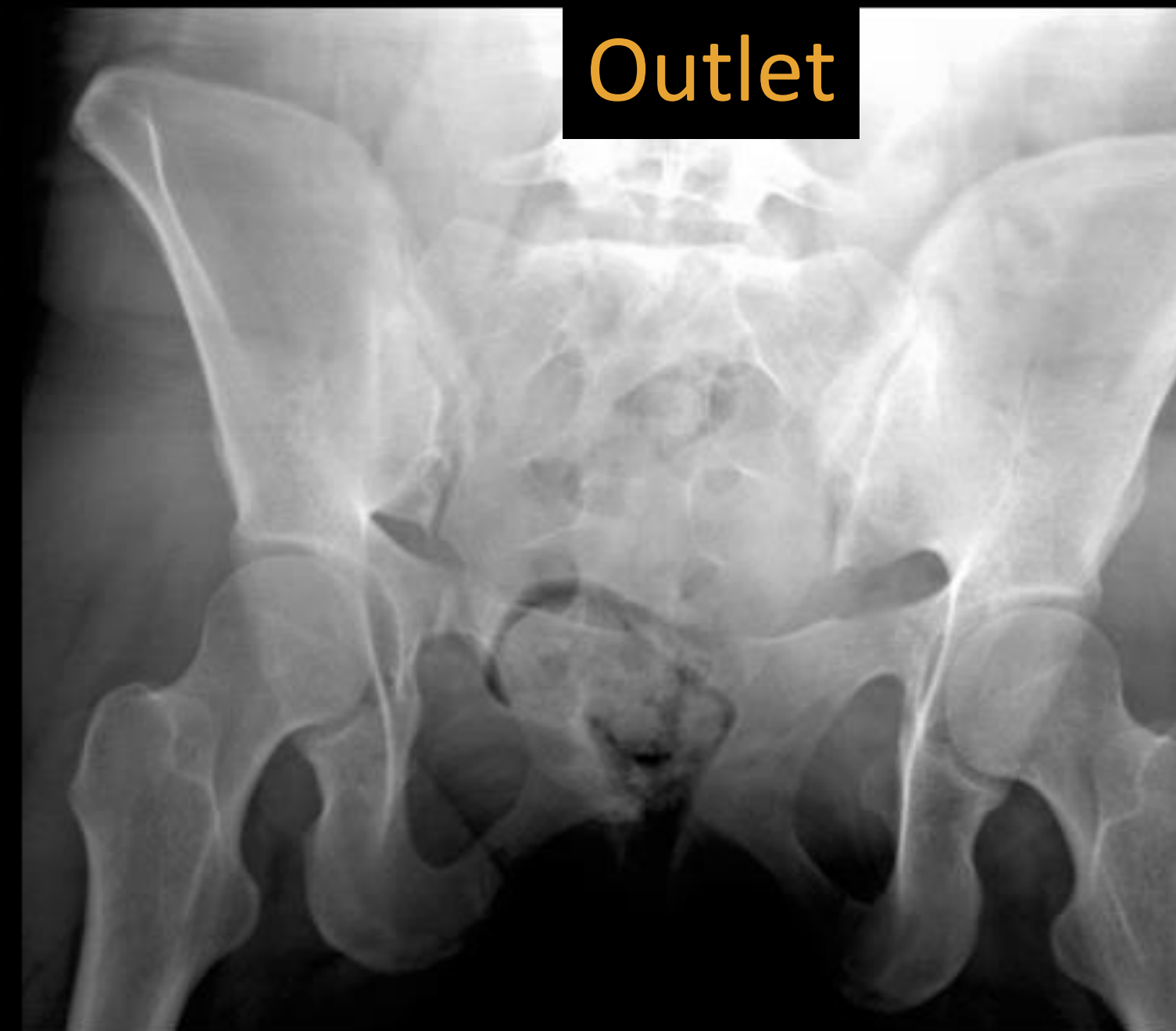
AP



Inlet

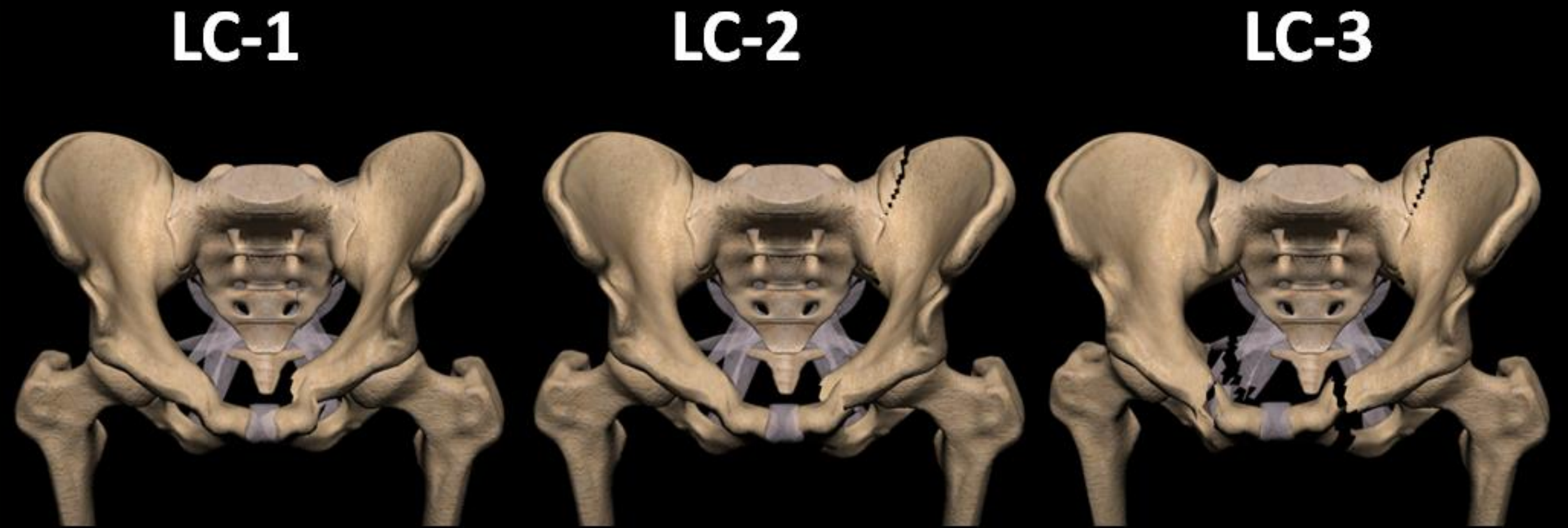

Outlet

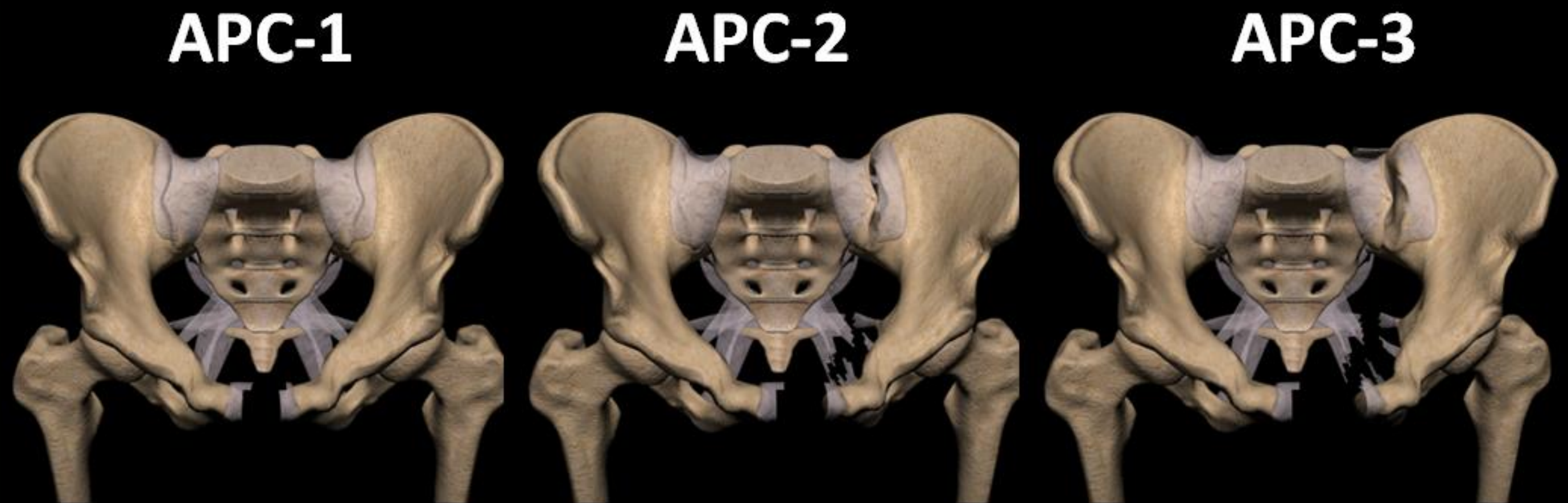

Young and Burgess system

Lateral Compression

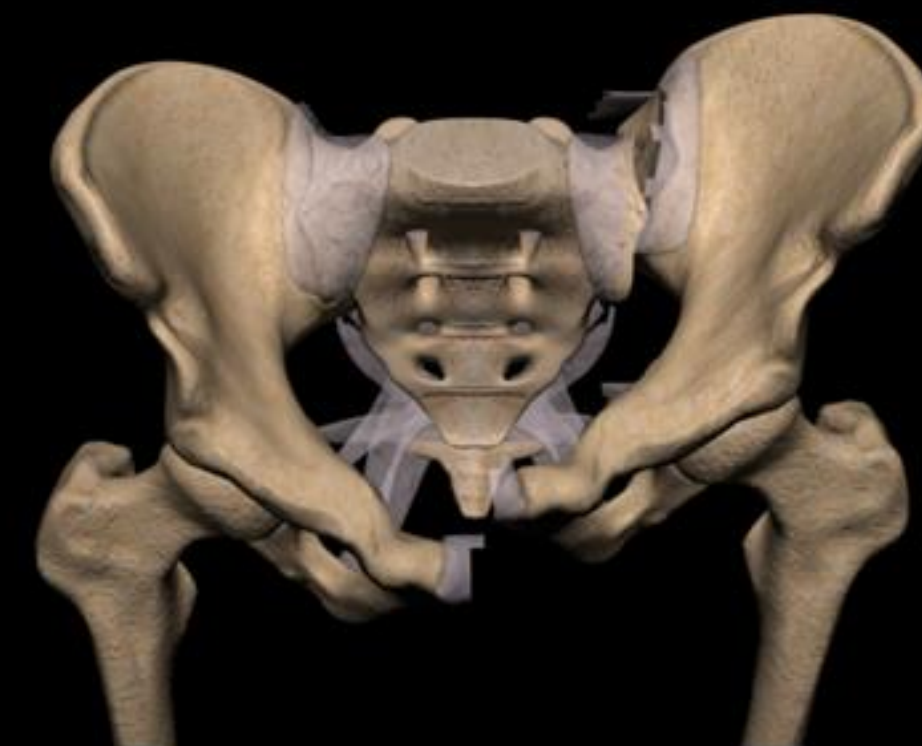

AP Compression

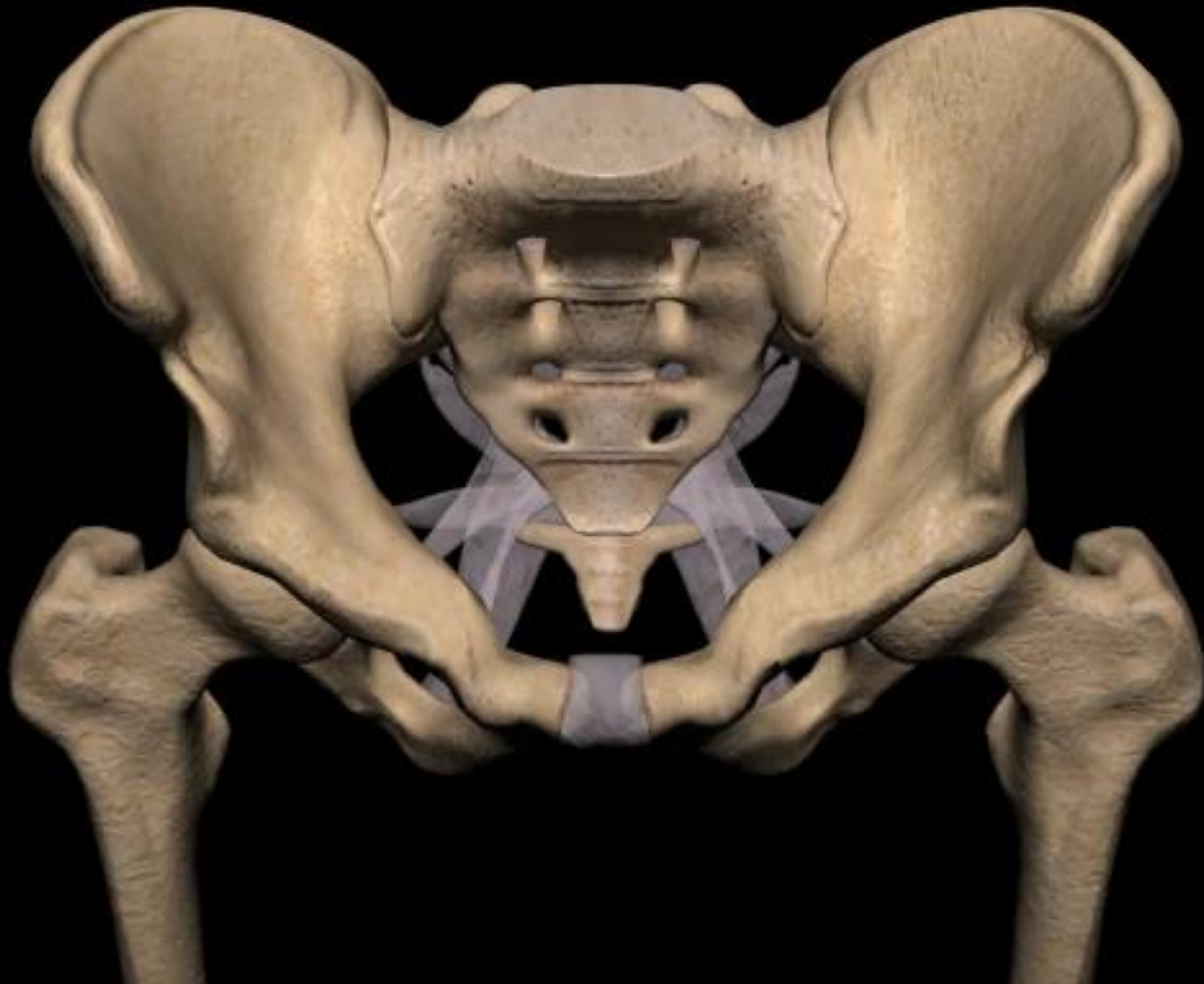

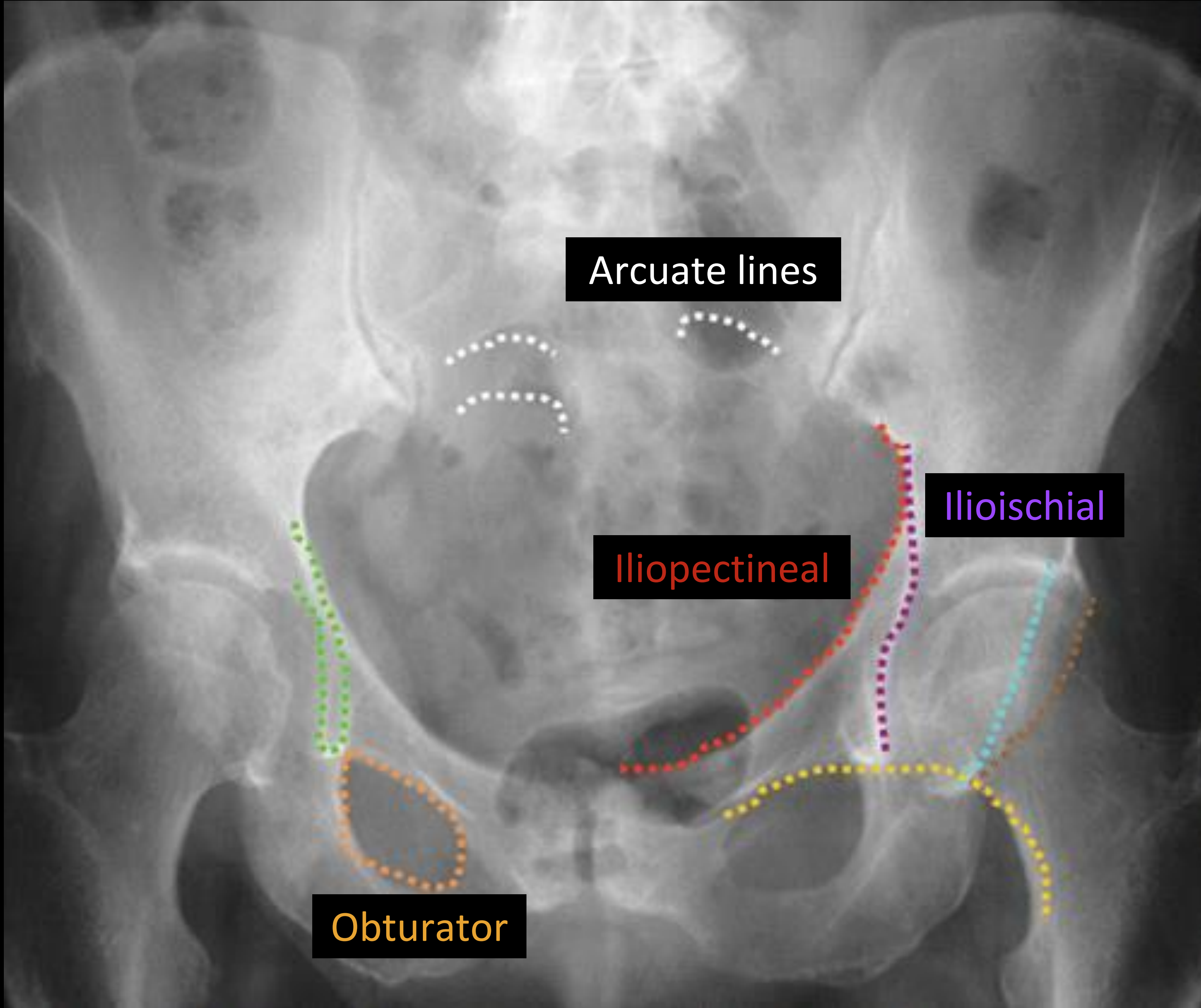
VS

Vertical Shear



LC 1



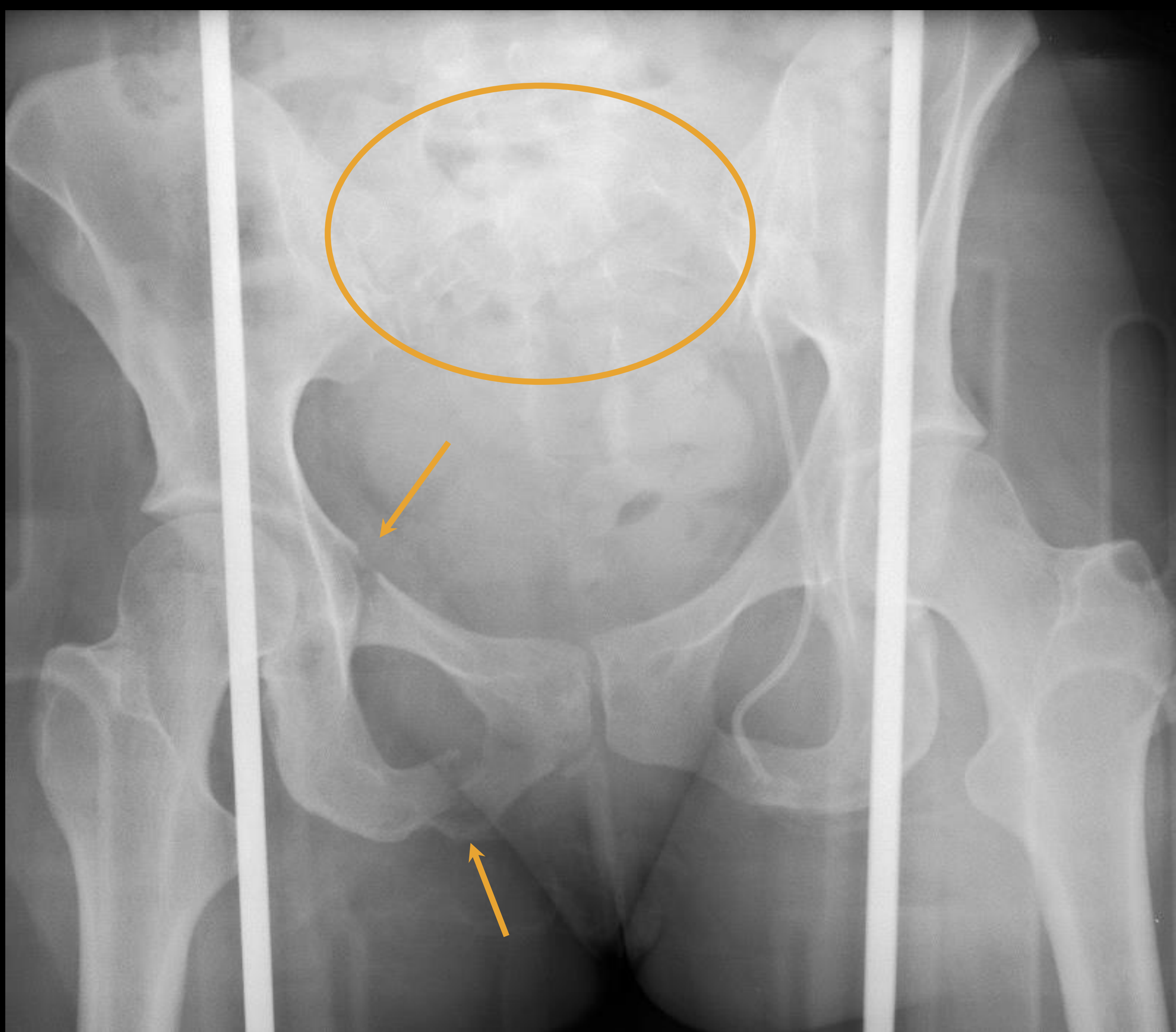


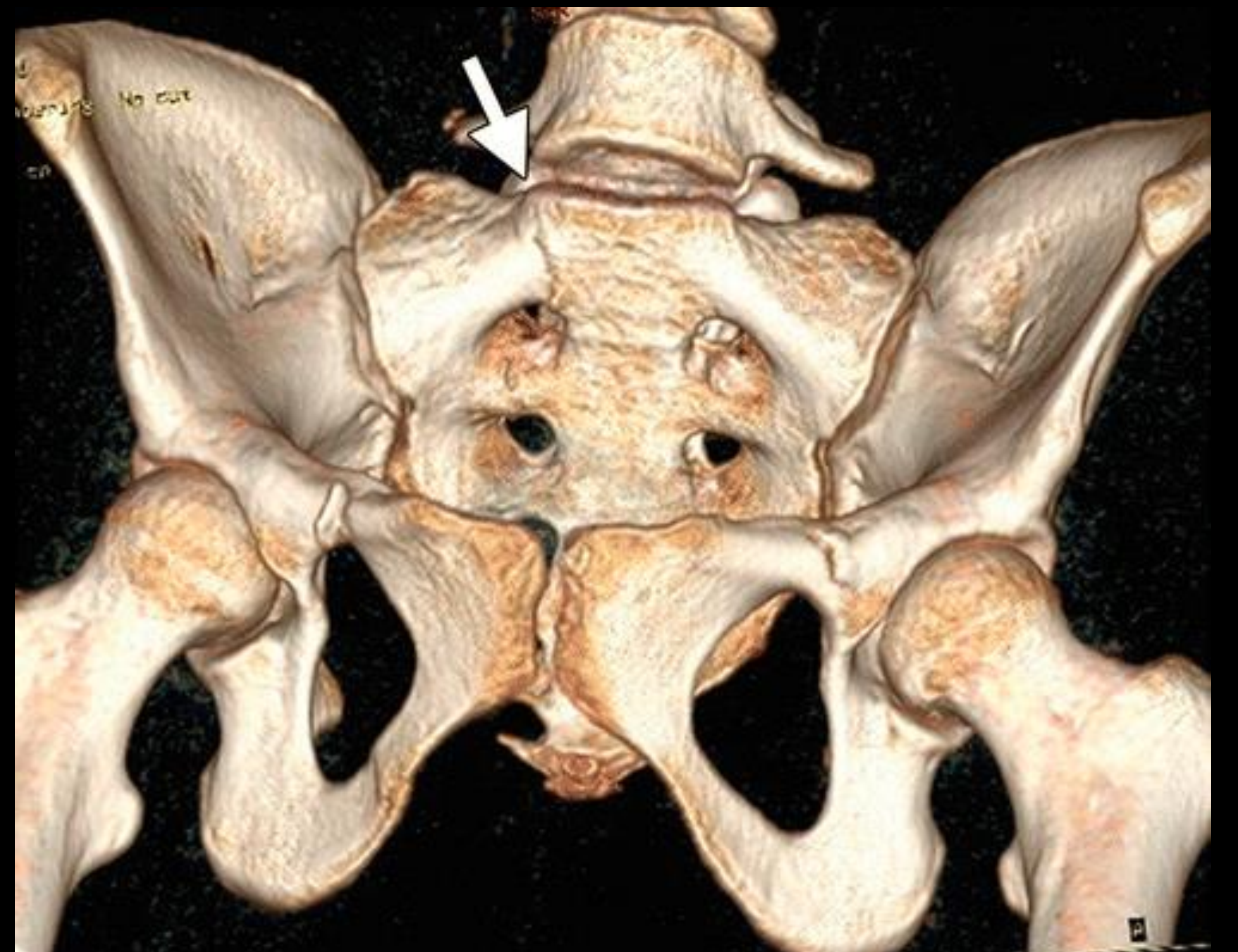
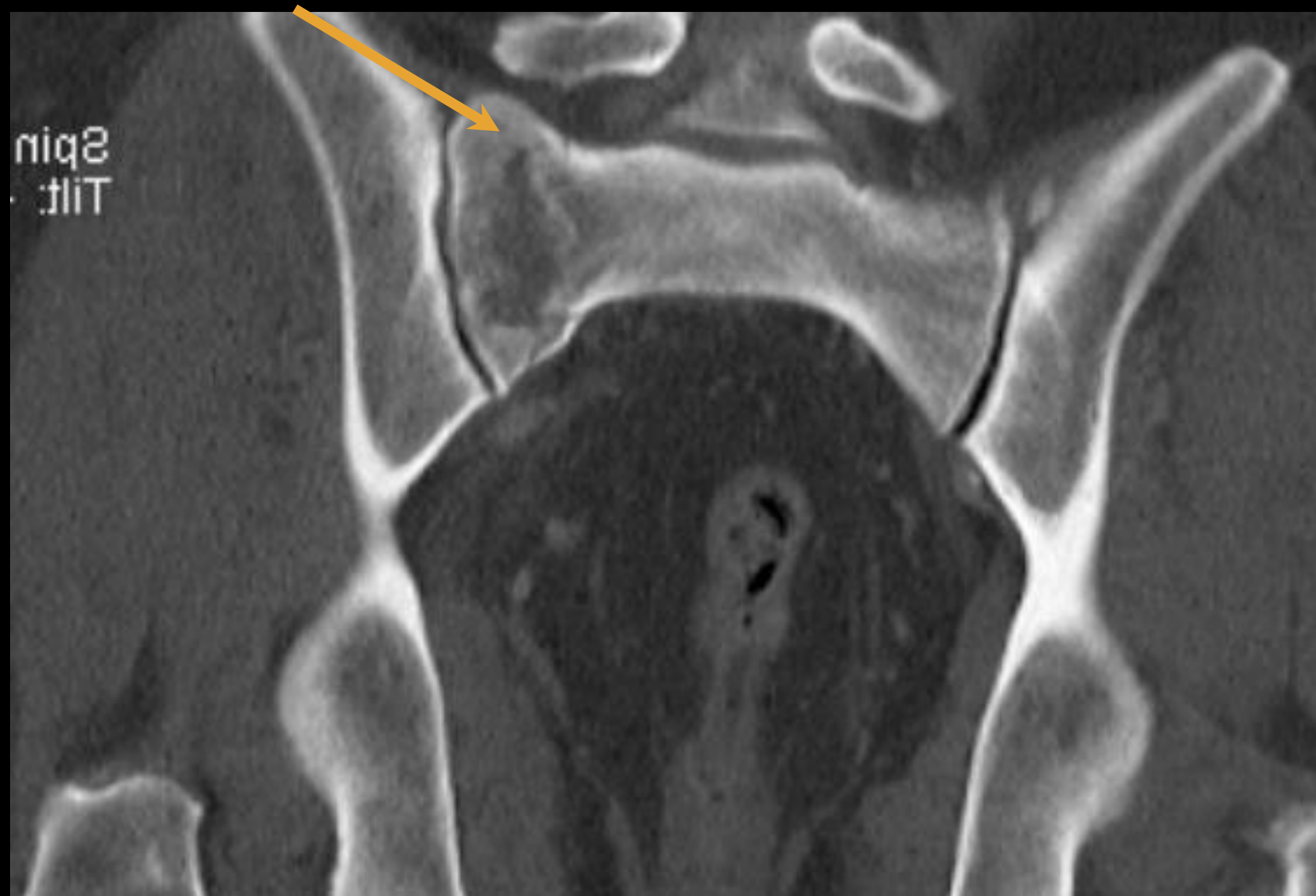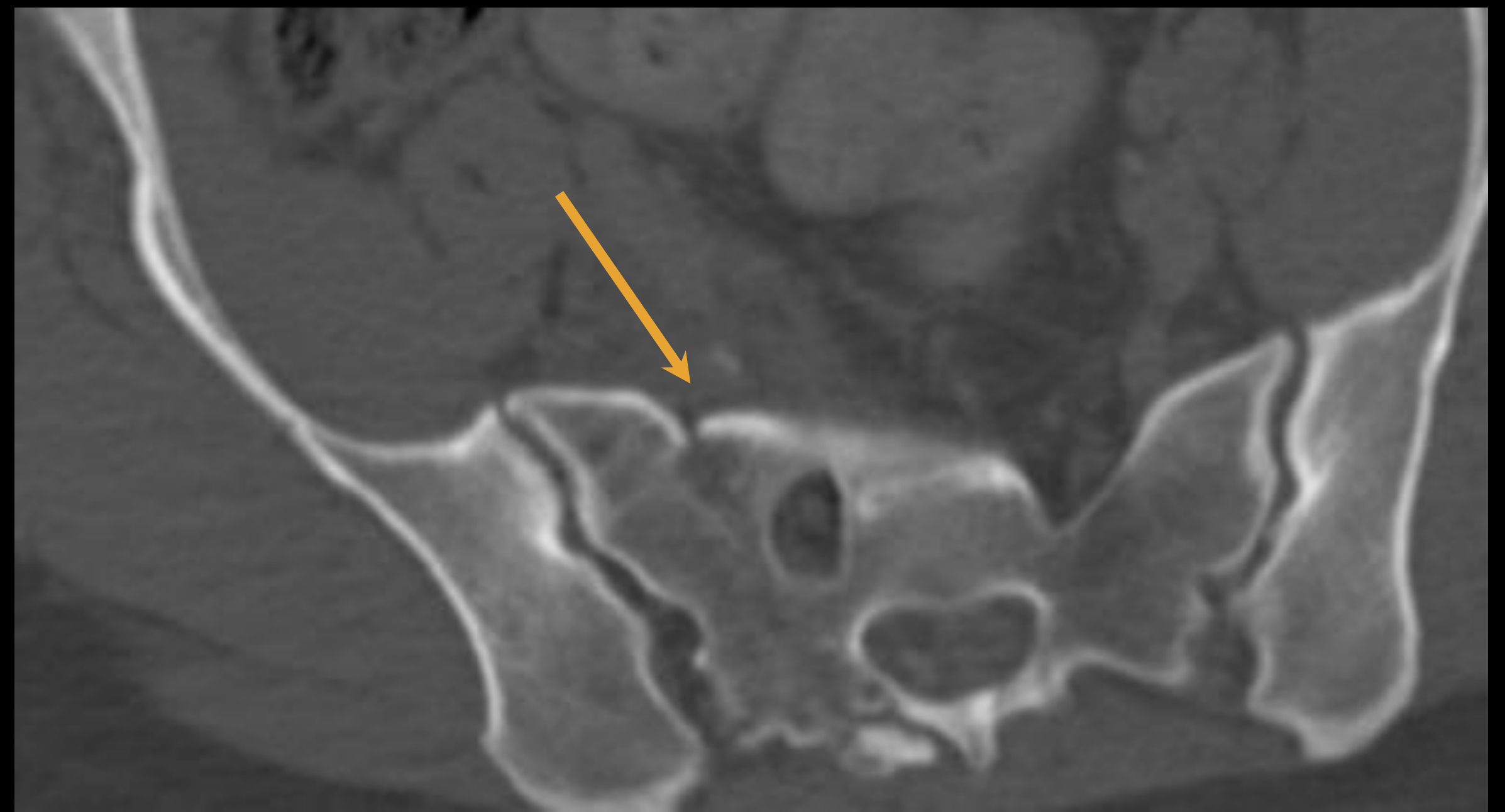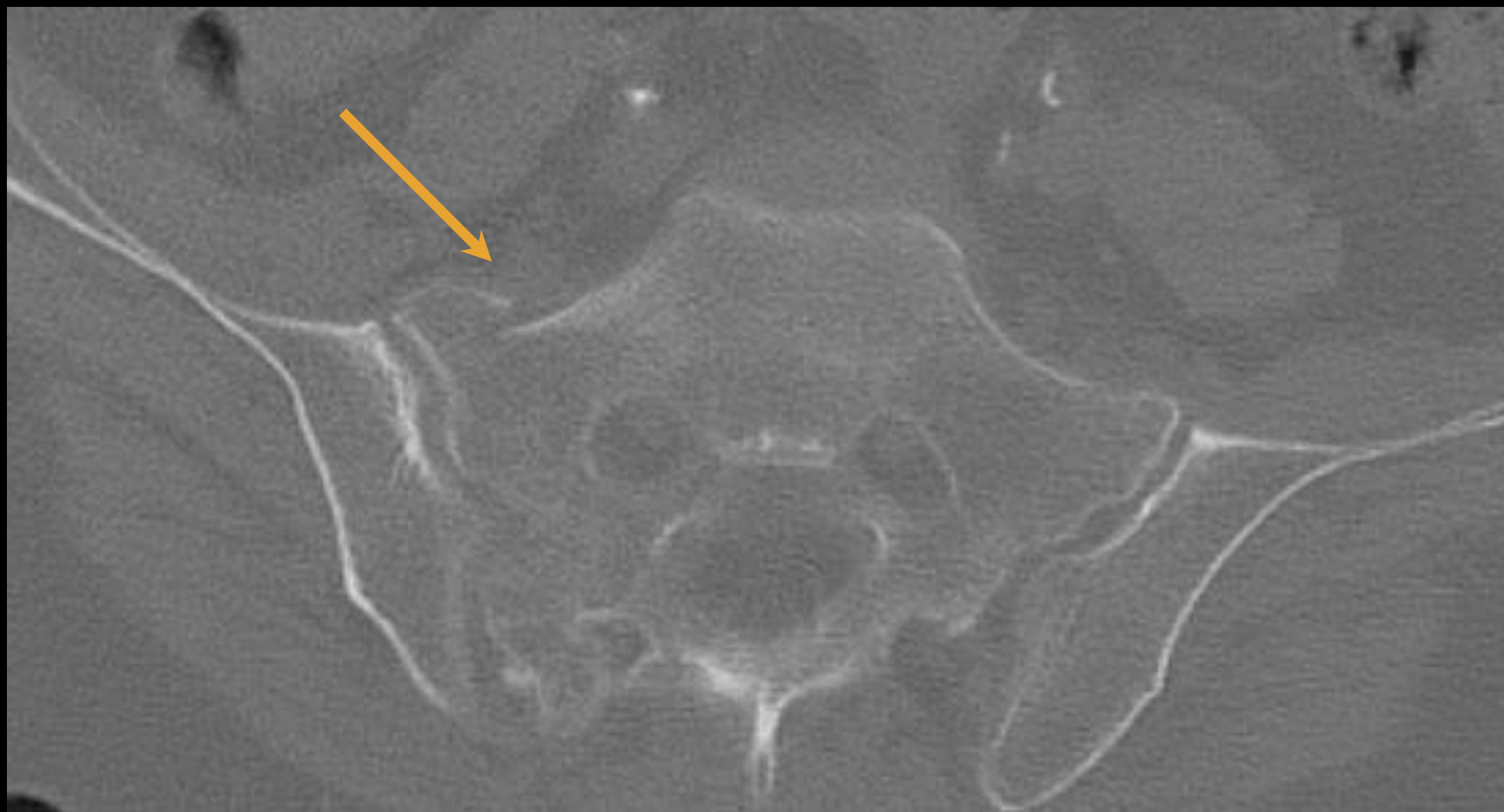
Arcuate lines

Ilioischial

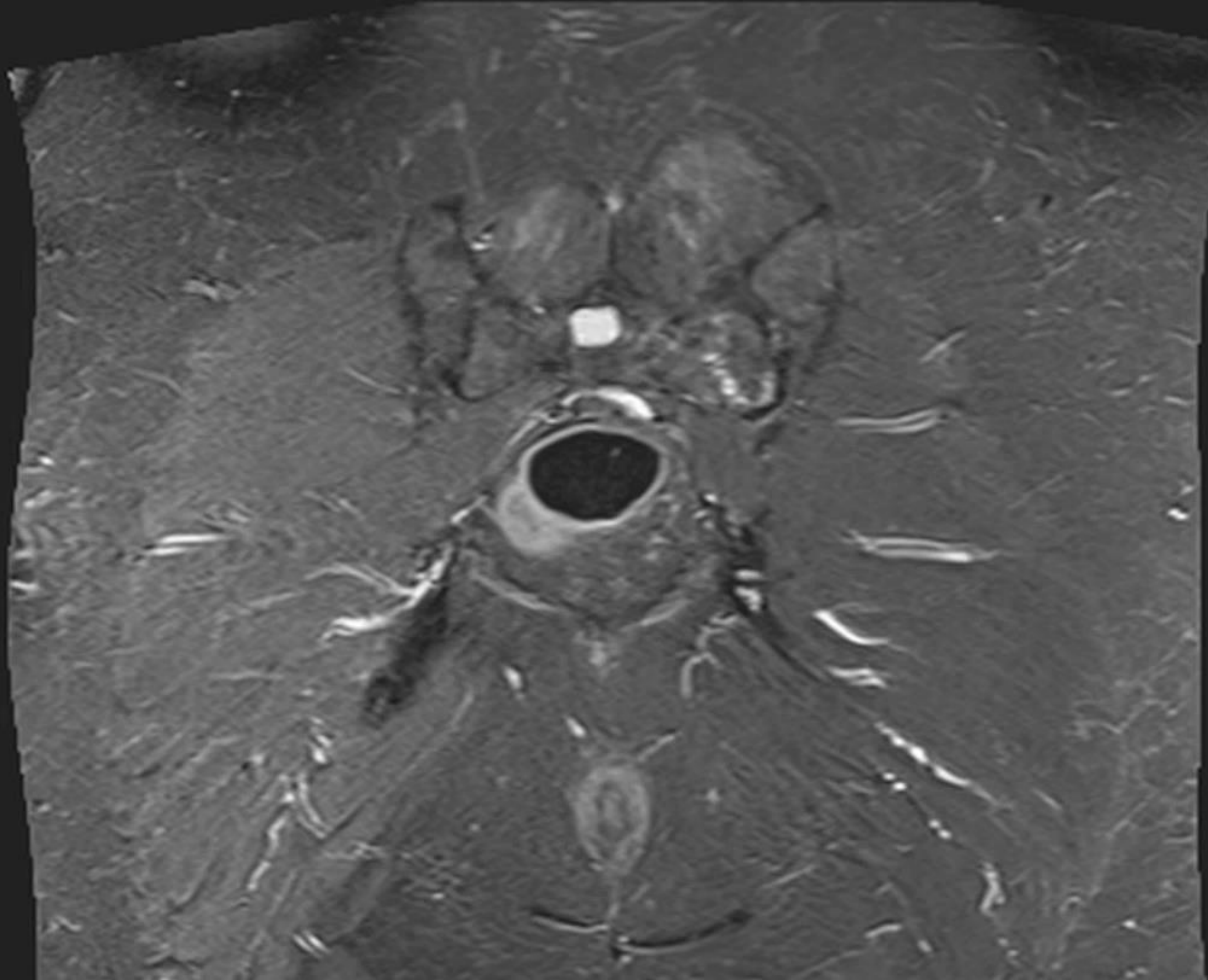
Iliopectineal

Obturator

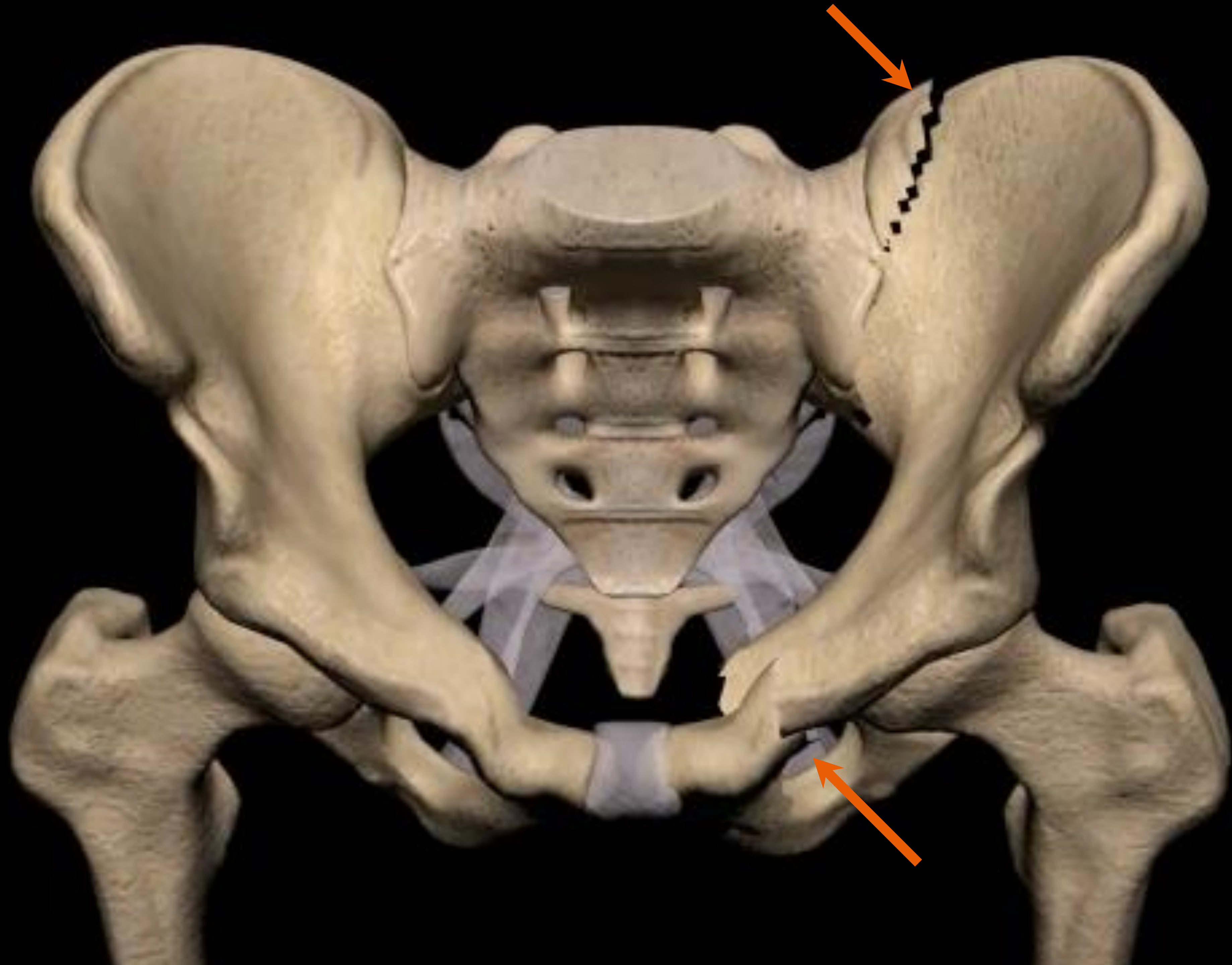




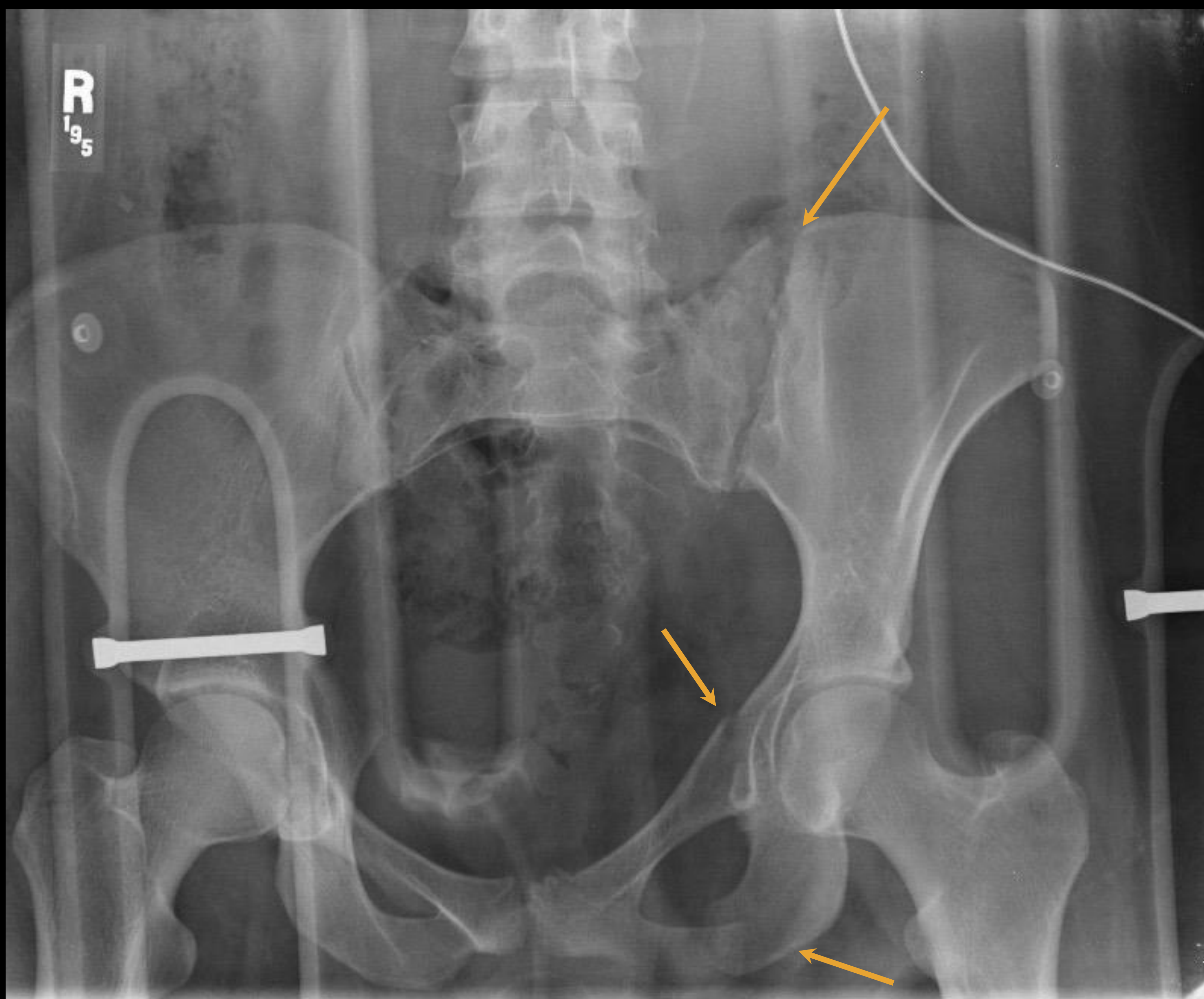
LC 1



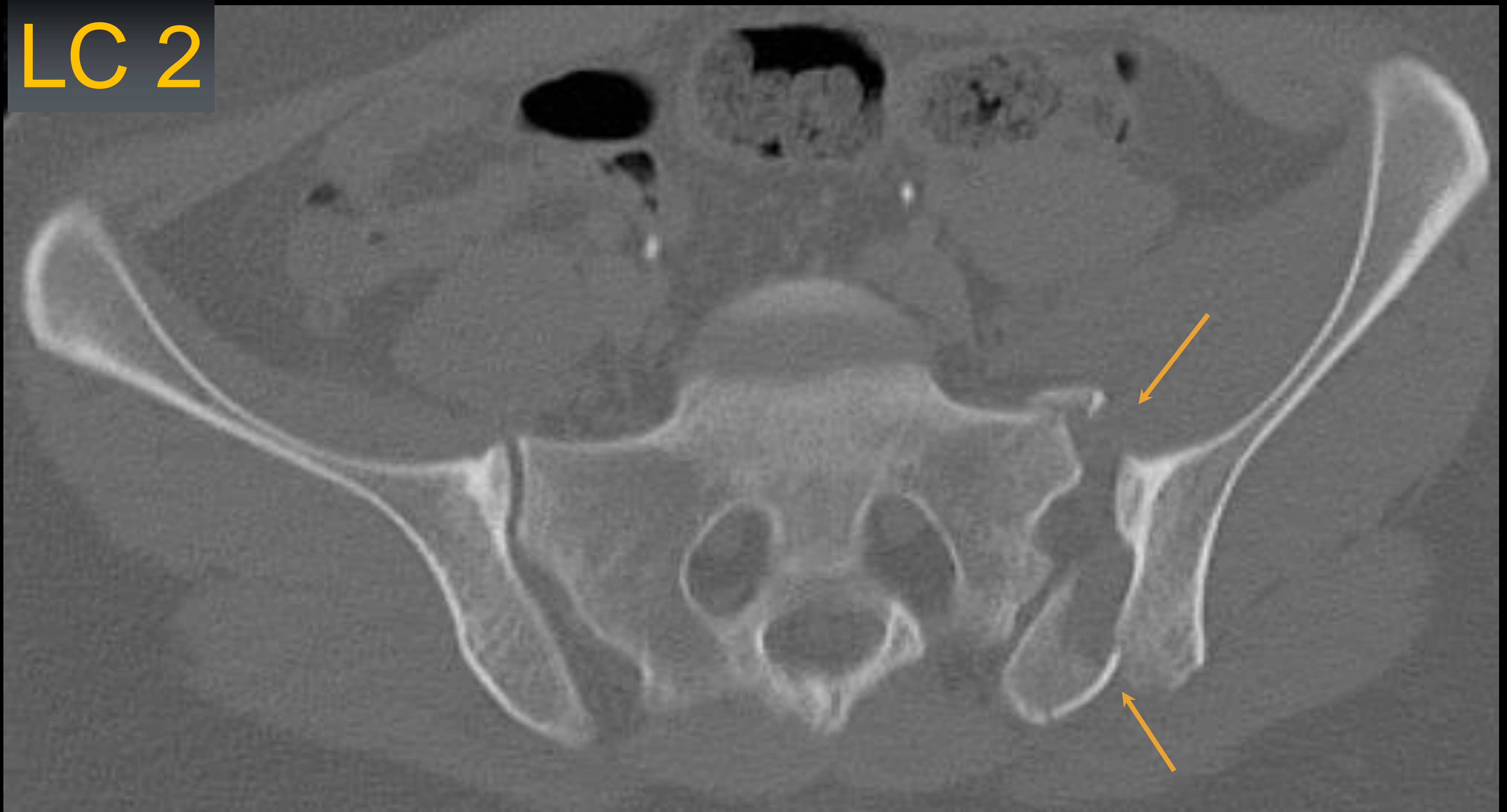
LC 2



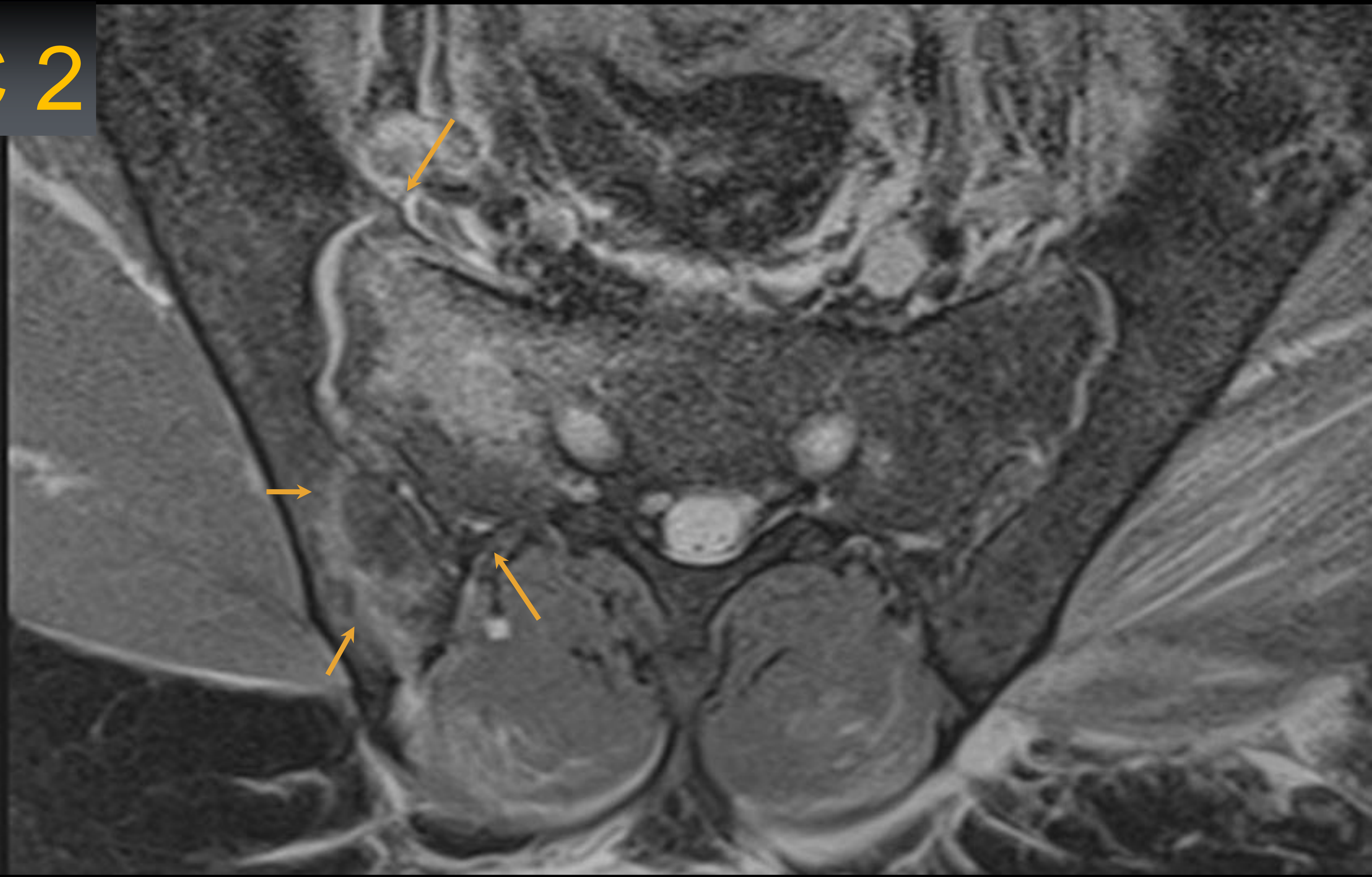
LC 2



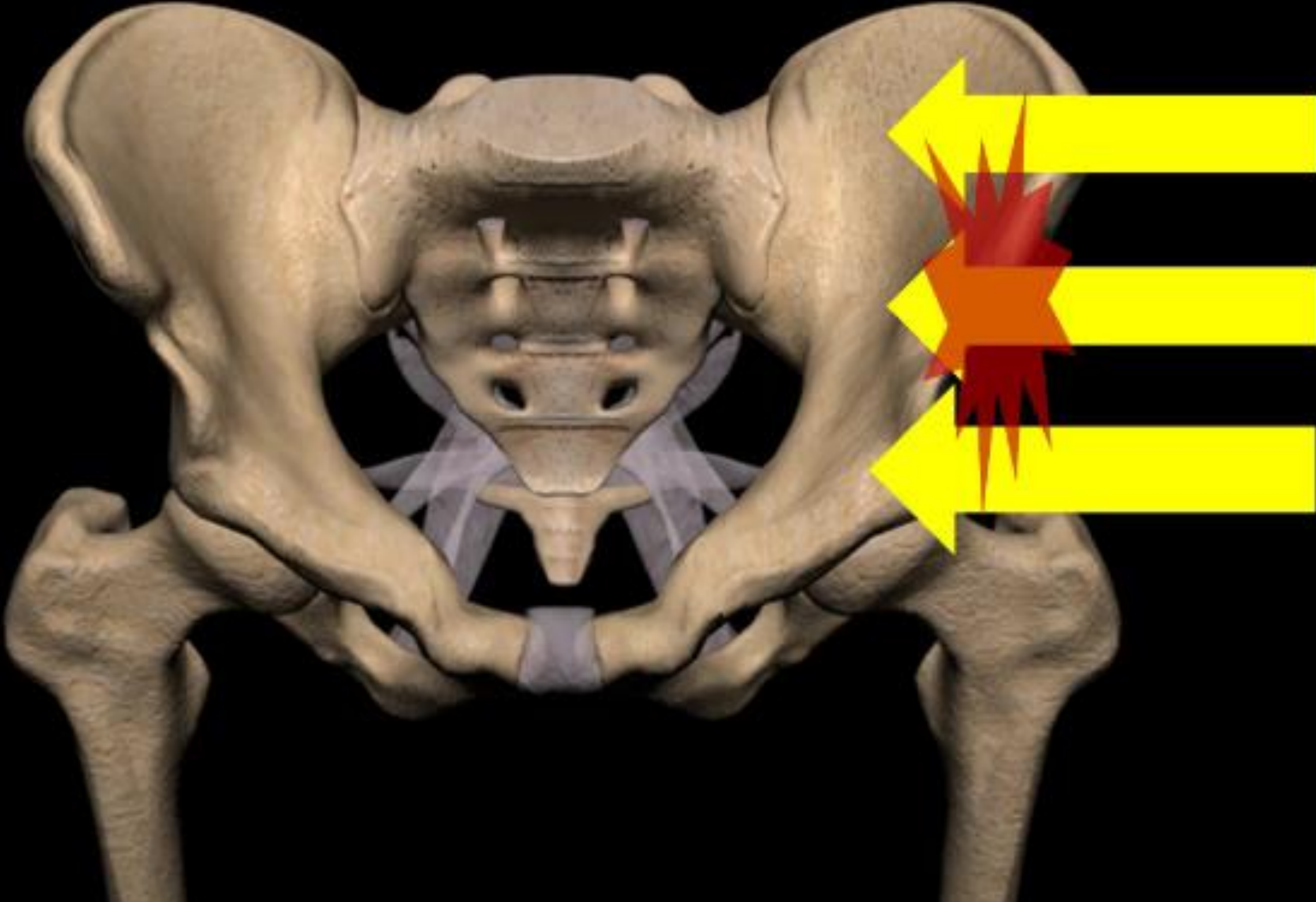
LC 2



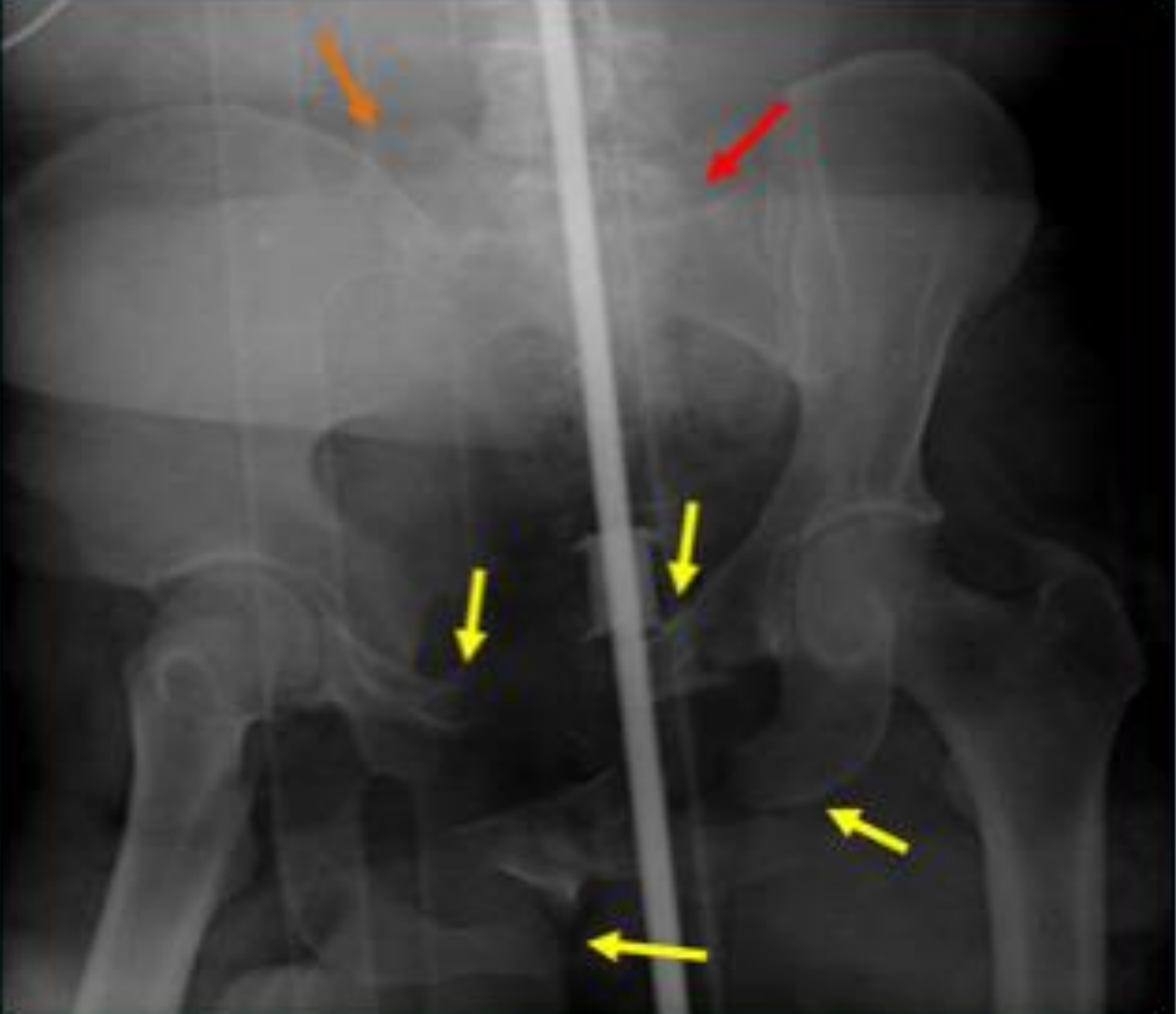LC 2

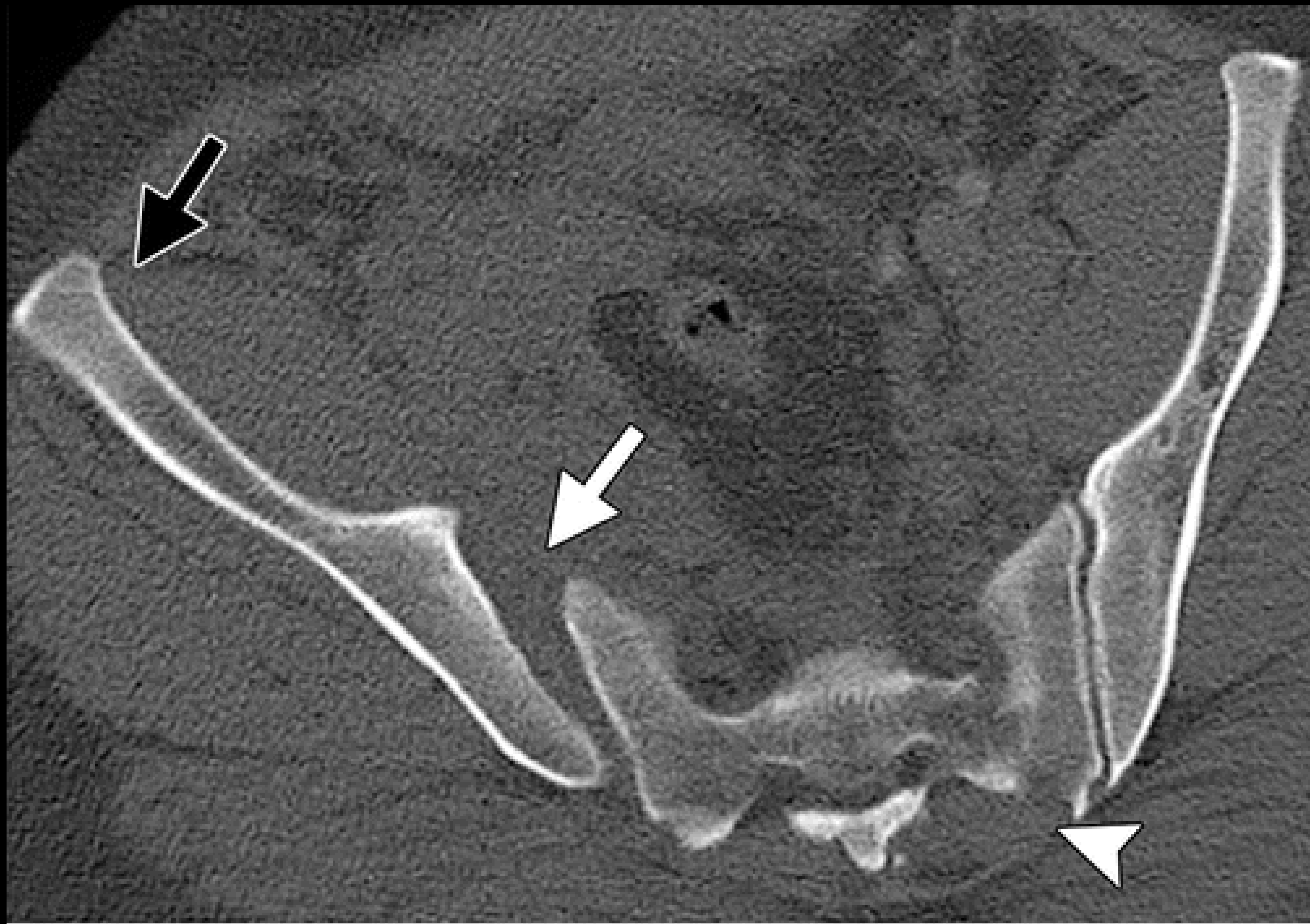


LC 3



LC 3

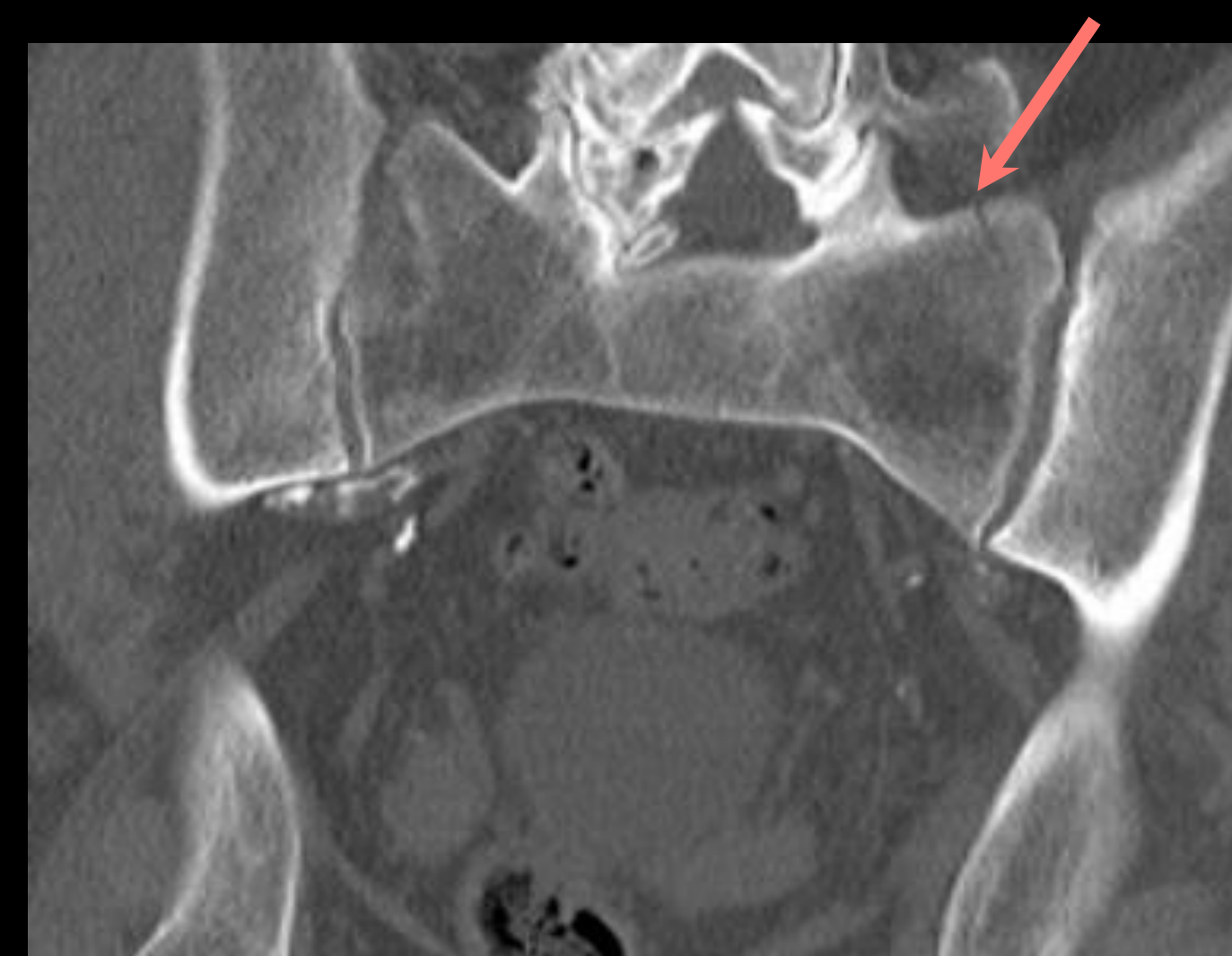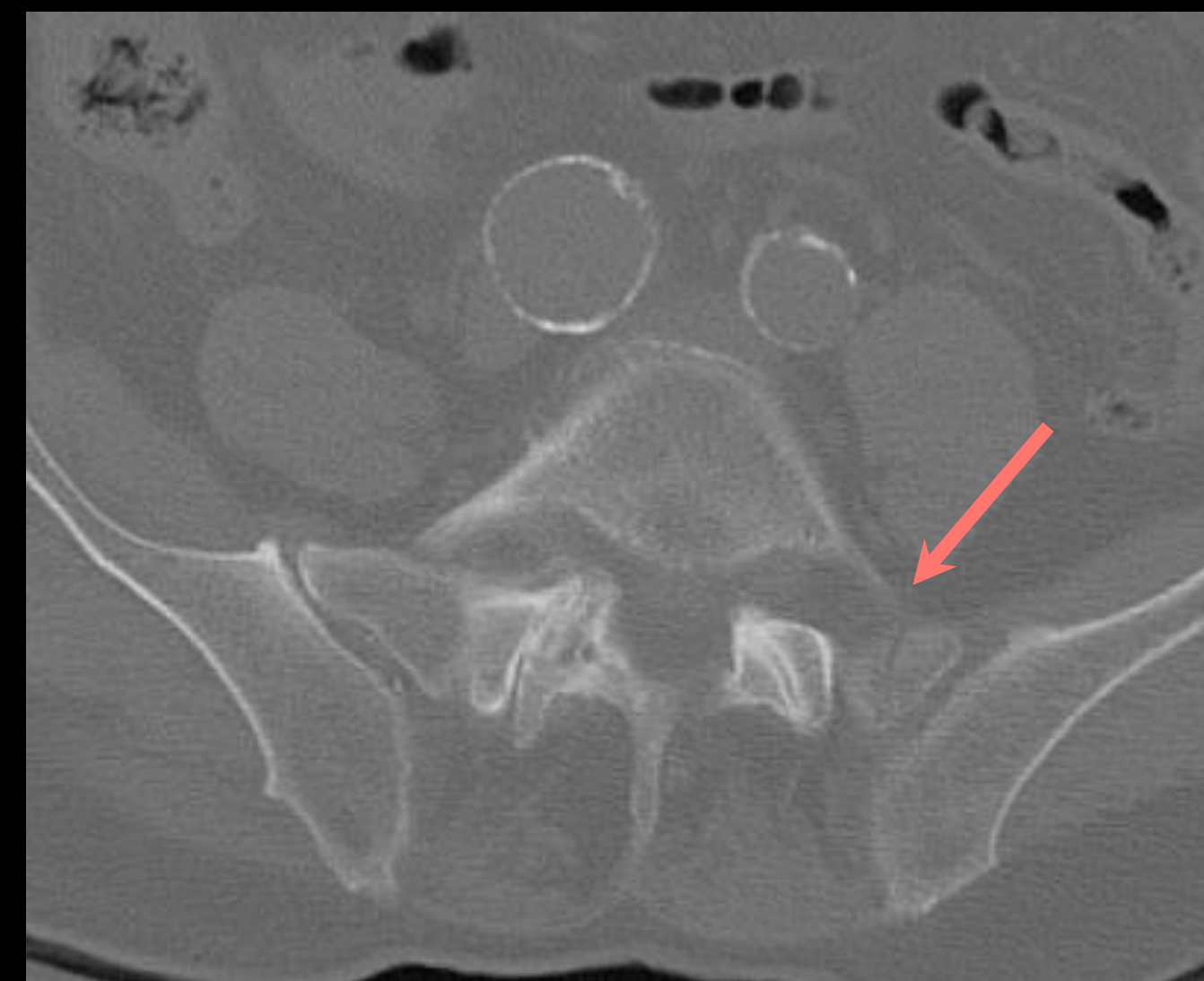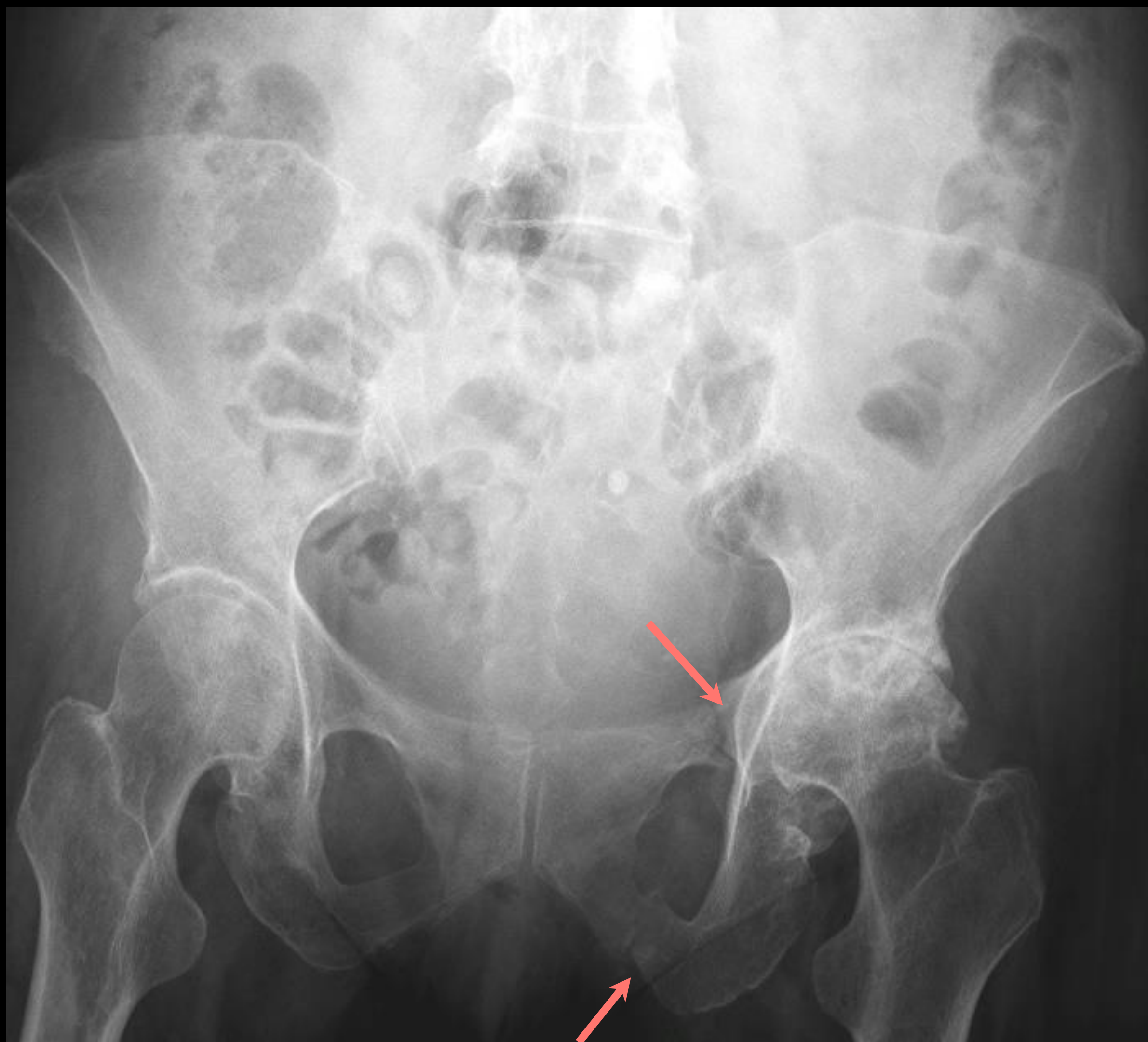




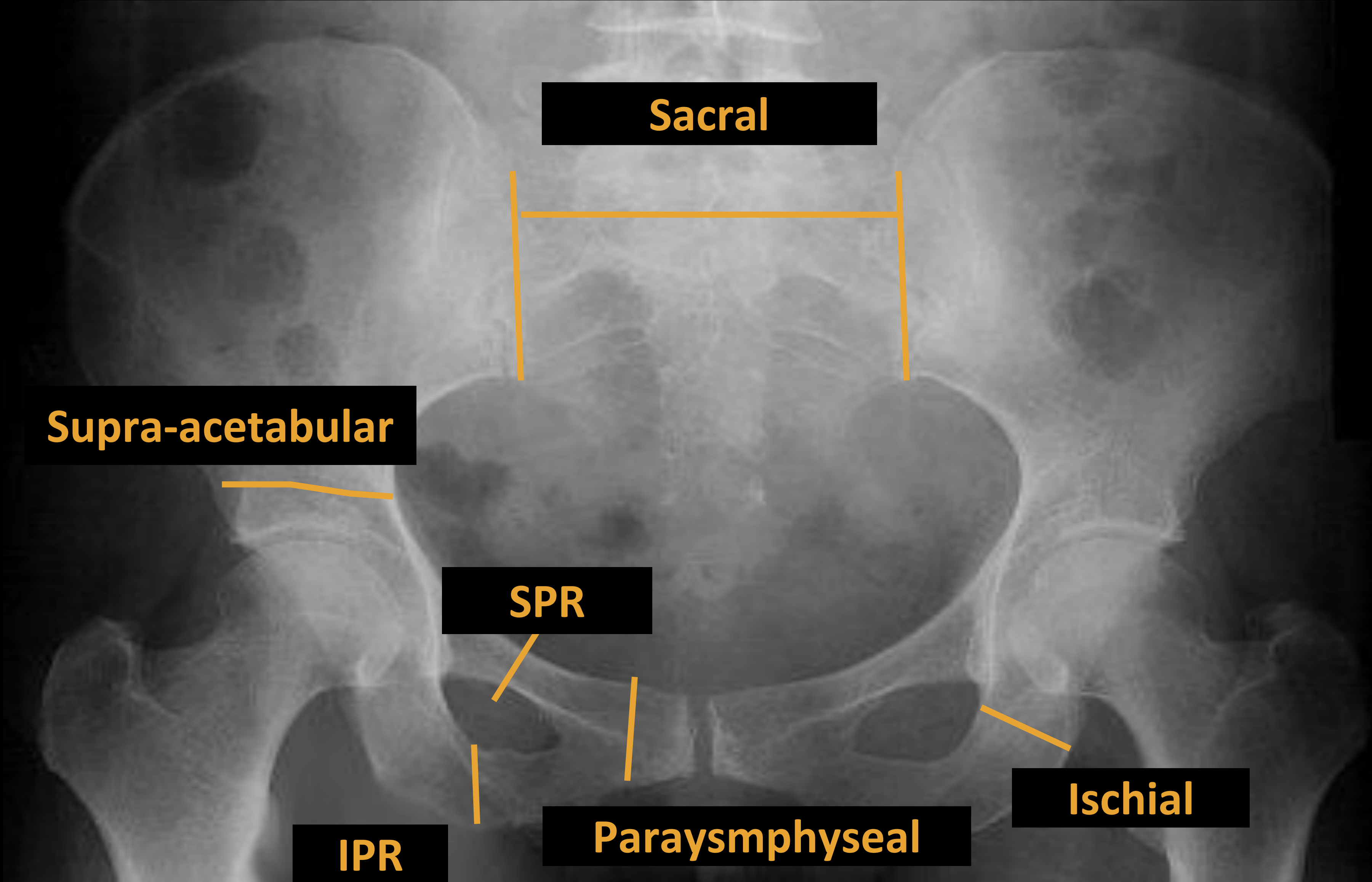
Lateral compression injury

- PUBIC RAMI FRACTURES
 - LC1: Sacral compression fracture
 - LC 2: Crescent fracture of posterior ilium
 - LC 3: Windswept pelvis

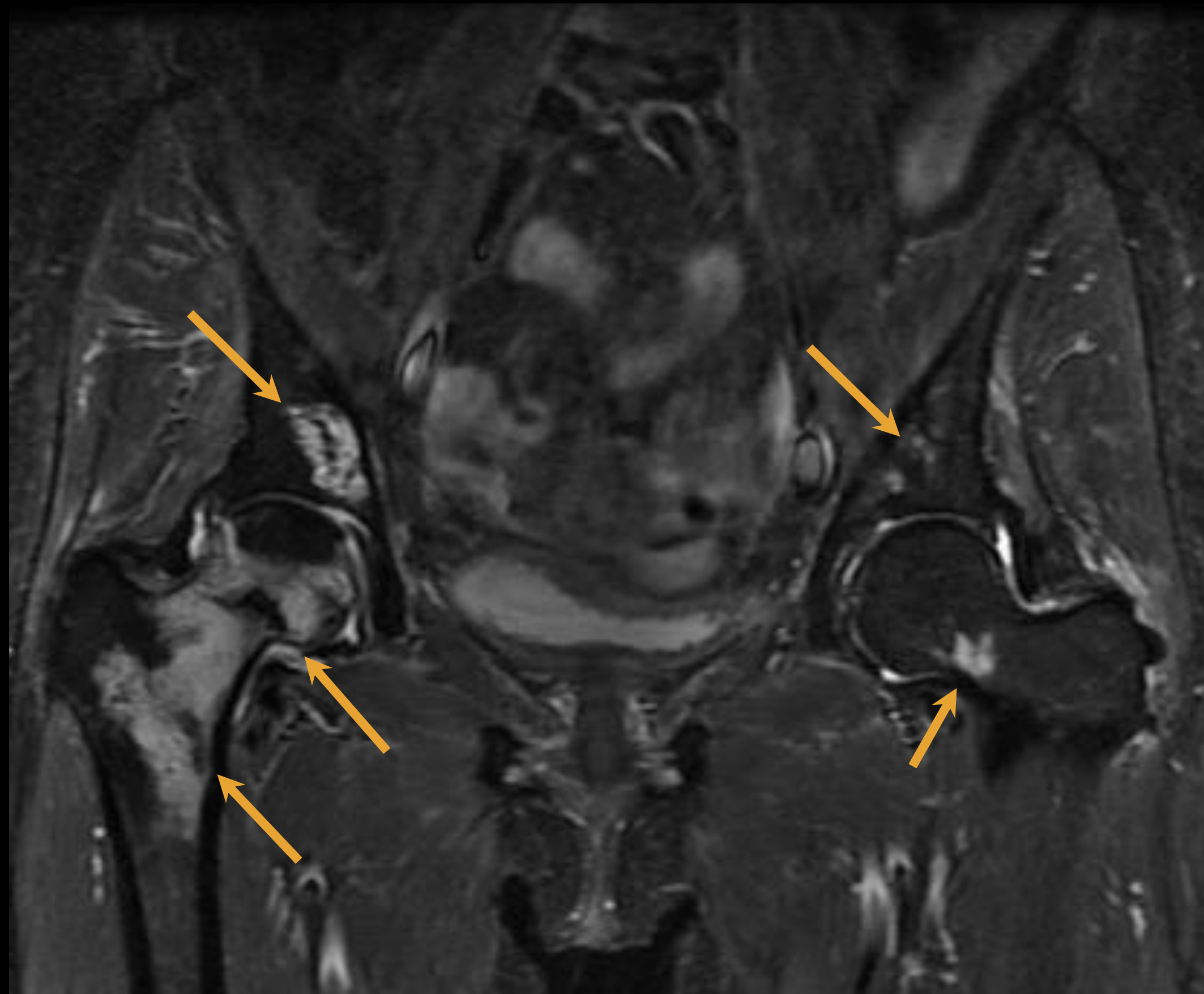
Lateral Compression injuries



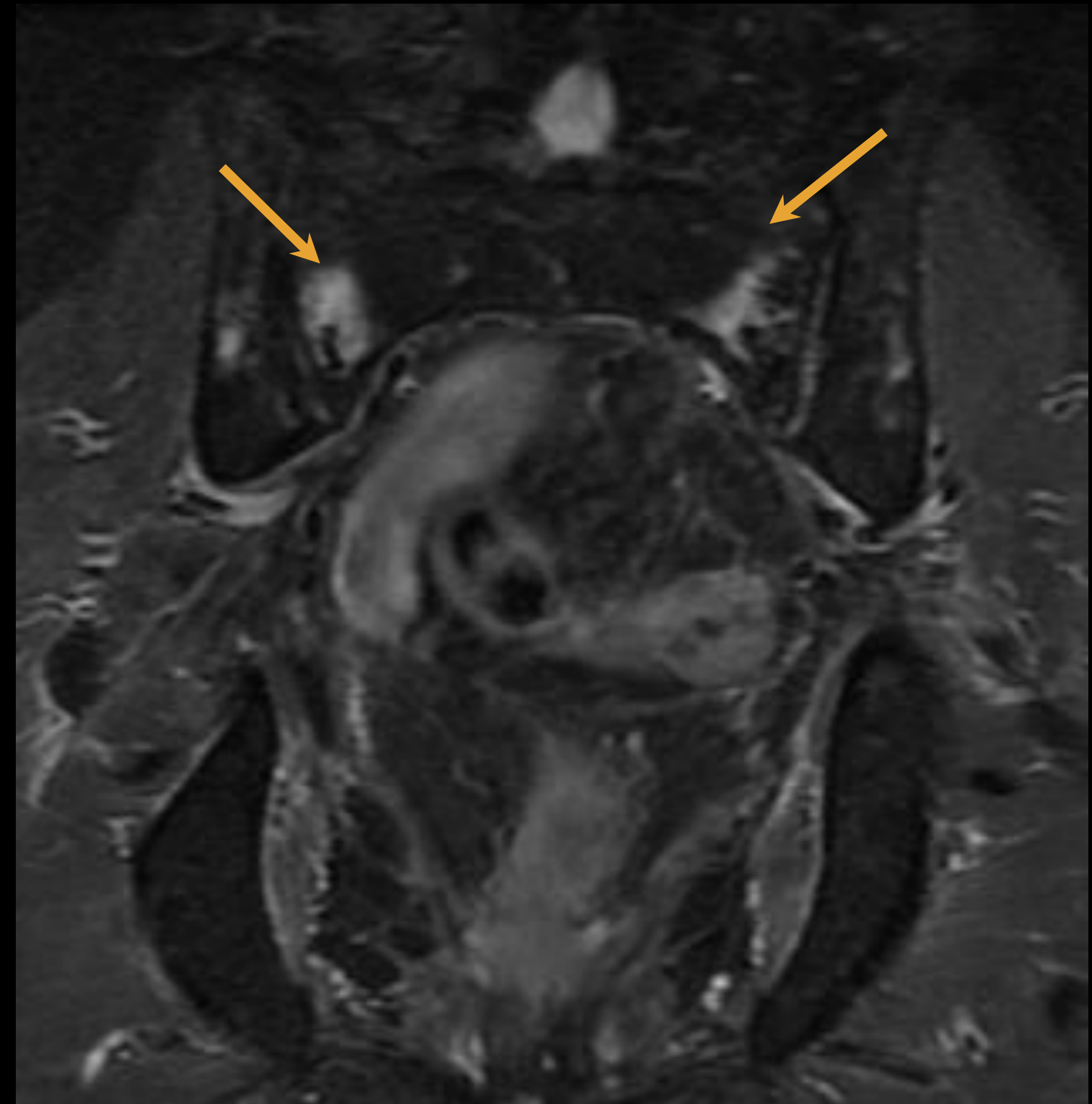
Insufficiency Fx



Insufficiency Fx

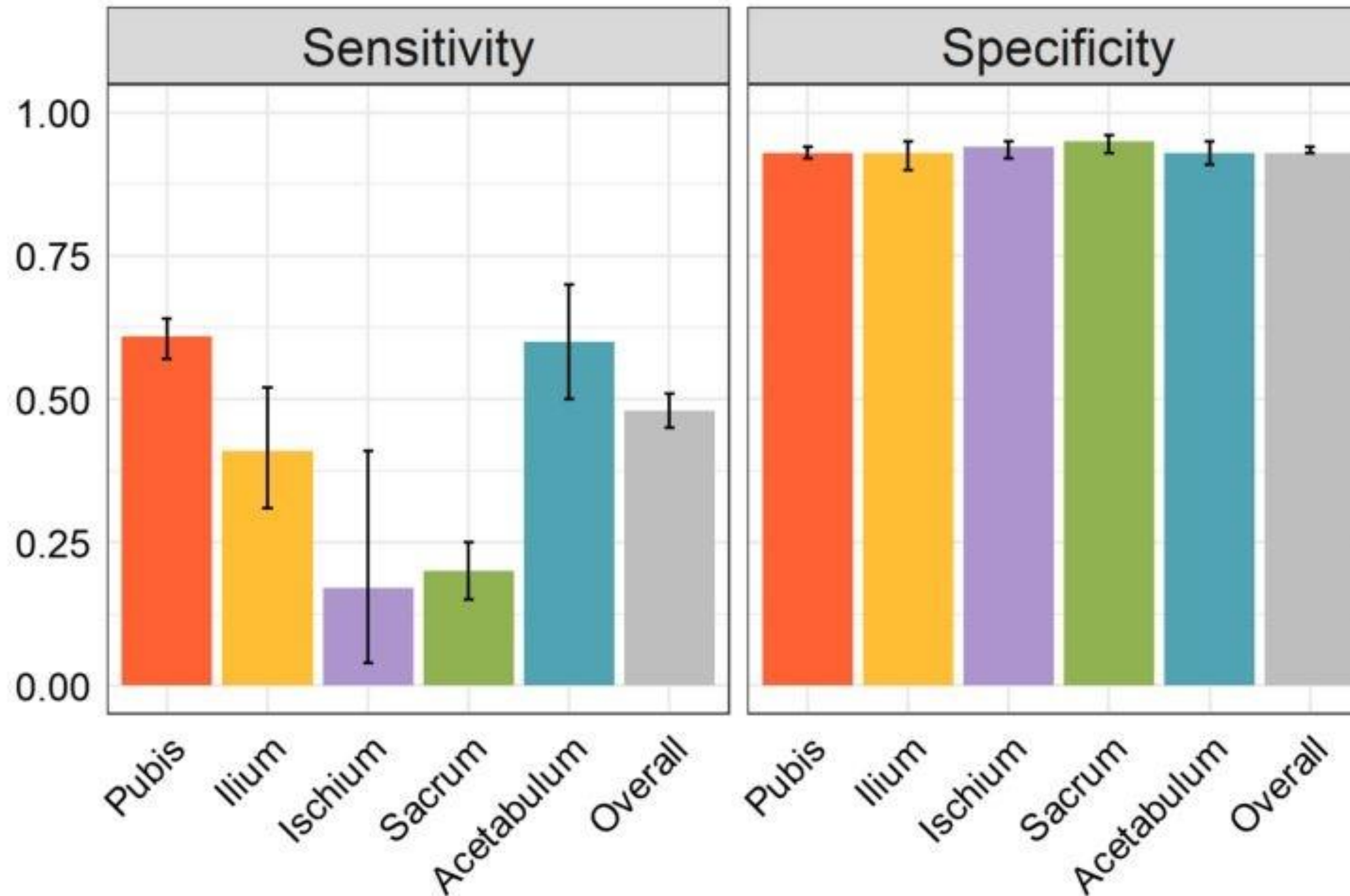


STIR Cor

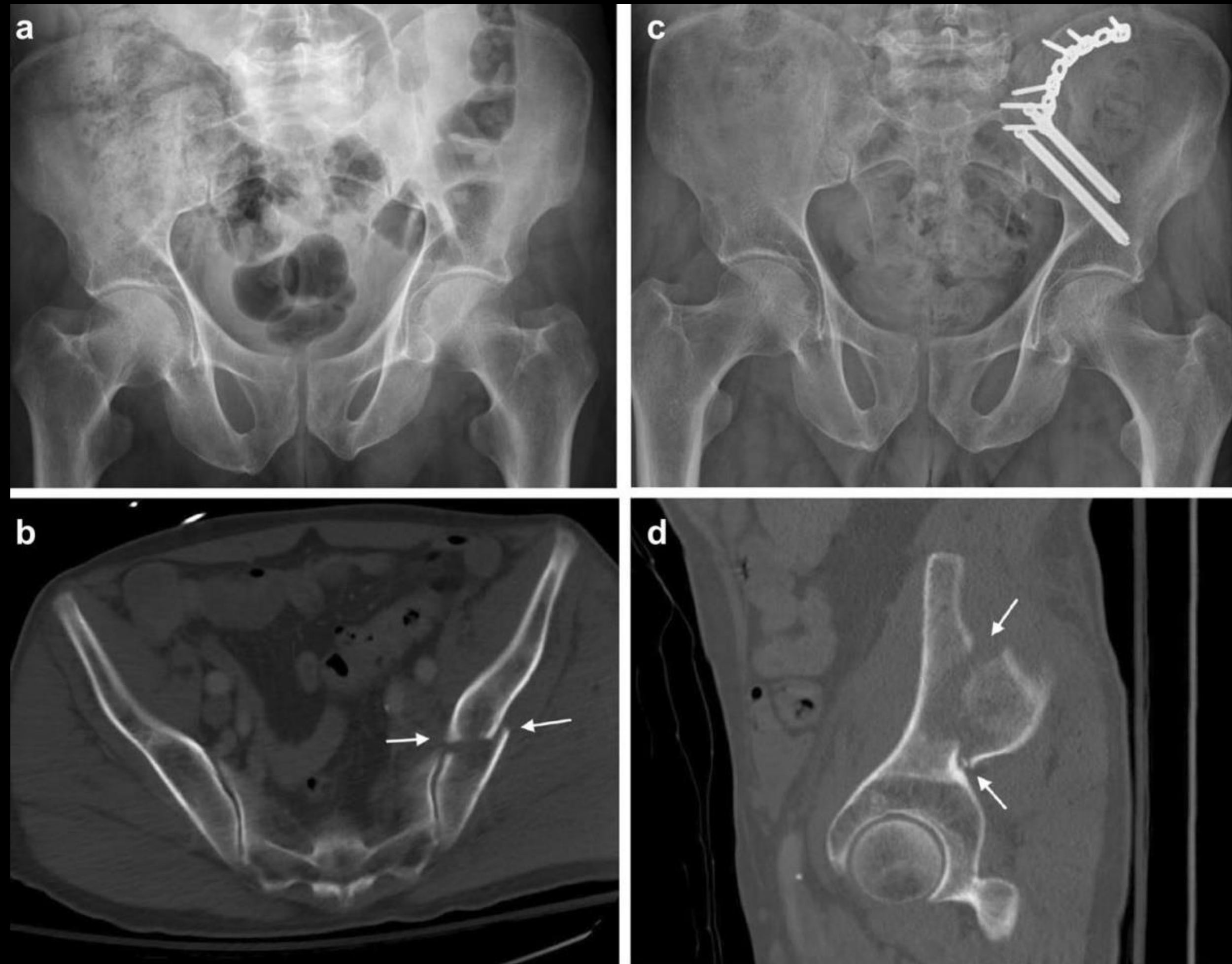

STIR Cor

Traumatic Pelvic Fractures in the Elderly



Traumatic Pelvic Fractures in the Elderly



Emergency Radiology (2022) 29:1009–1018
<https://doi.org/10.1007/s10140-022-02090-w>

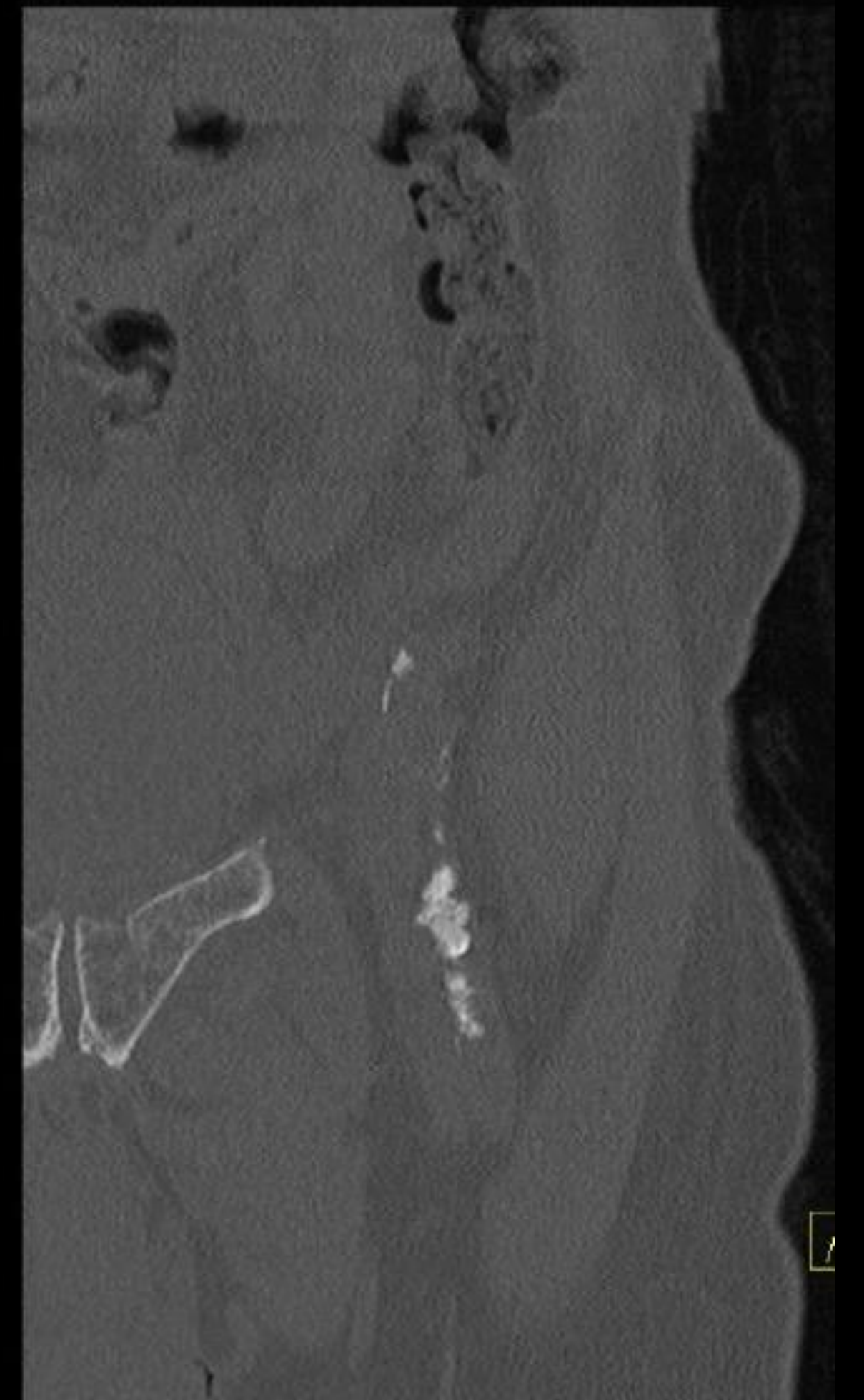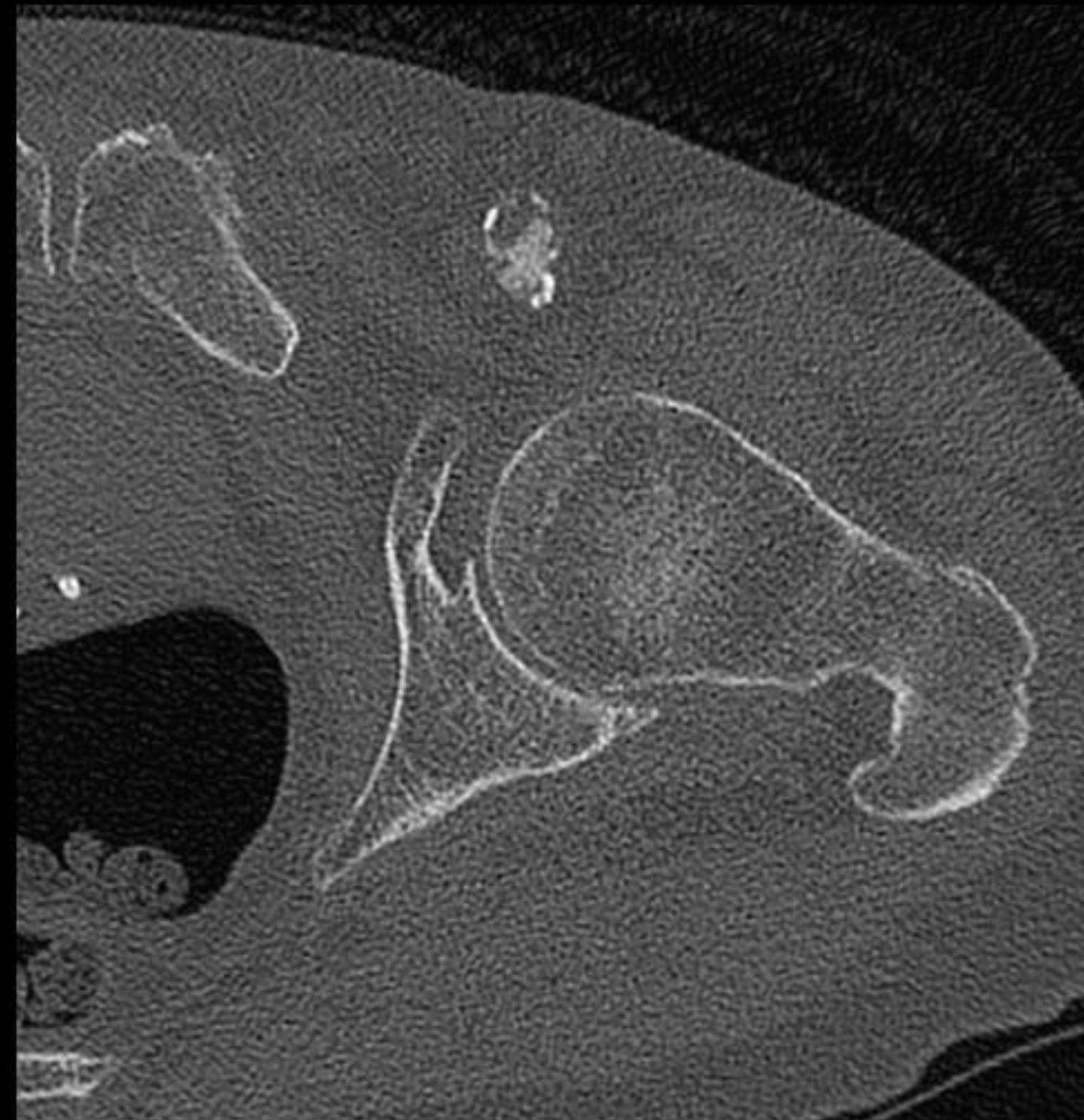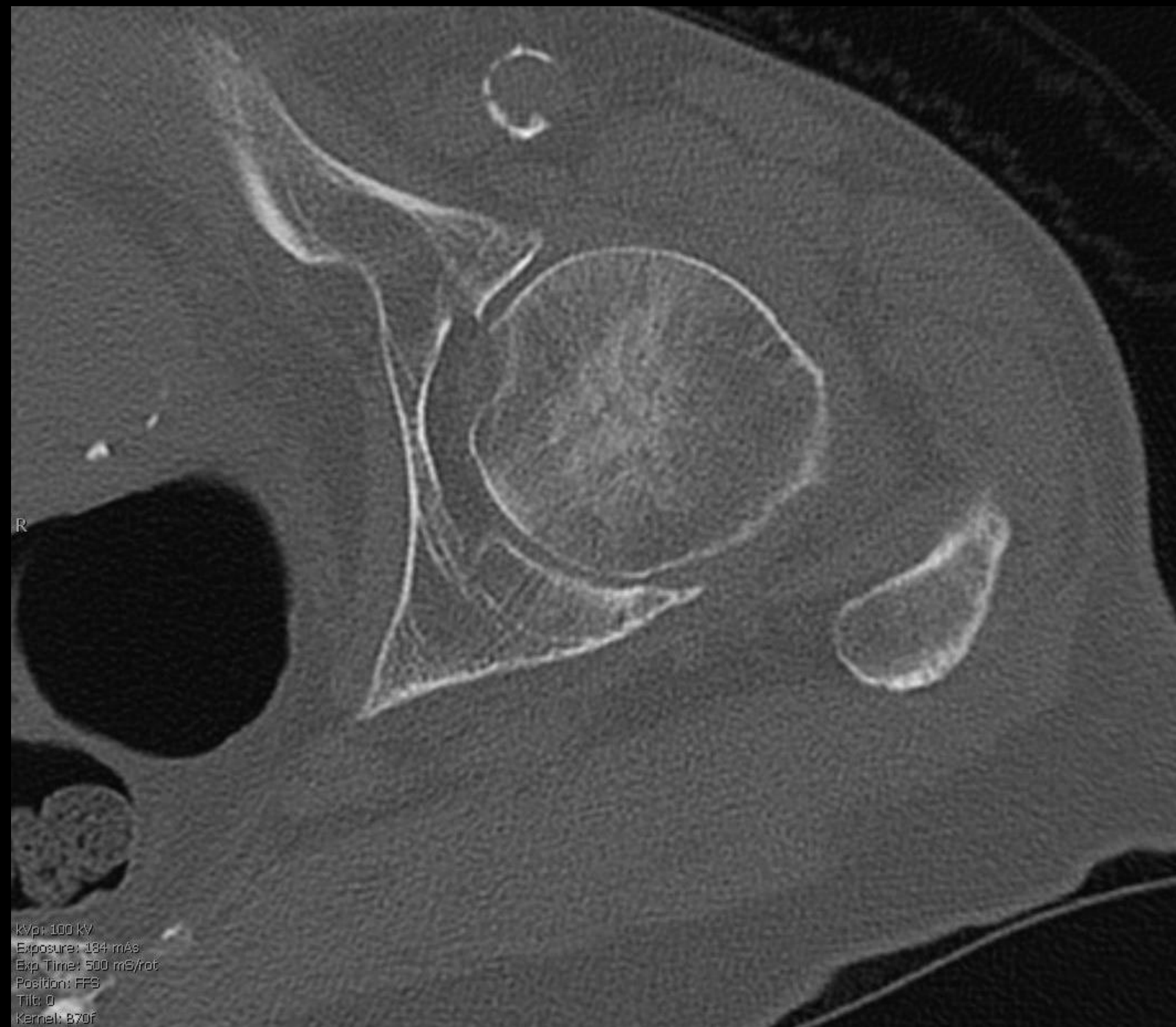ORIGINAL ARTICLE



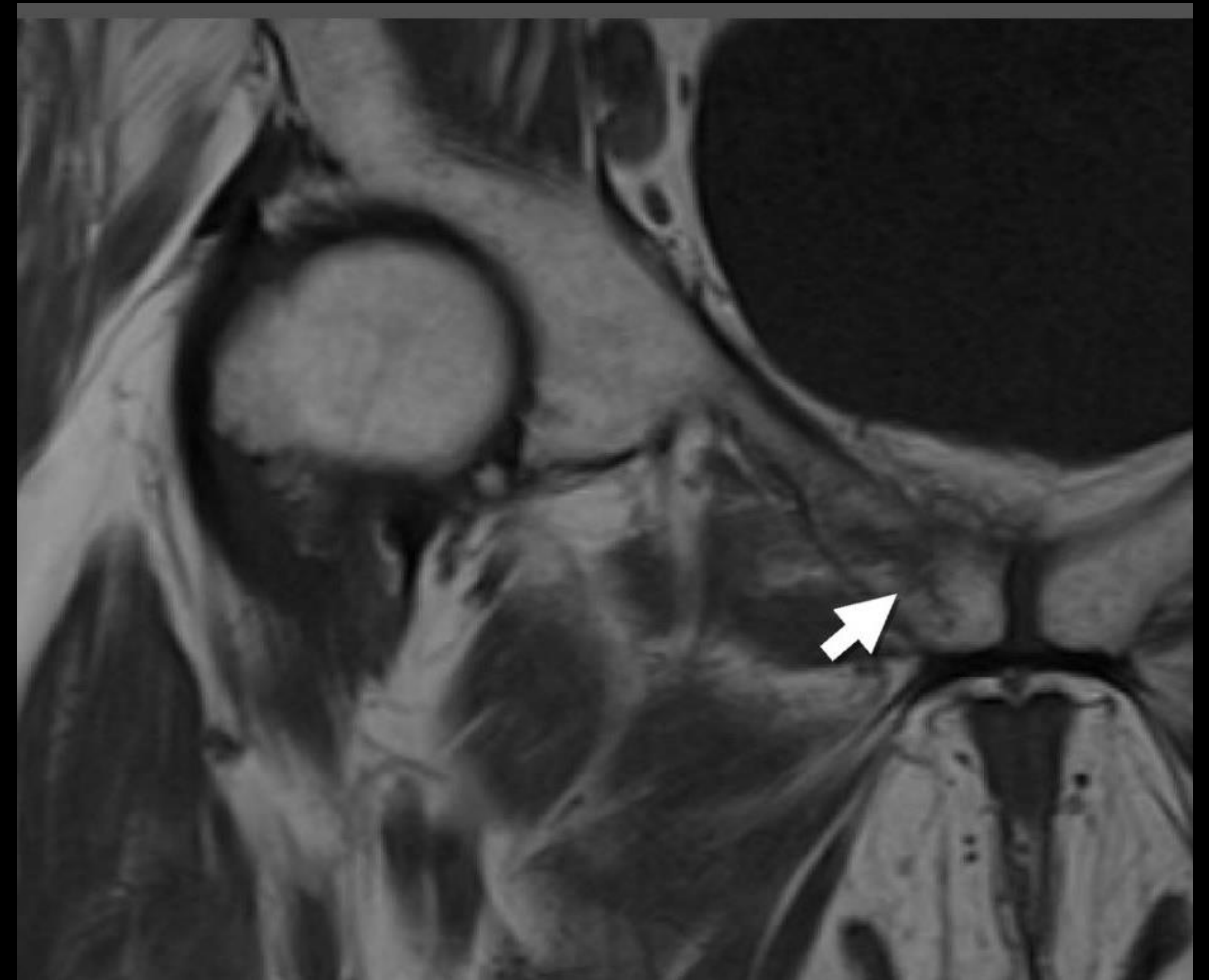
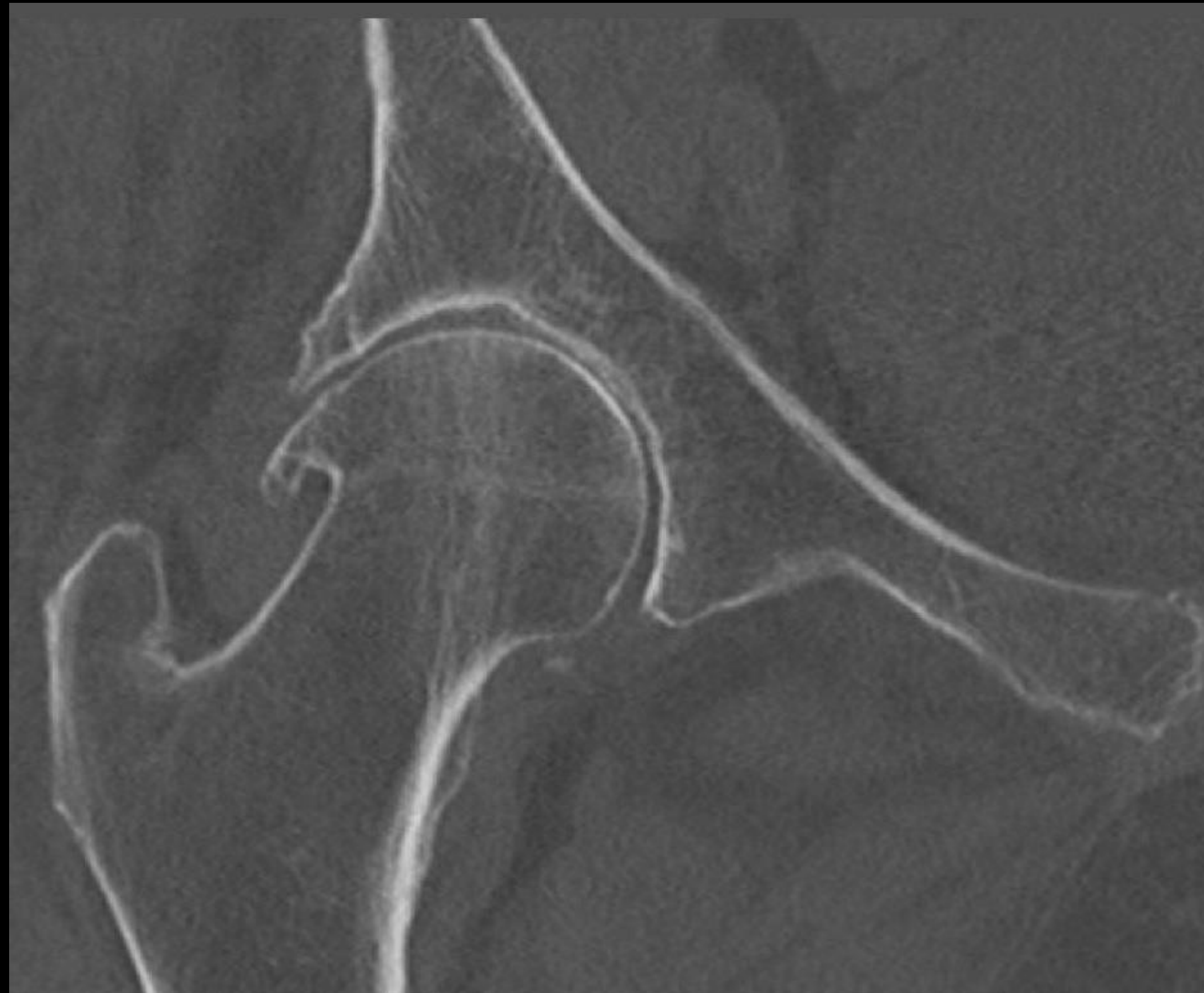Diagnostic accuracy of pelvic radiographs for the detection of traumatic pelvic fractures in the elderly

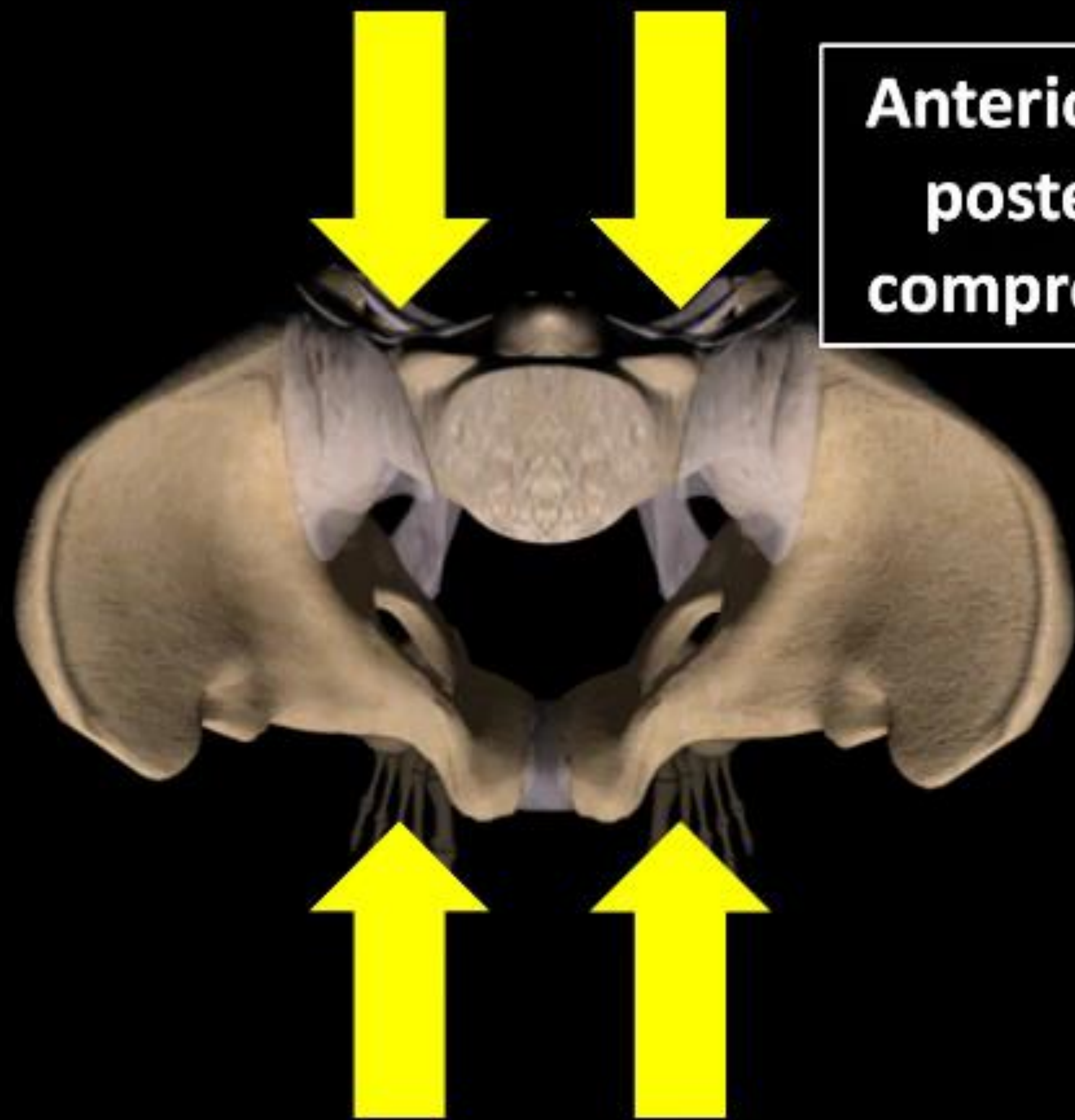
Yuntong Ma¹ · Jacob C. Mandell¹ · Tatiana Rocha¹ · Maria ADuran Mendicuti¹ · Michael J. Weaver² · Bharti Khurana¹

SPR Fx on Hip CT



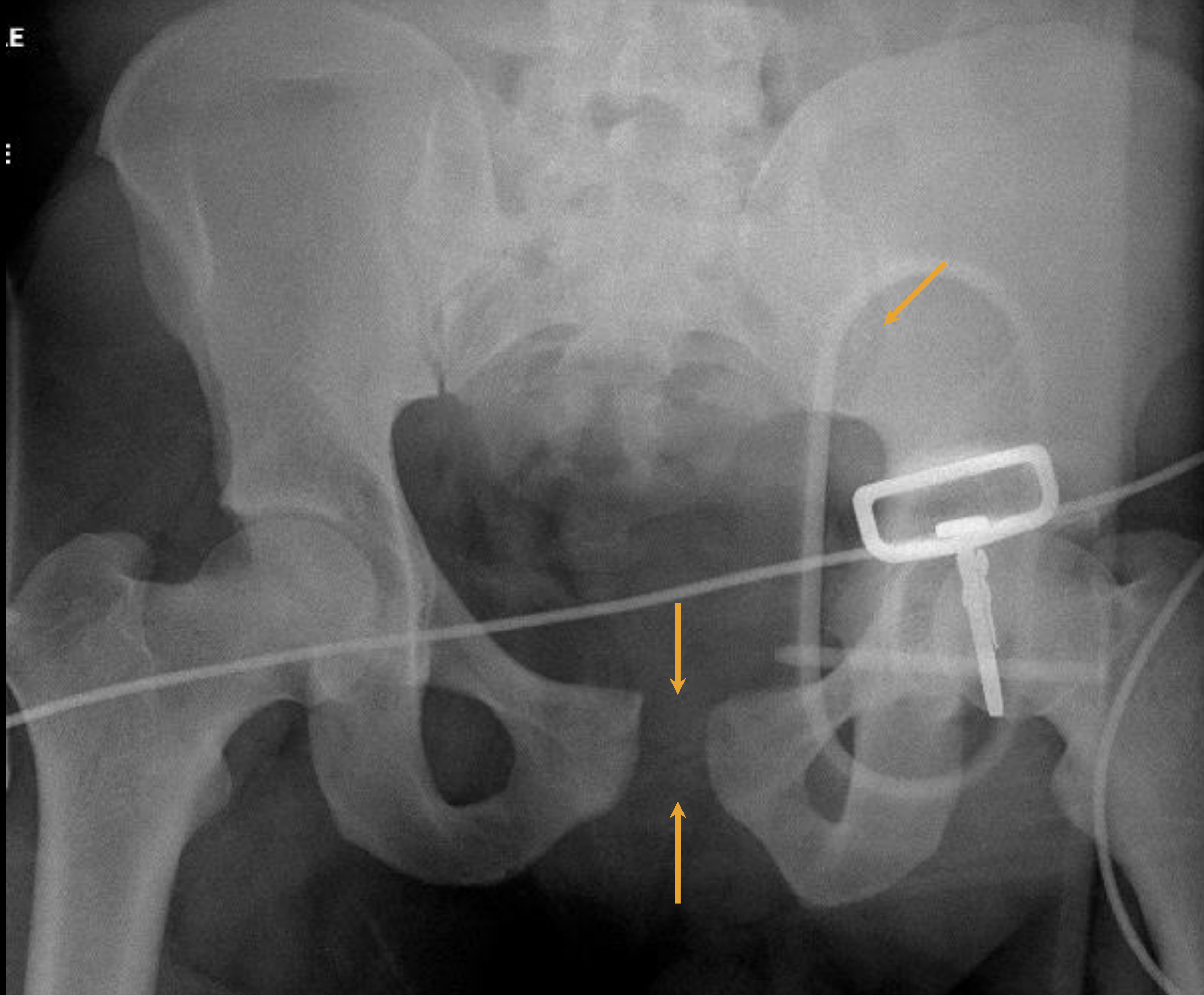
SPR Fx on Hip CT



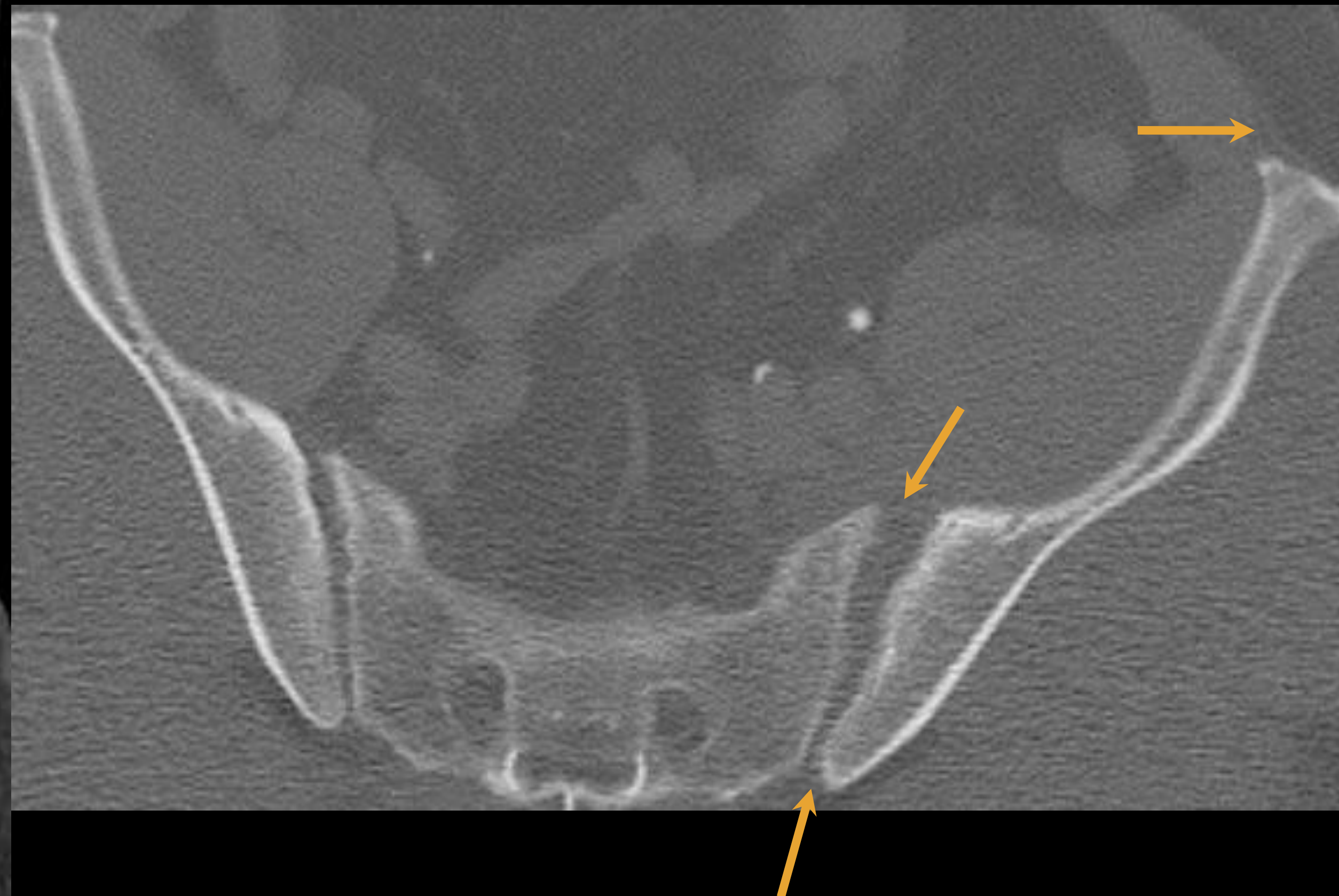
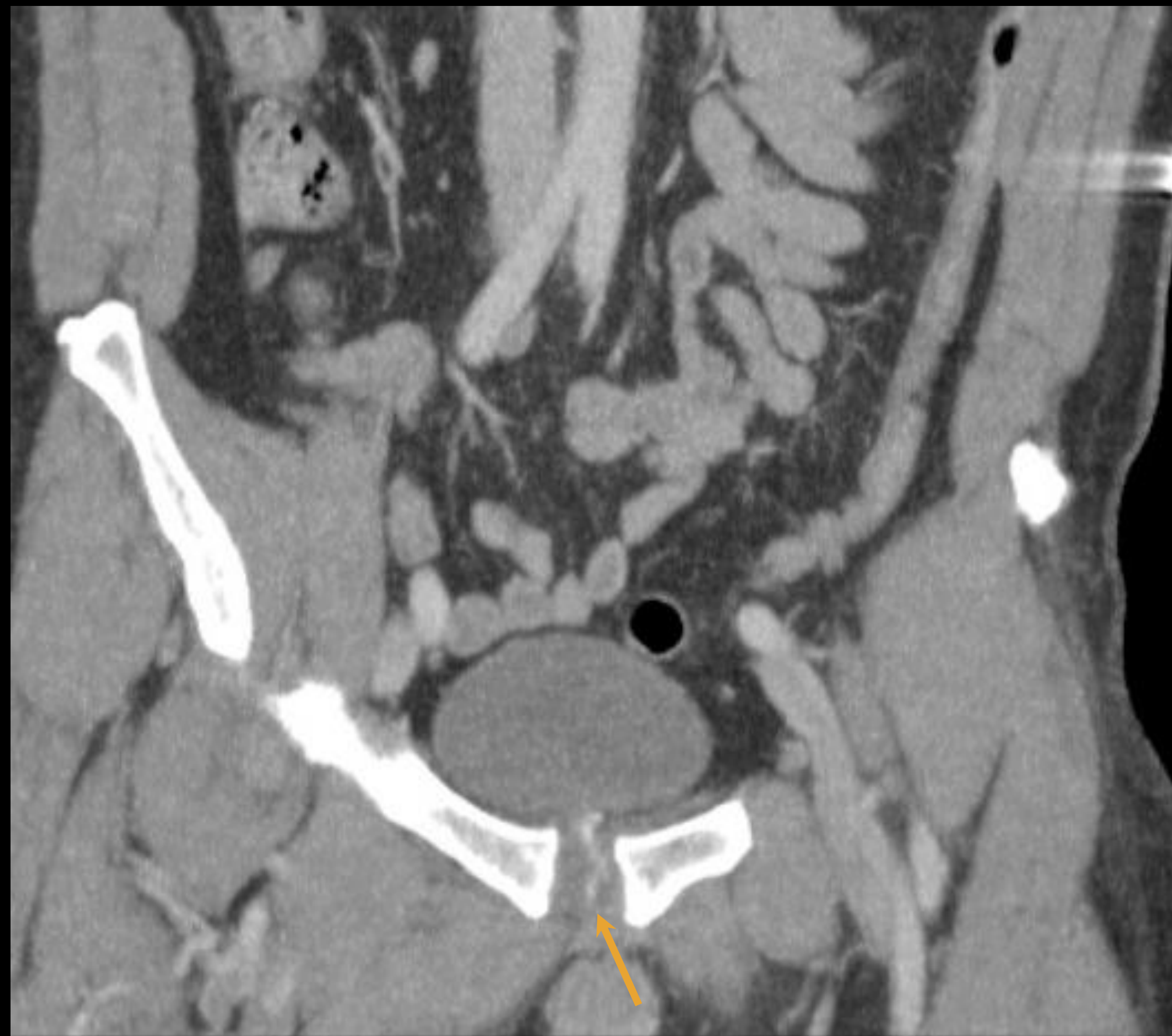

**Anterior and
posterior
compression**

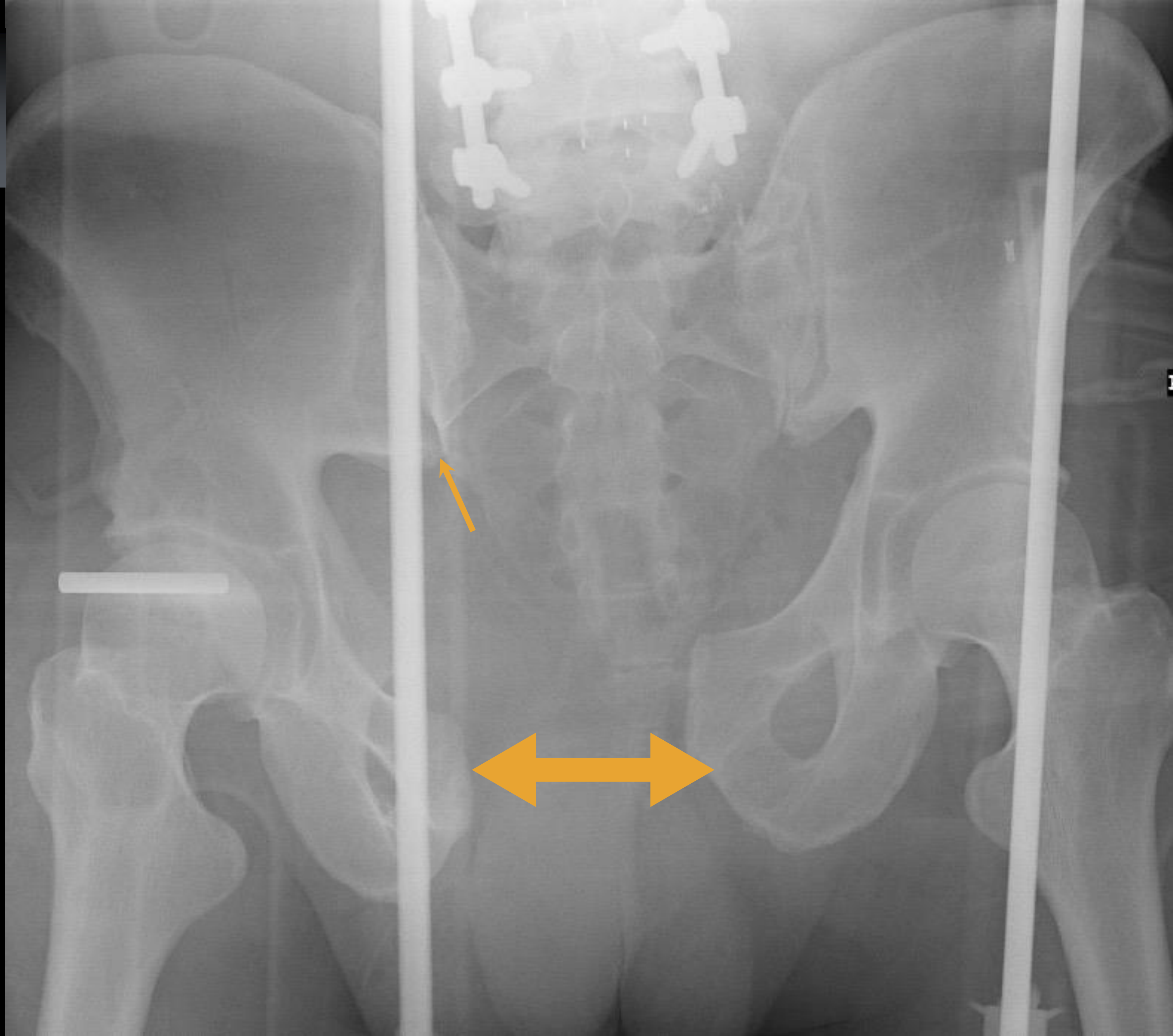
APC 2



APC 2

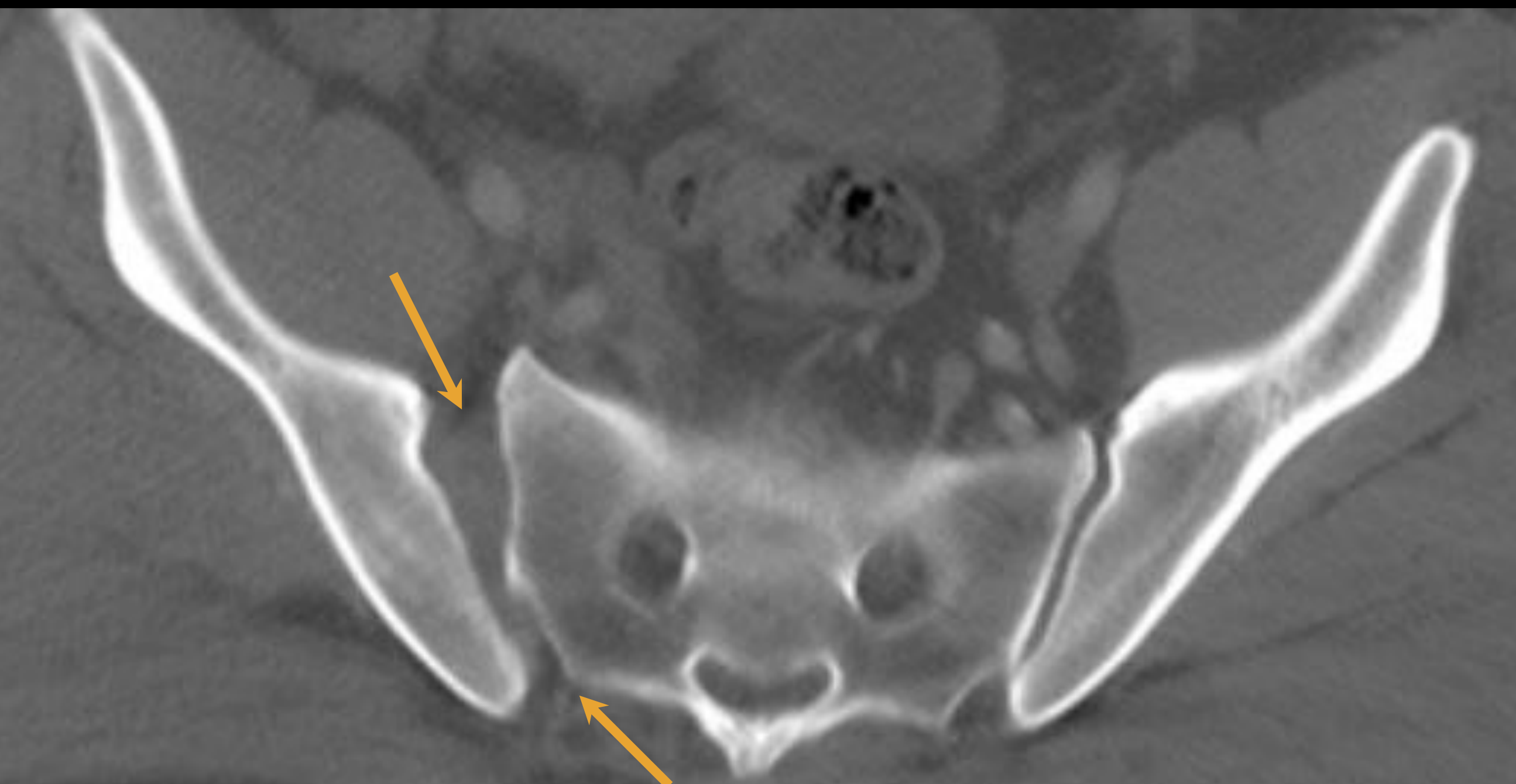
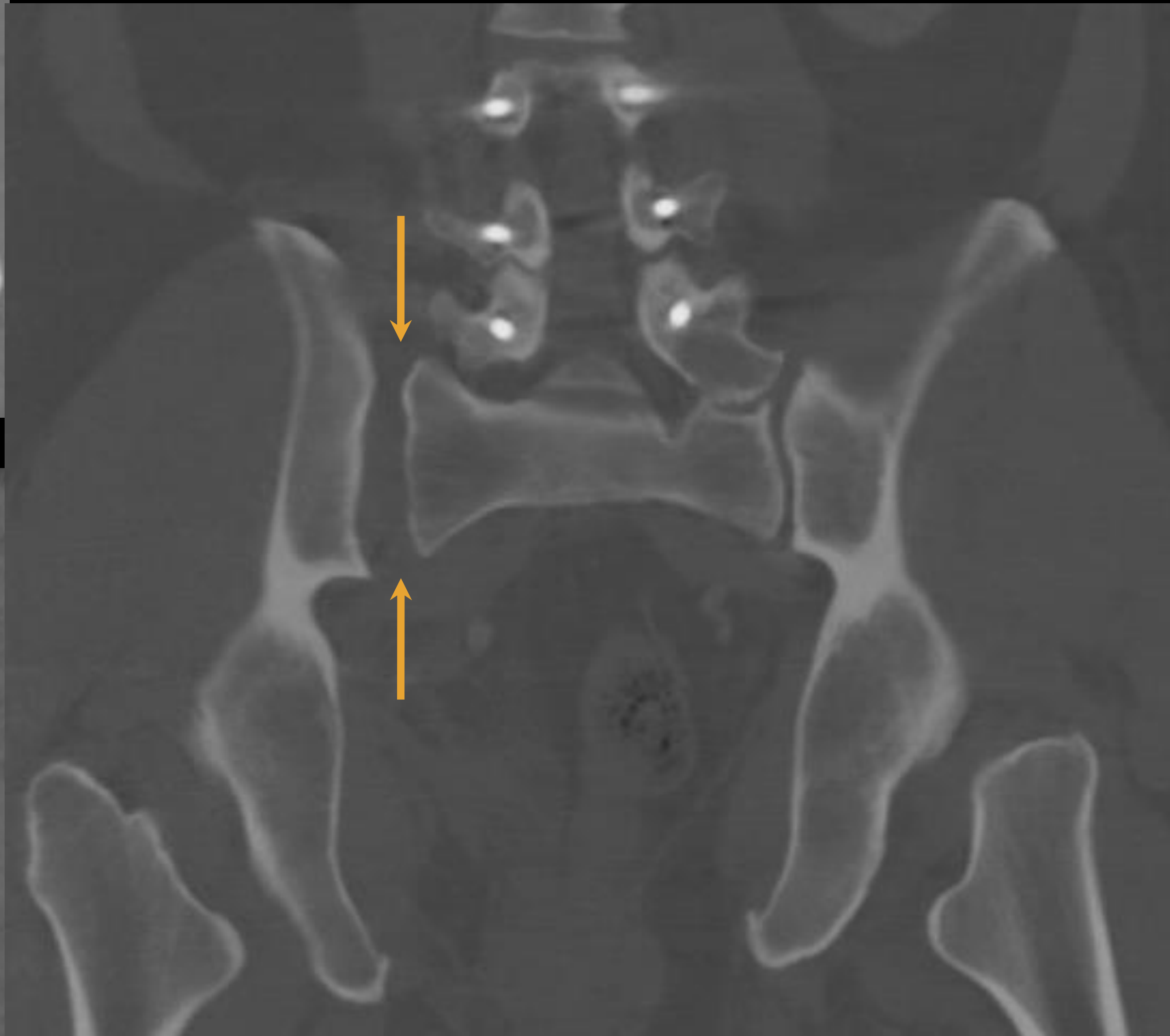
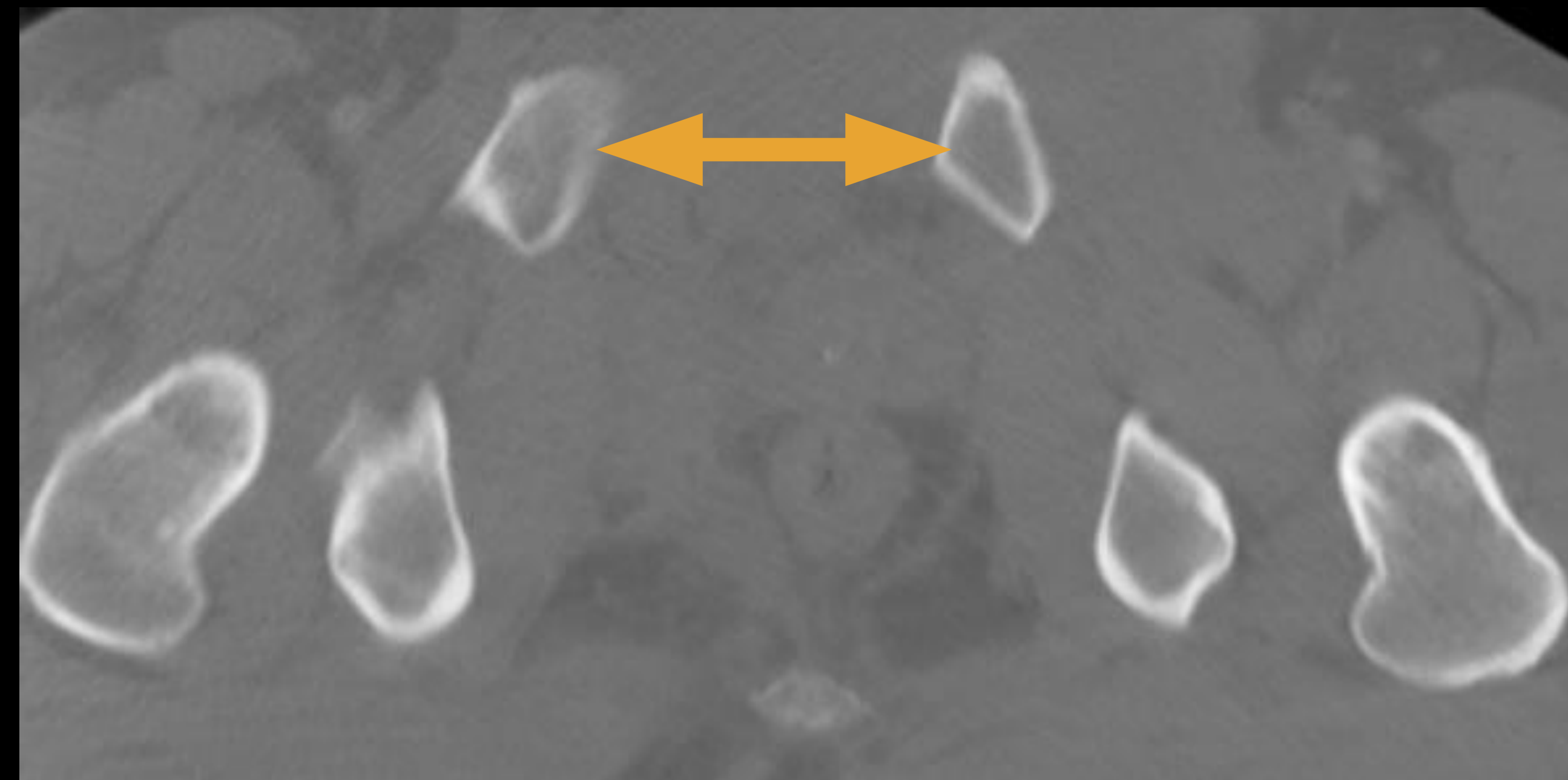APC 2

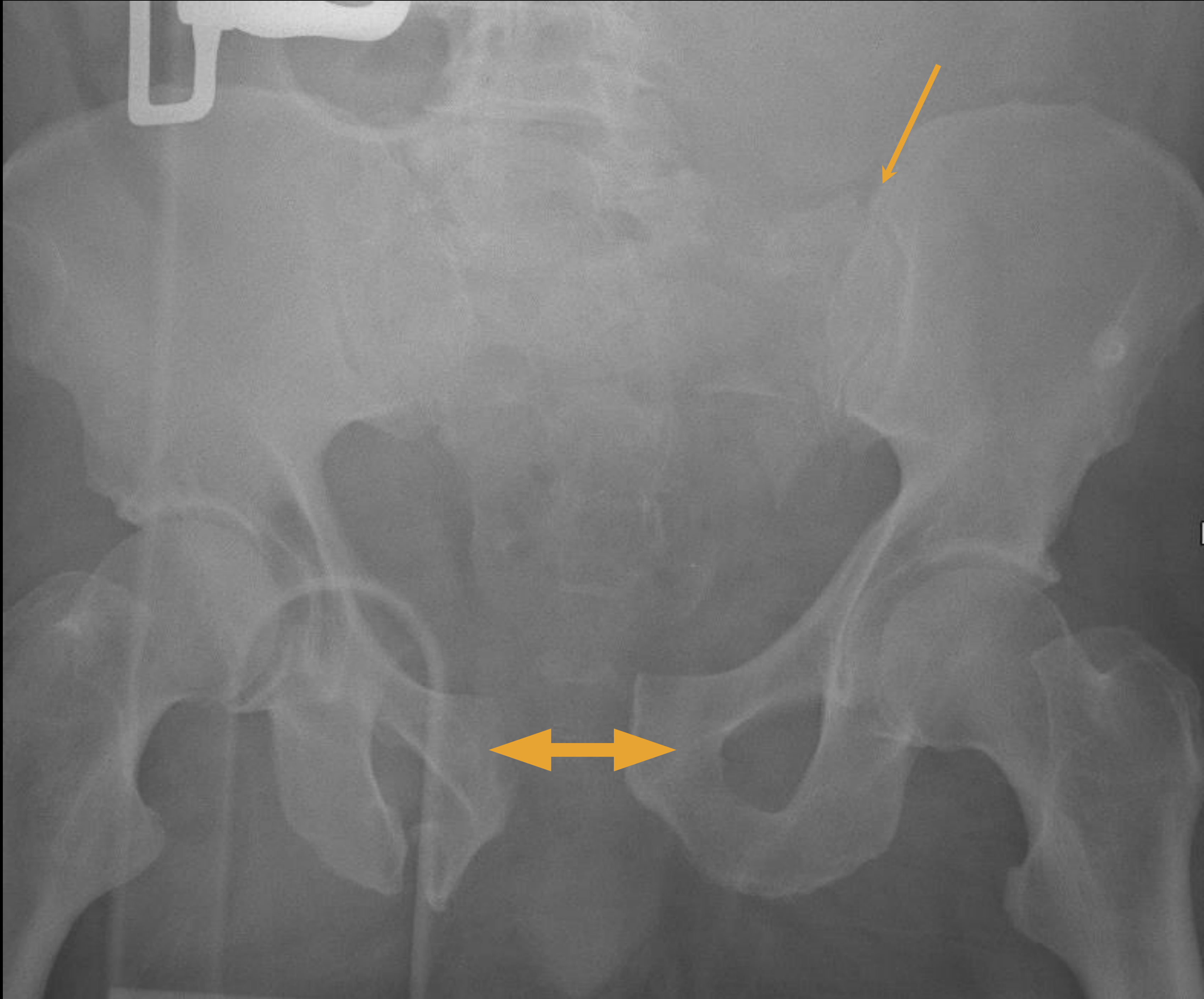


AP

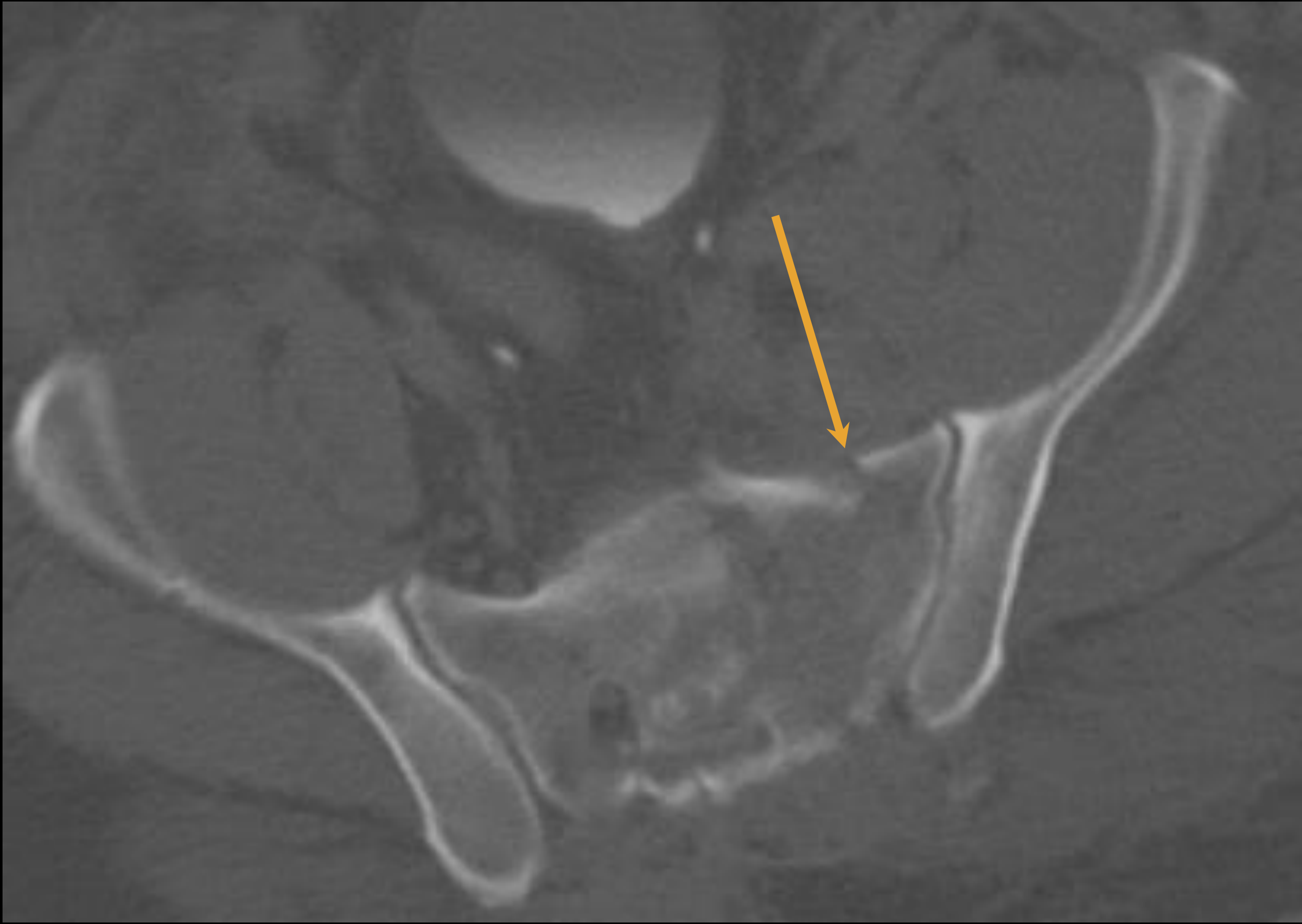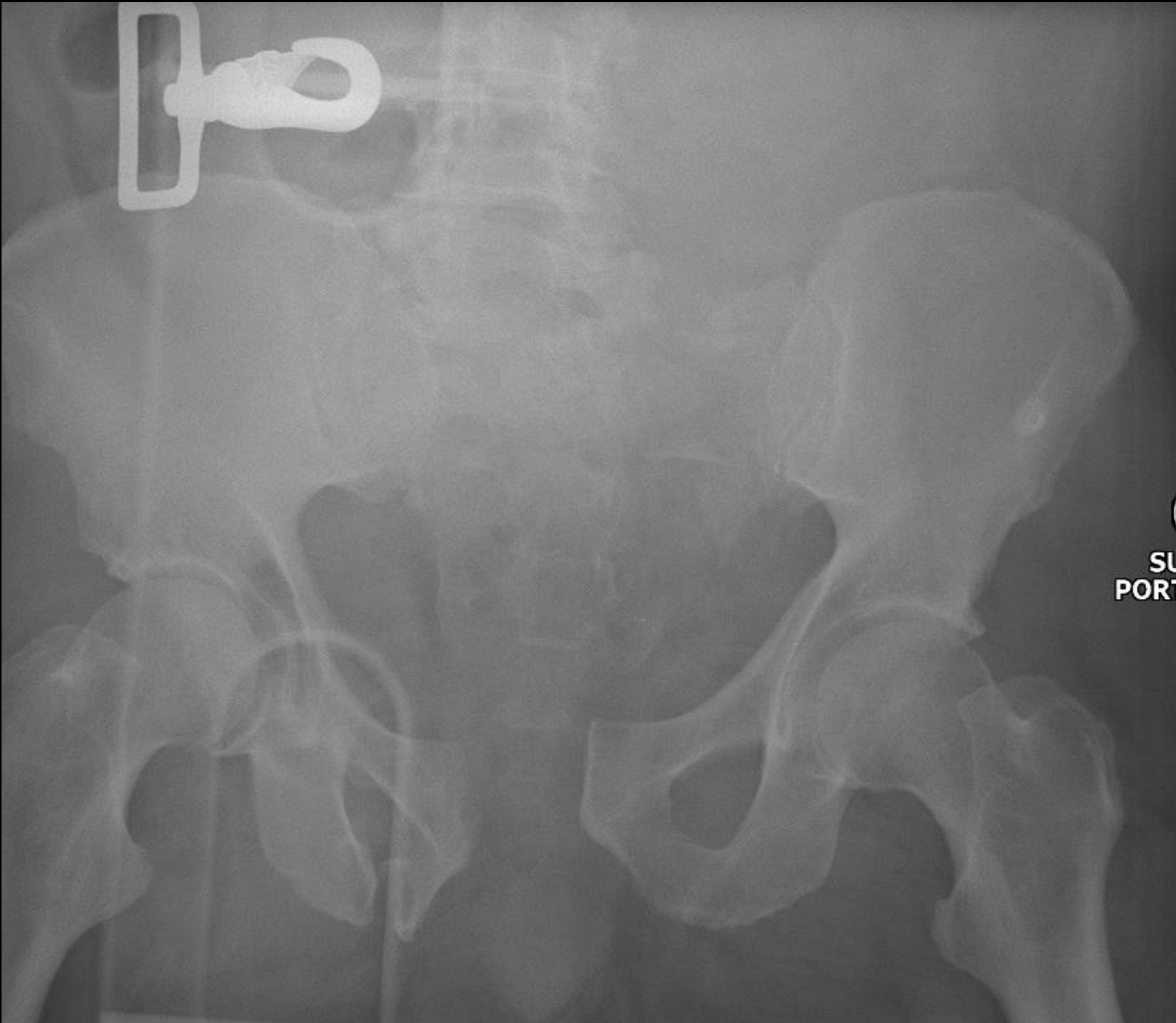APC 3

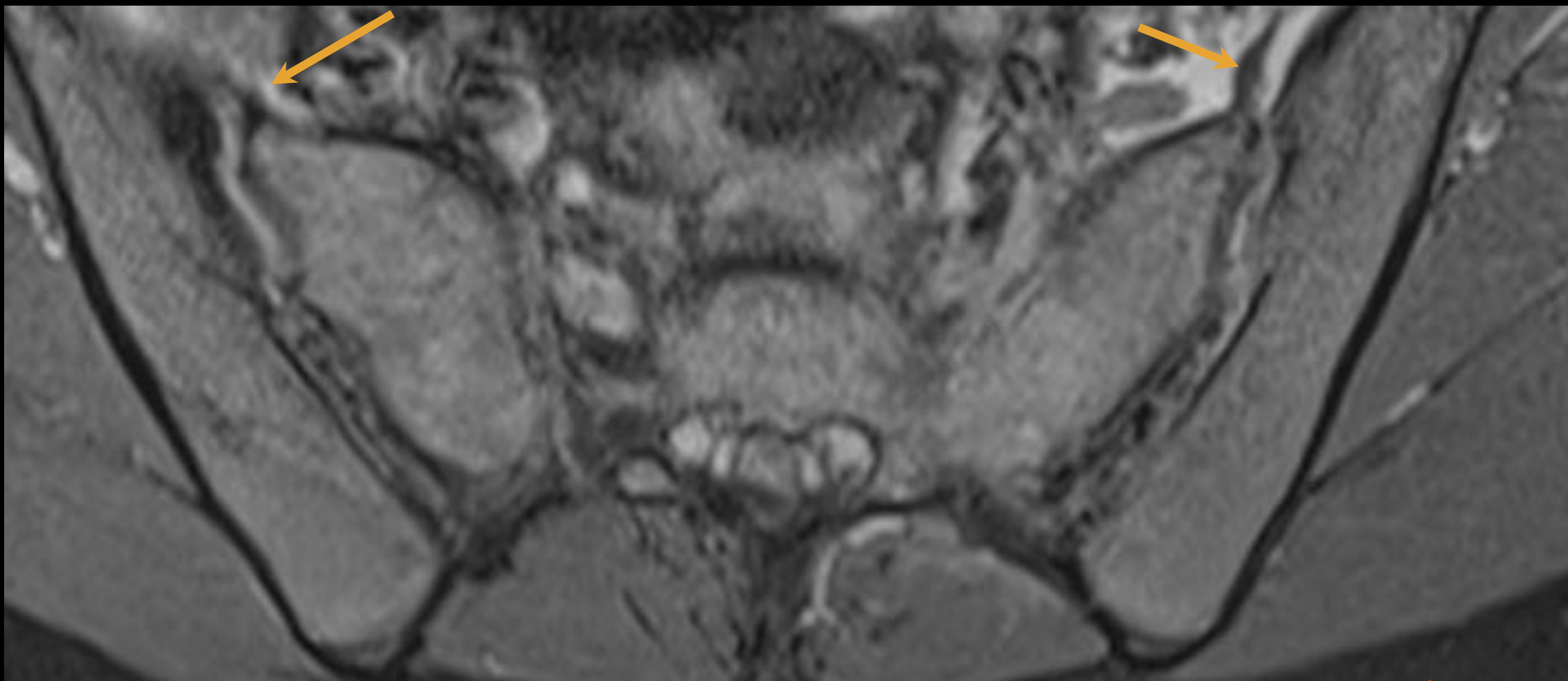


? APC



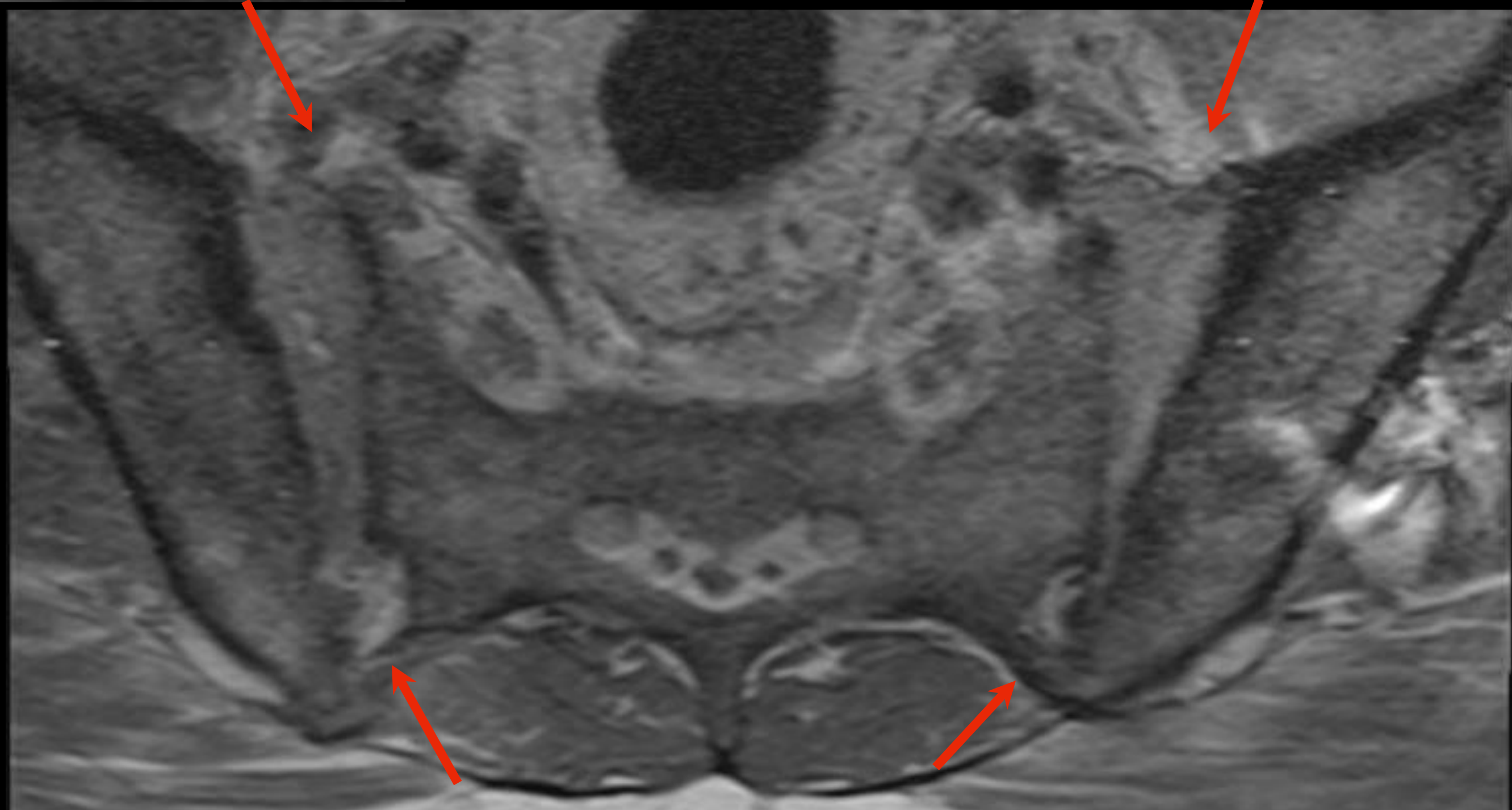
APC 2





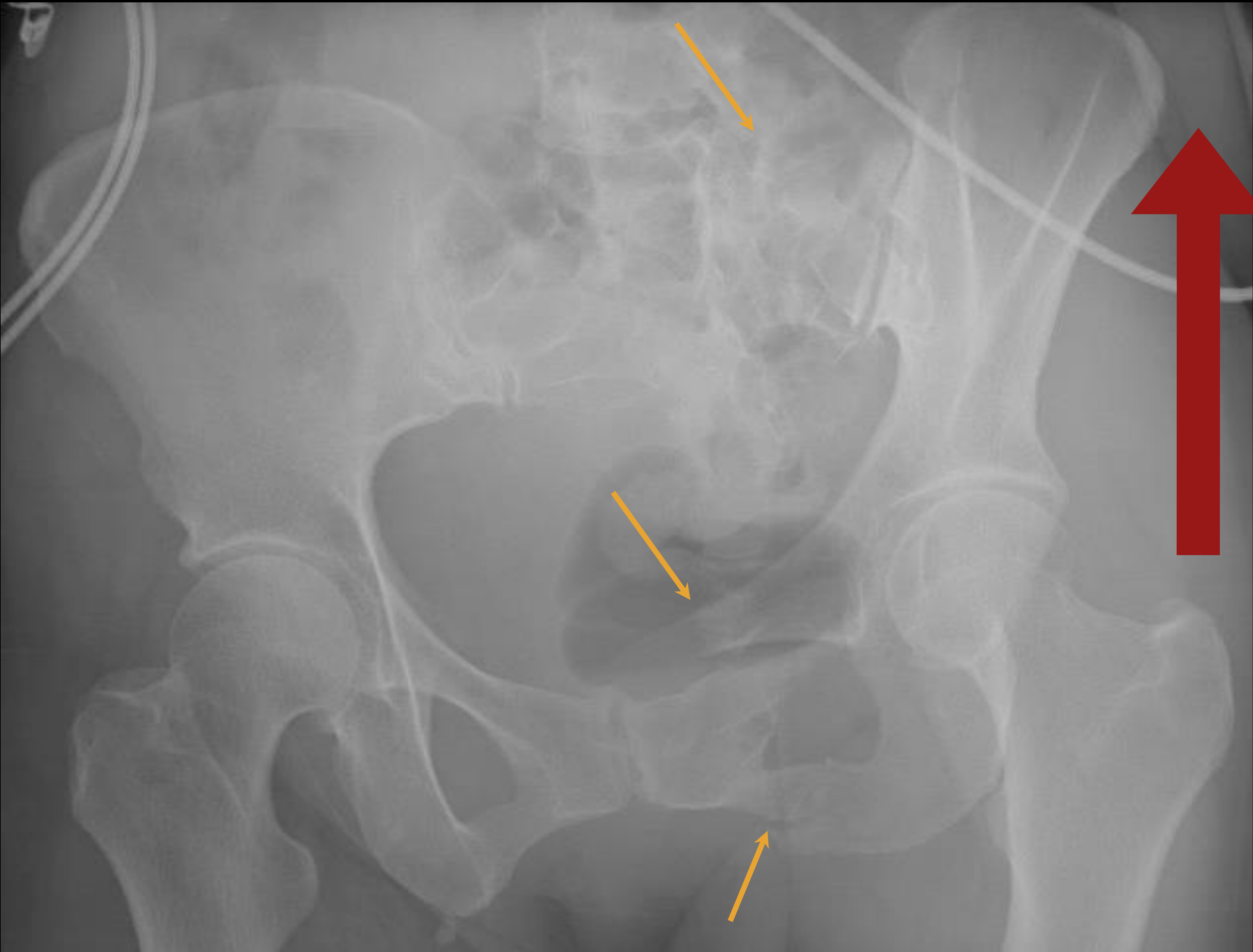
APC 2

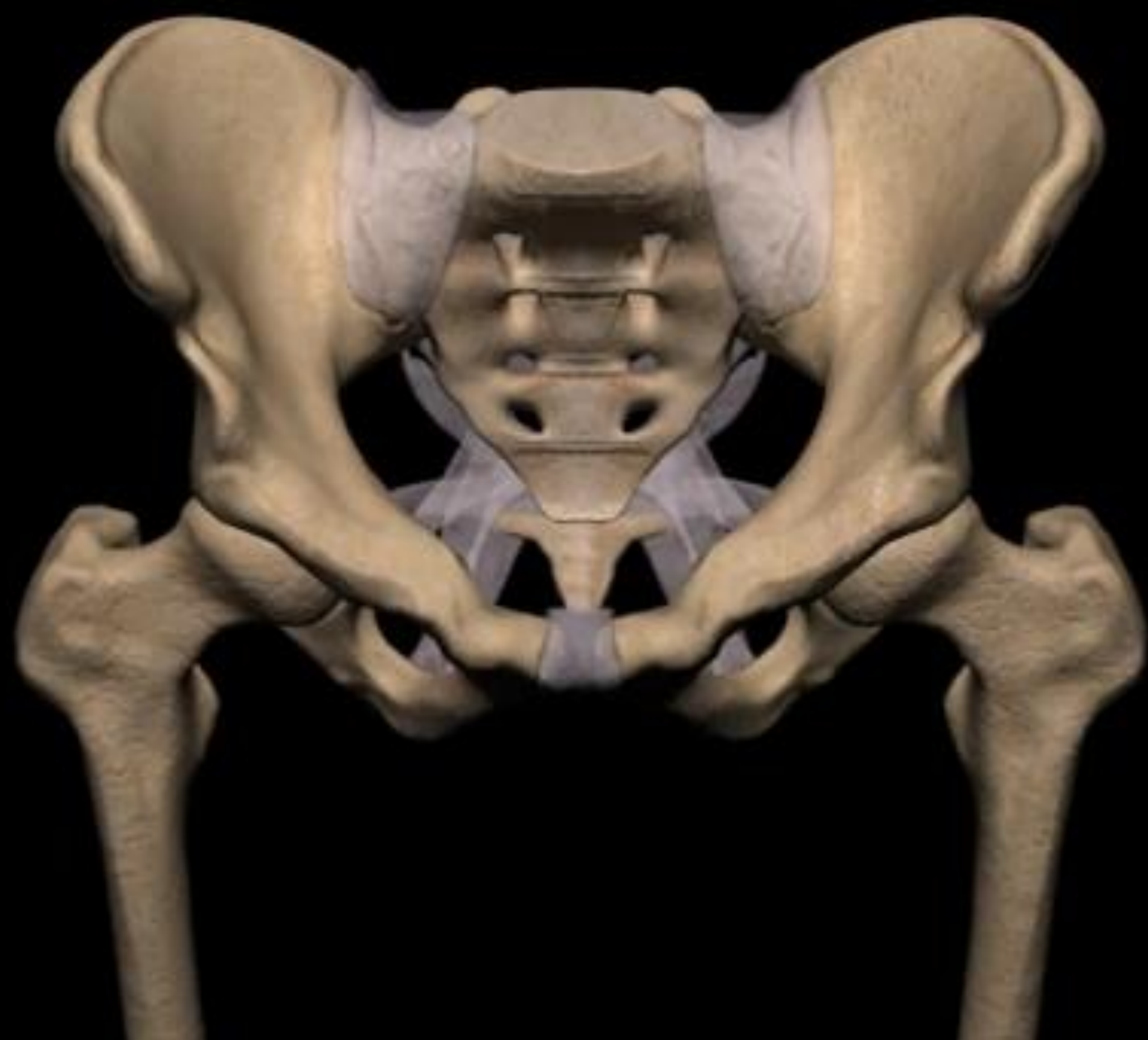APC 3



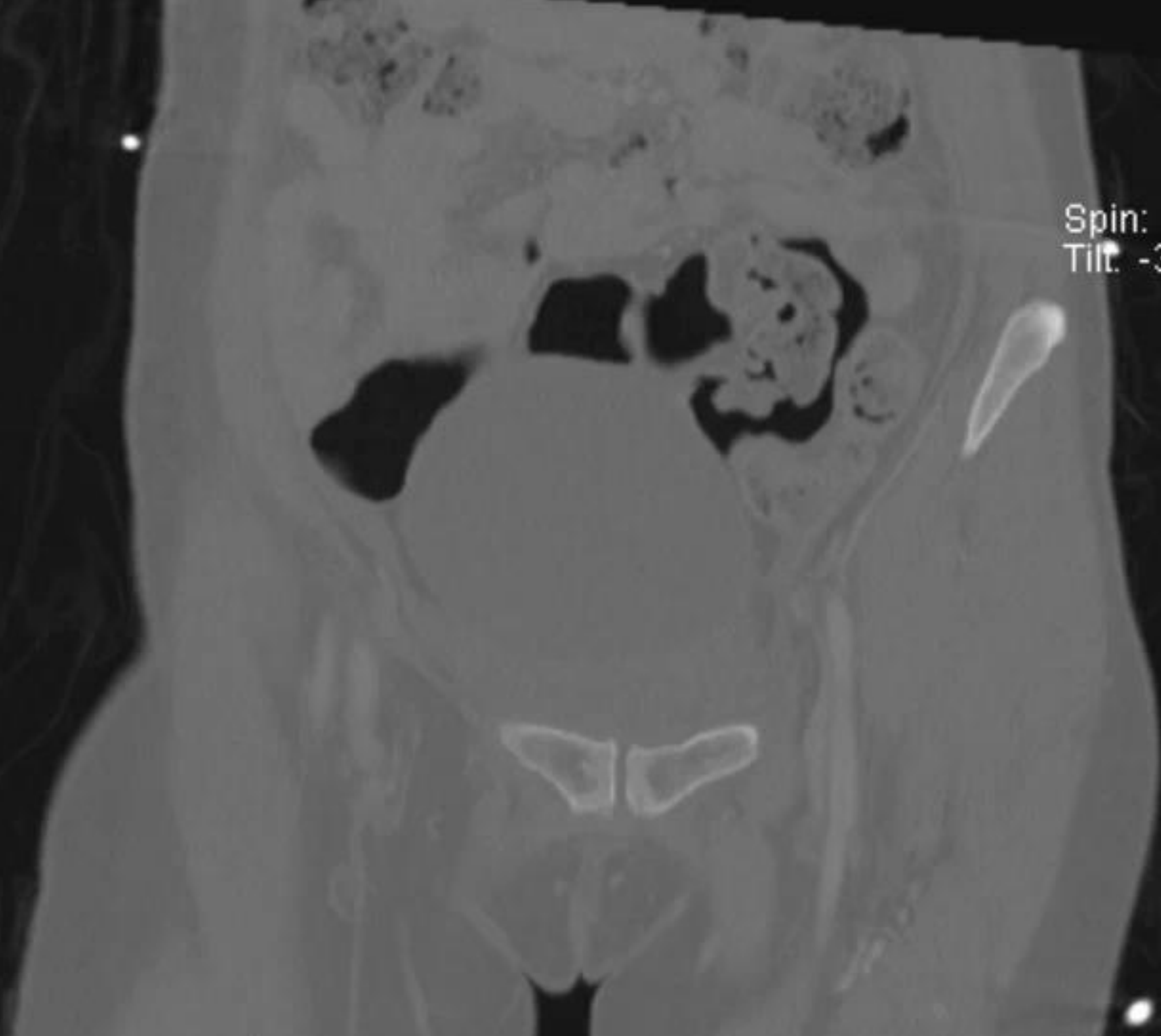AP compression injury

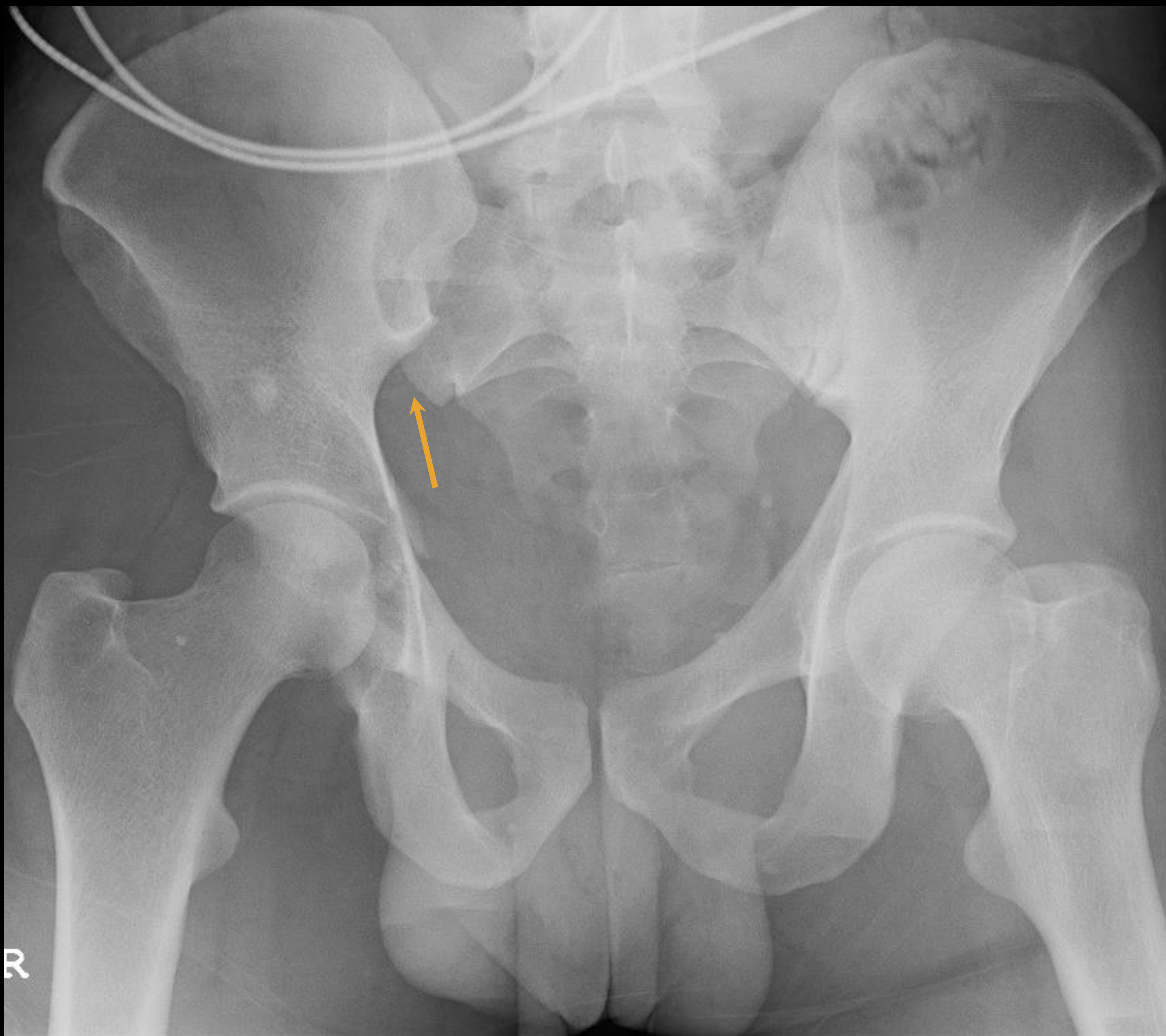
- PUBIC SYMPHYSIS WIDENING/Fx
 - APC1: Widening of pubic symphysis (> 2cm)
 - APC2: Widening of anterior SI
 - APC3: Complete diastasis of SI





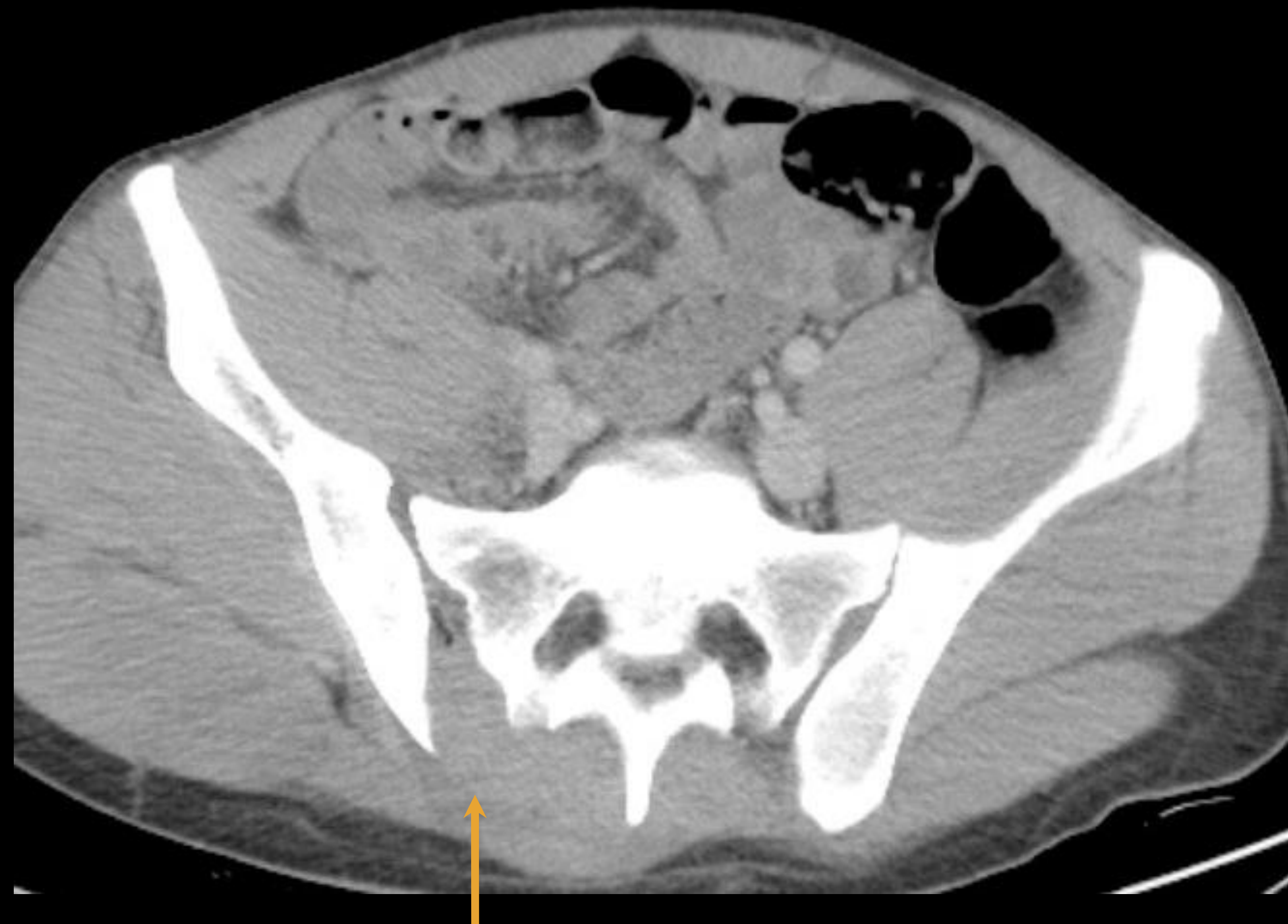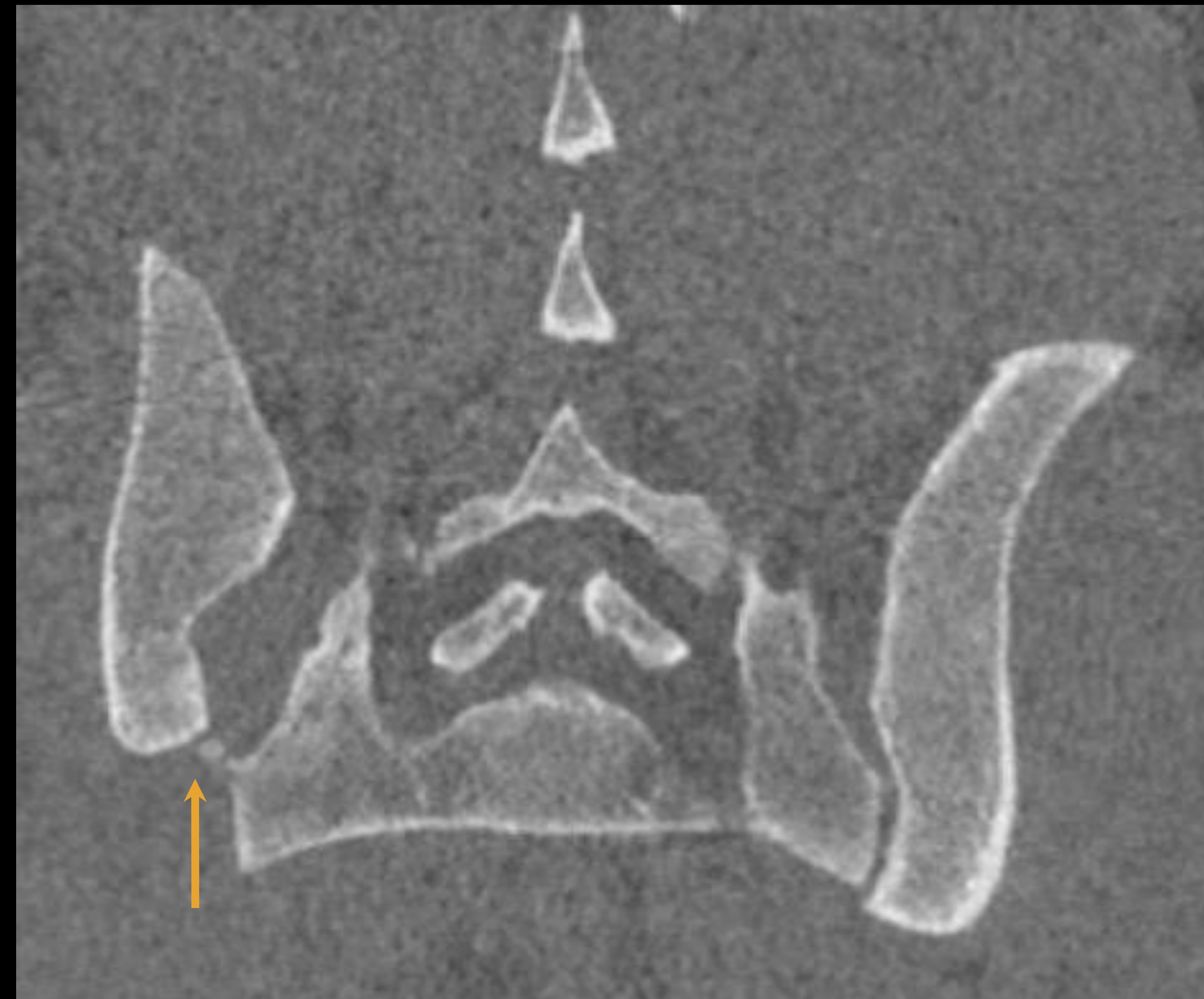Spin: 9
Tilt: -3

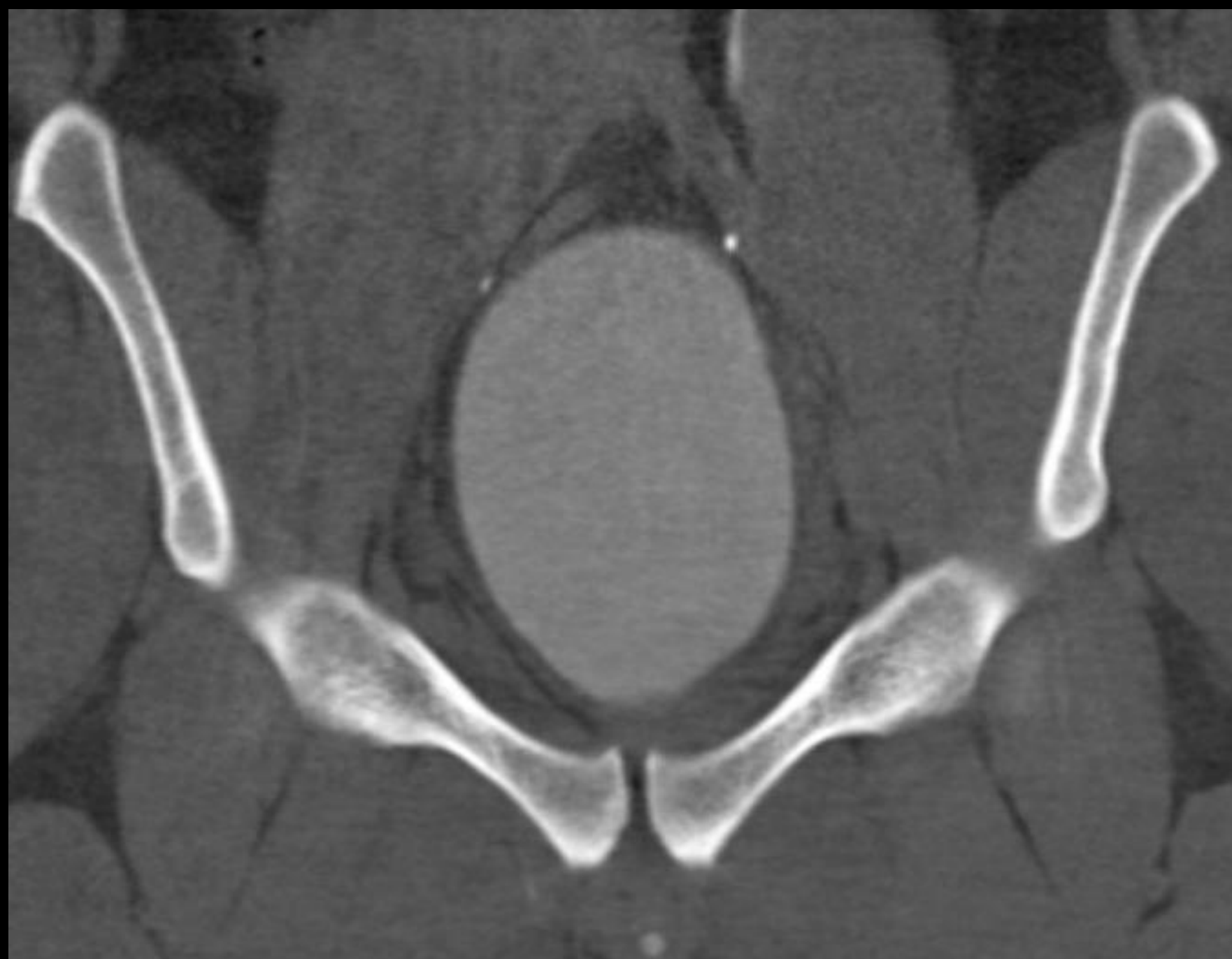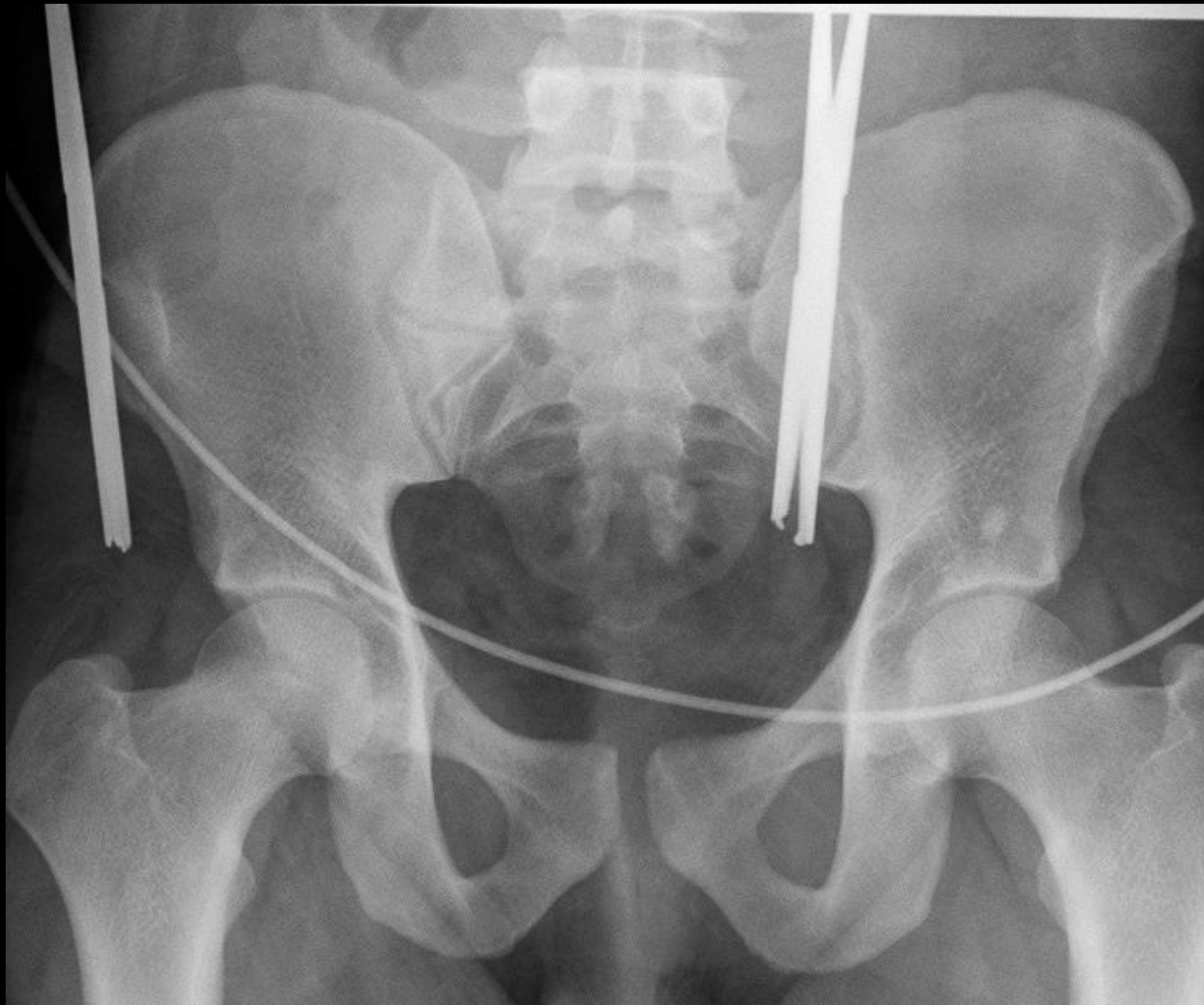
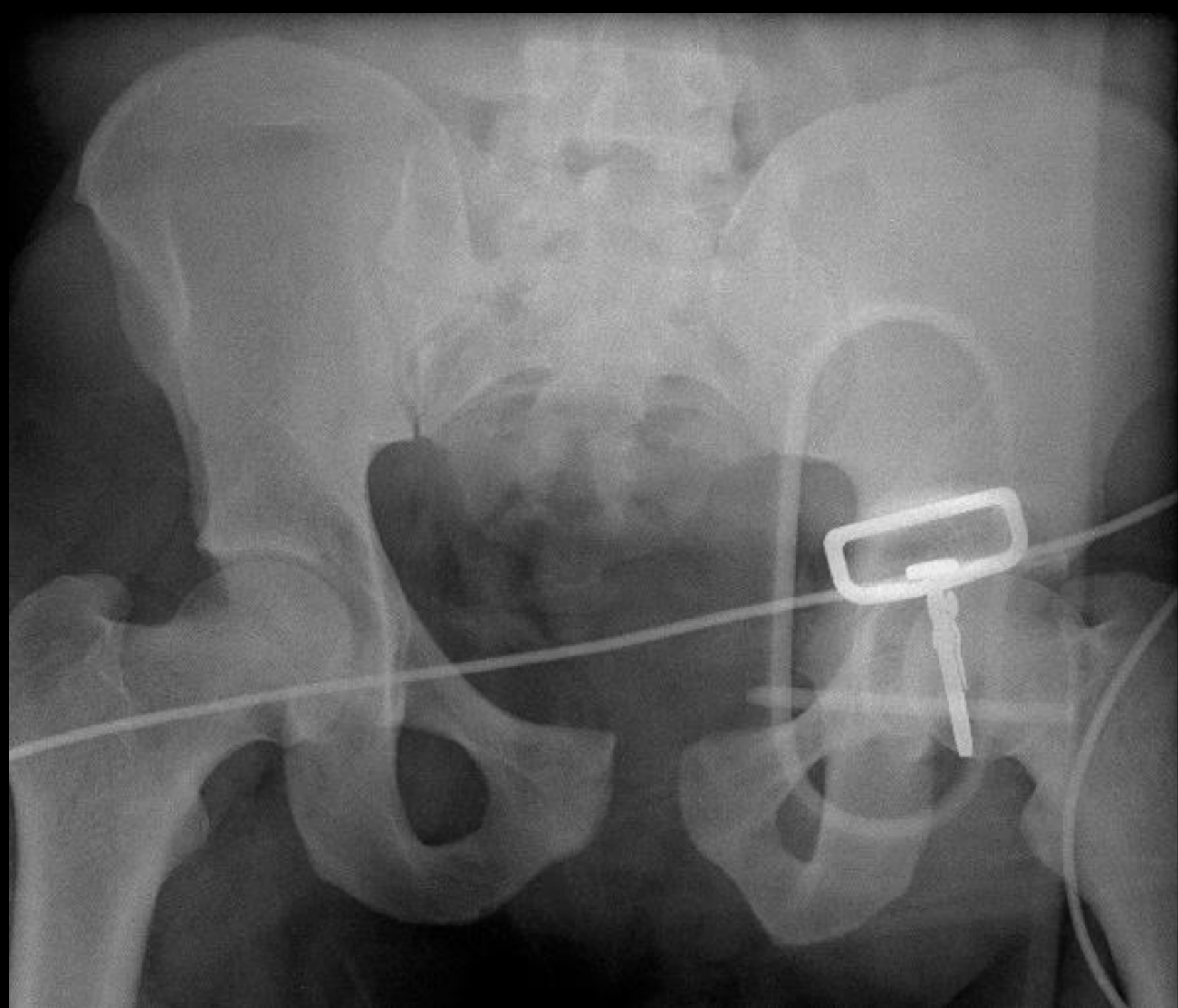




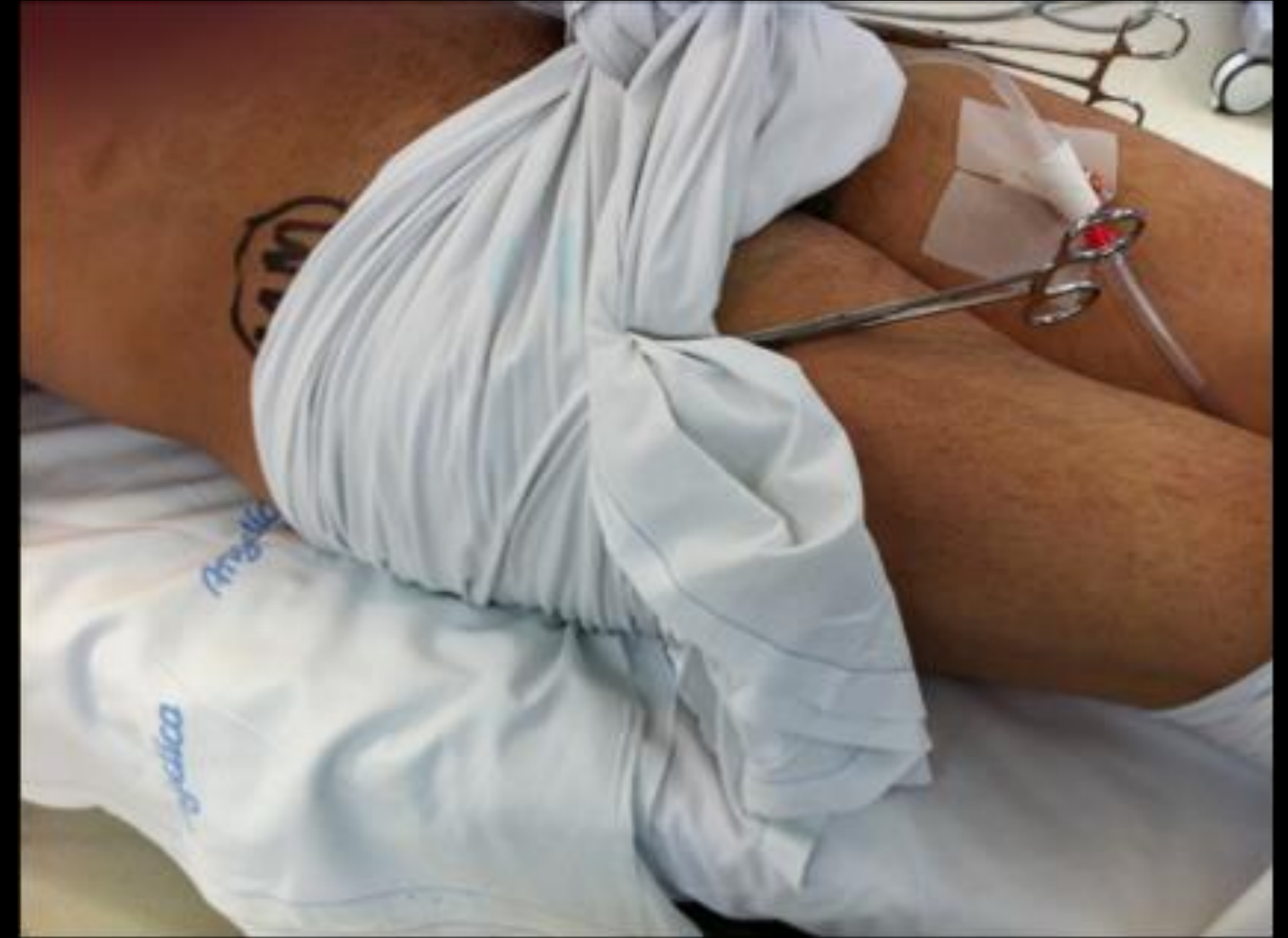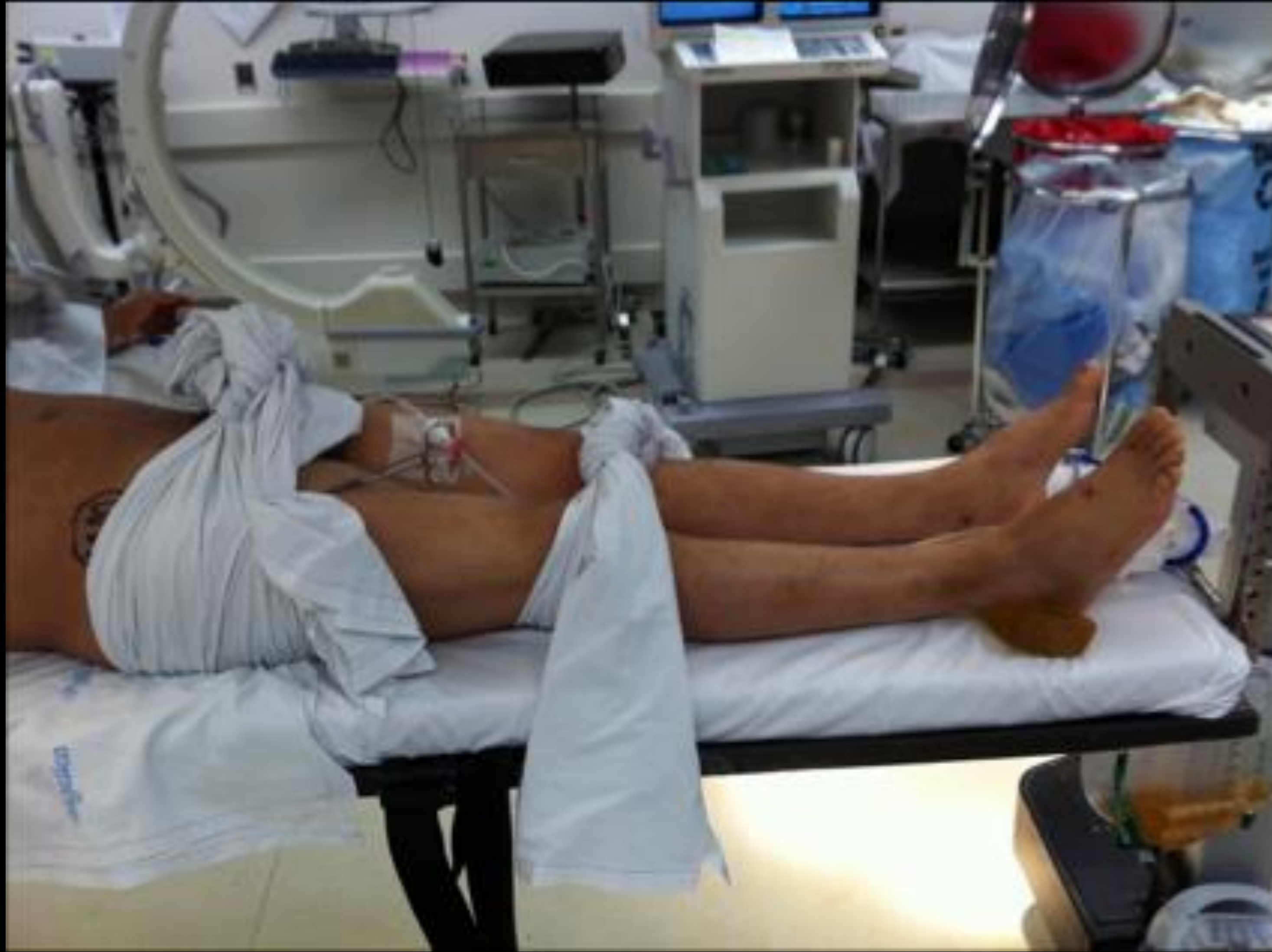**Vertical
Shear**

Vertical Shear



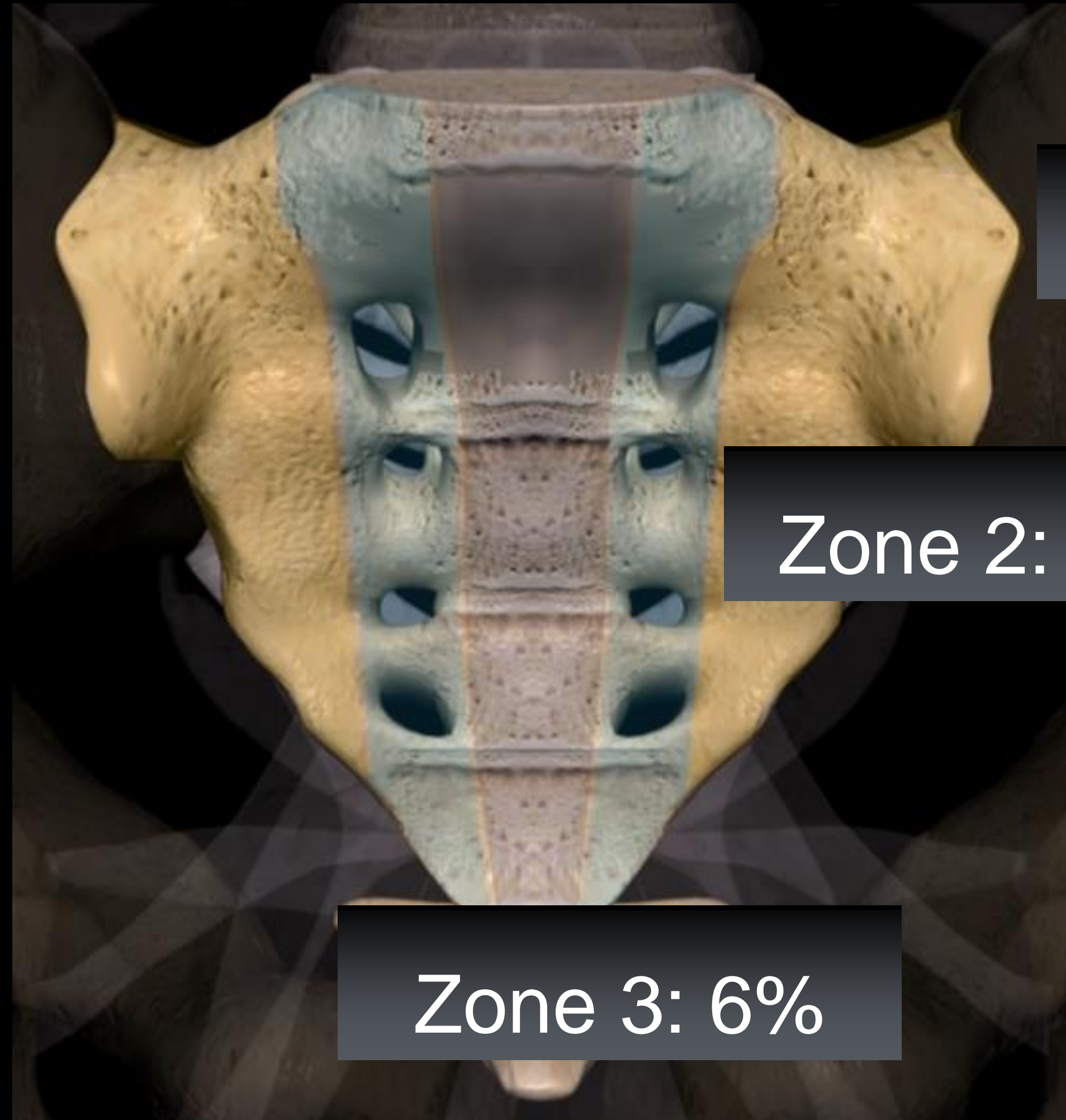






	Anterior ring injury	Posterior ring injury
LC I	Pubic rami fx	Ipsilateral sacral compression
LC II	Pubic rami fx	Ipsilateral iliac crest (crescent) fracture, or posterior SI ligament injury with SI widening
LC III	Pubic rami fx	Contralateral APC injury (windswept pelvis)
APC I	Pubic symphysis diastasis (<2 cm)	Minimal SI joint widening, but intact SI ligaments
APC II	Pubic rami fx or symphysis diastasis	Anterior SI joint widening, anterior SI ligament disruption
APC III	Pubic rami fx or symphysis diastasis	Complete SI ligament disruption, SI joint widening, but no vertical displacement
VS	Pubic rami fx or symphysis	Vertical displacement with SI ligament disruption

Sacral Fractures

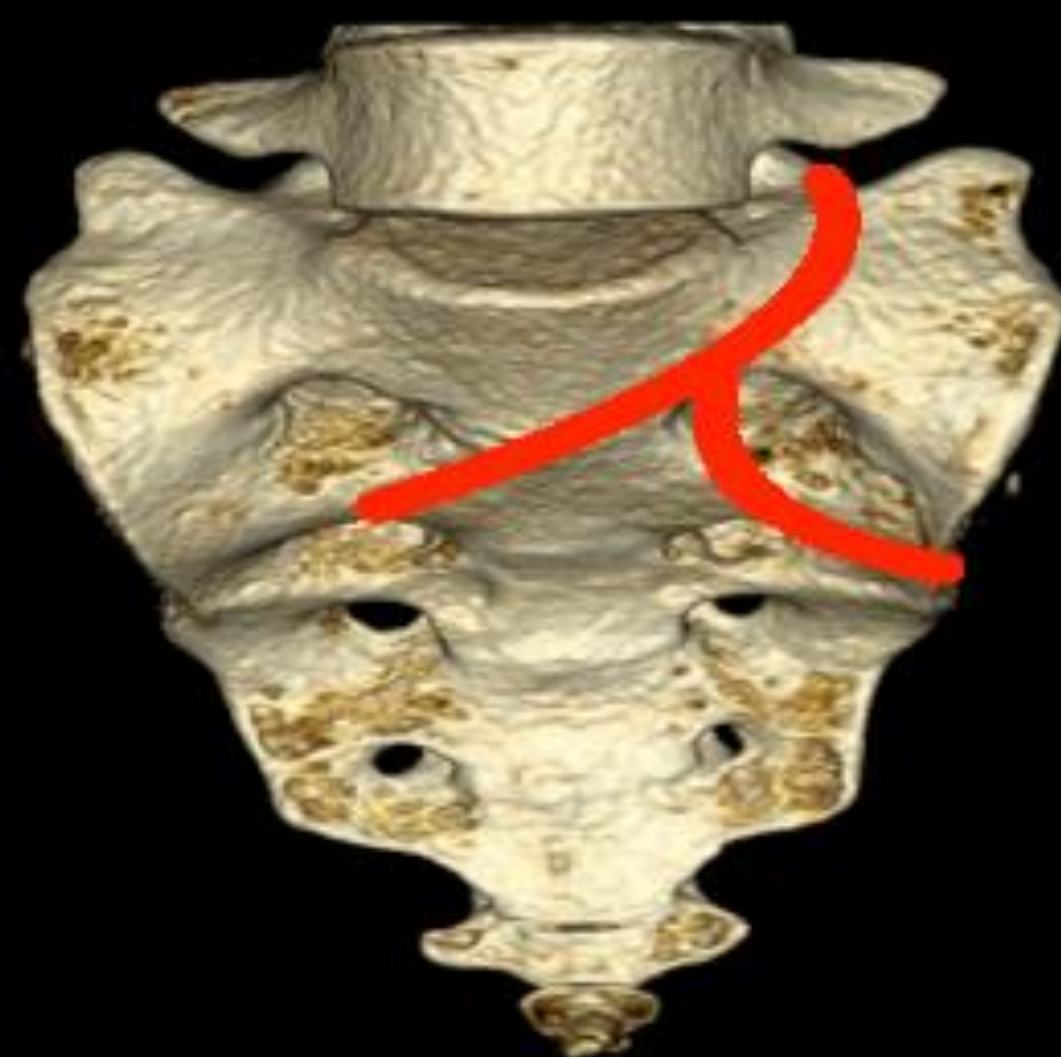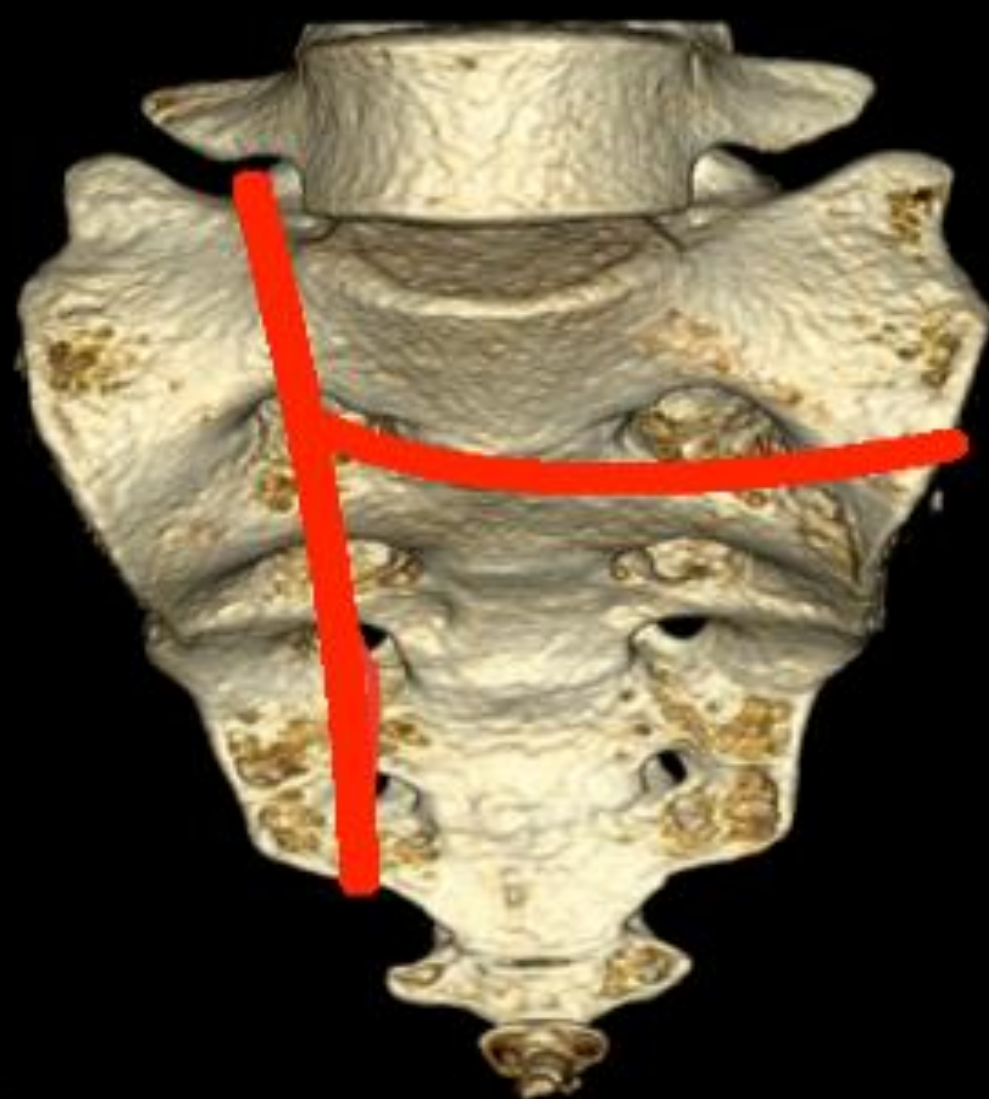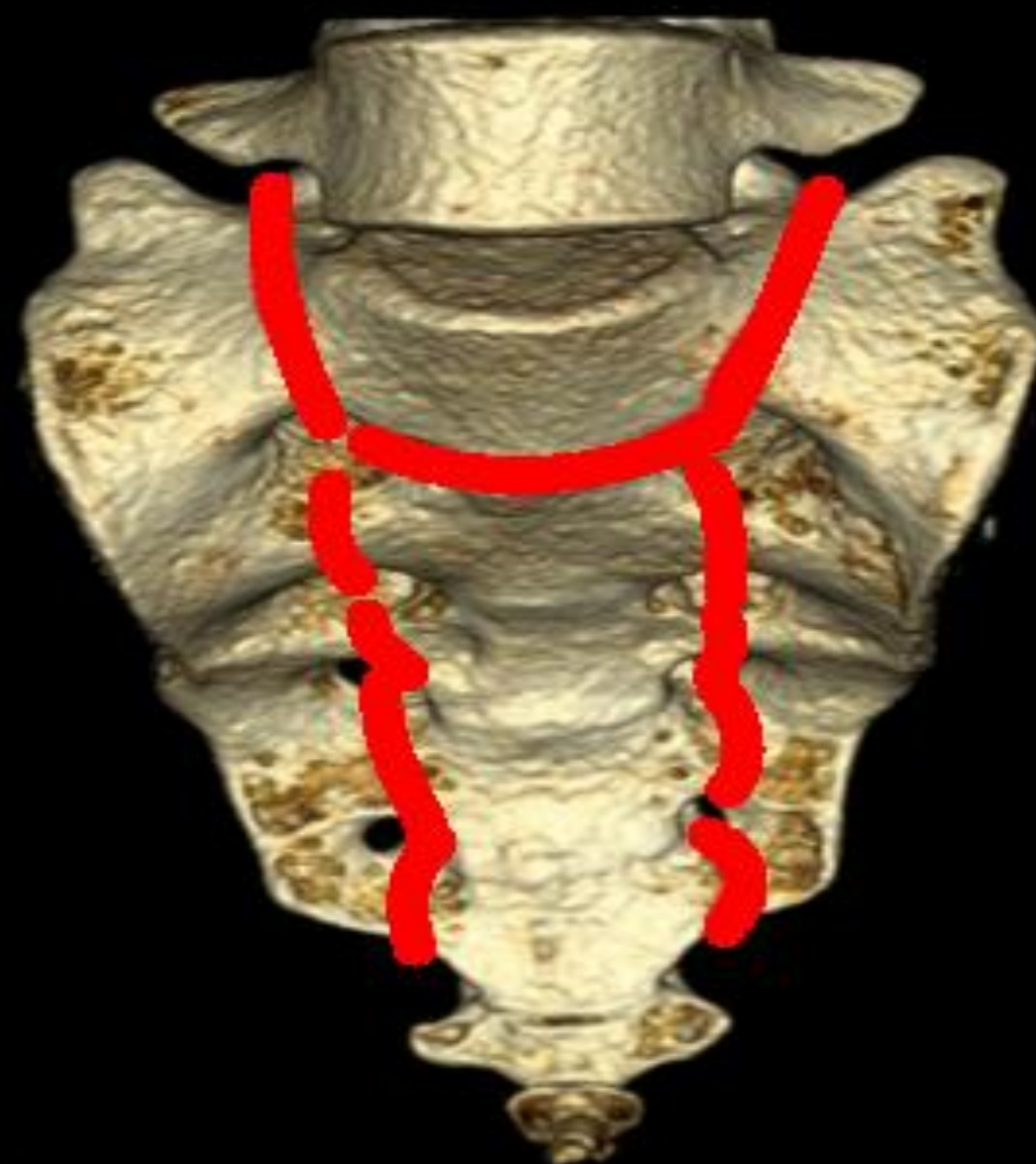
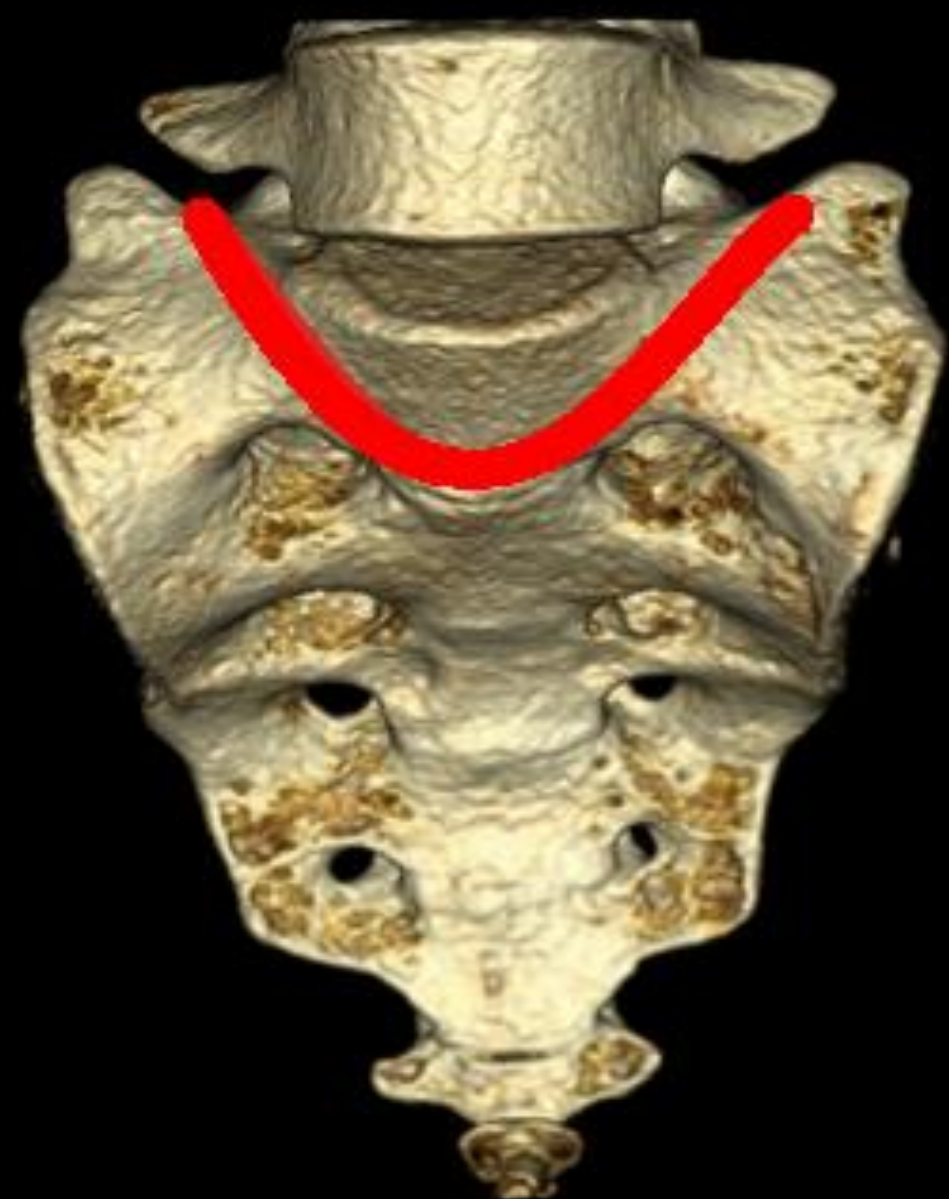


Zone 1: 50%

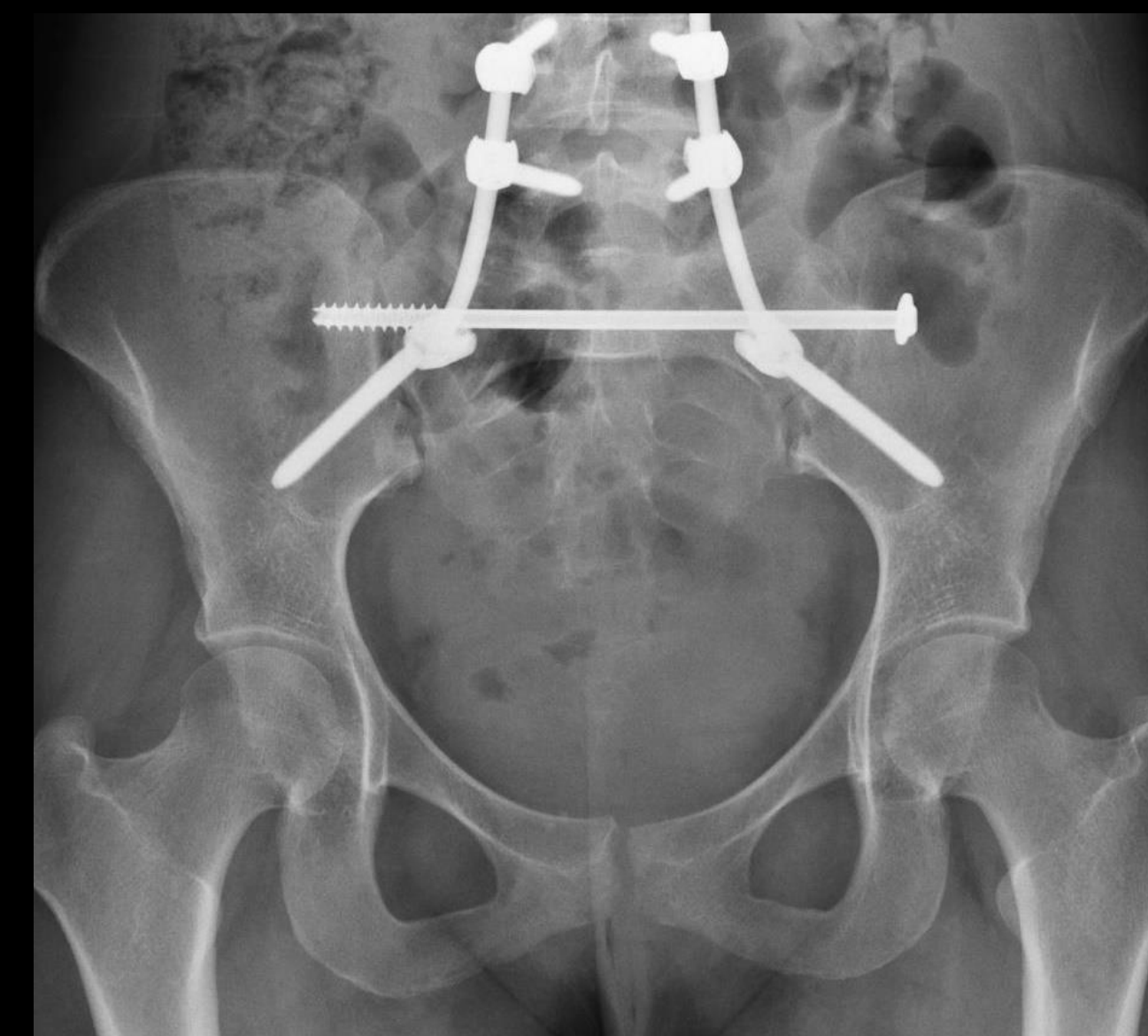
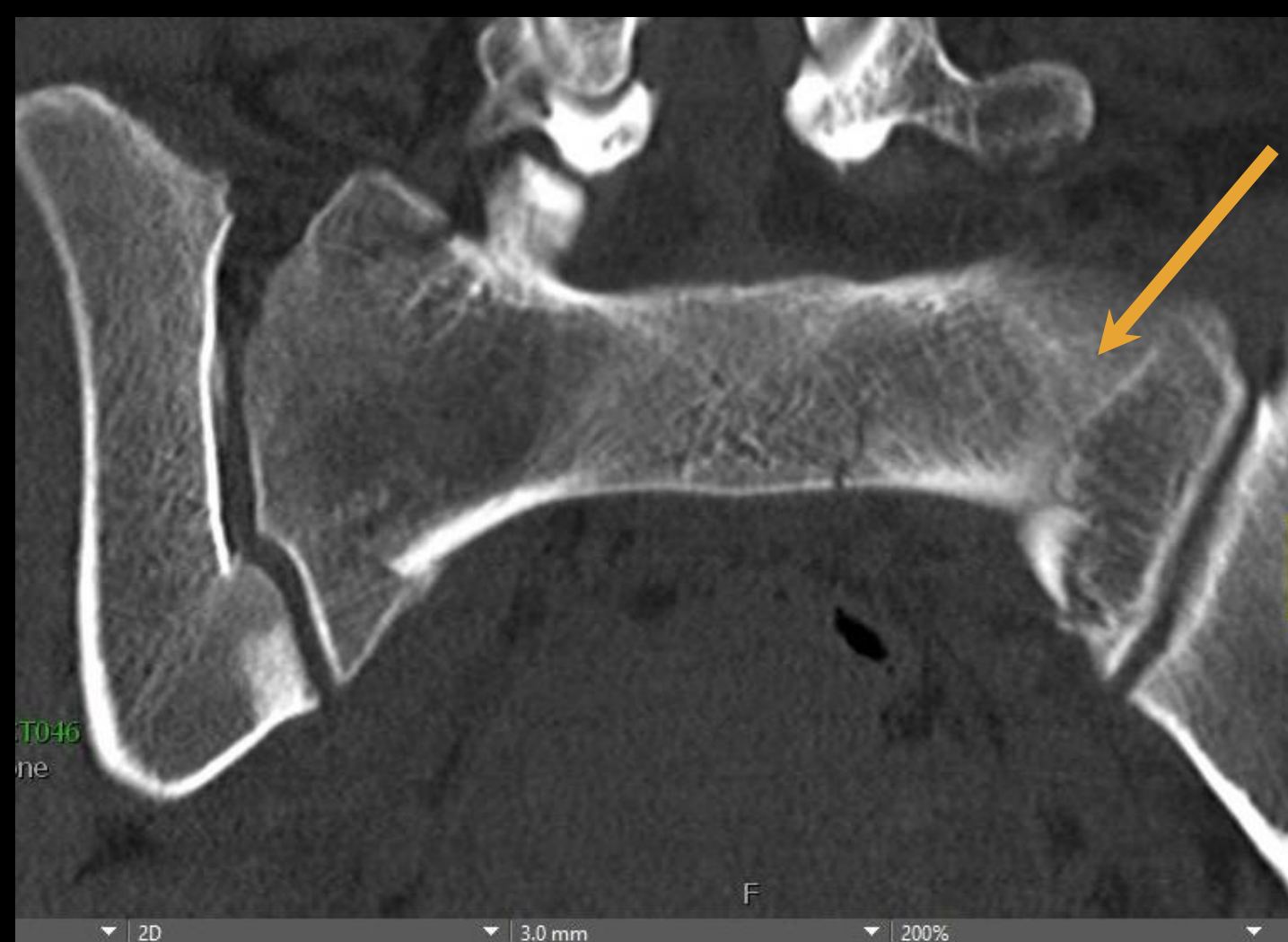
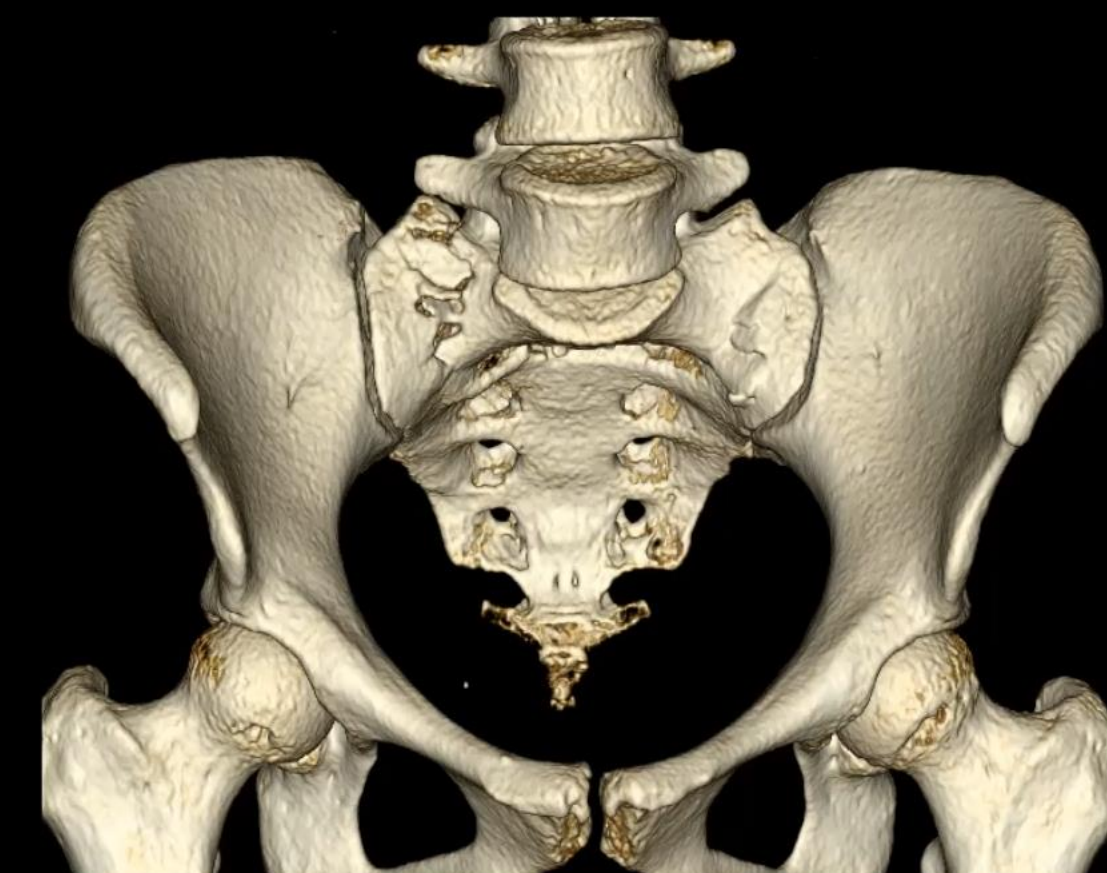
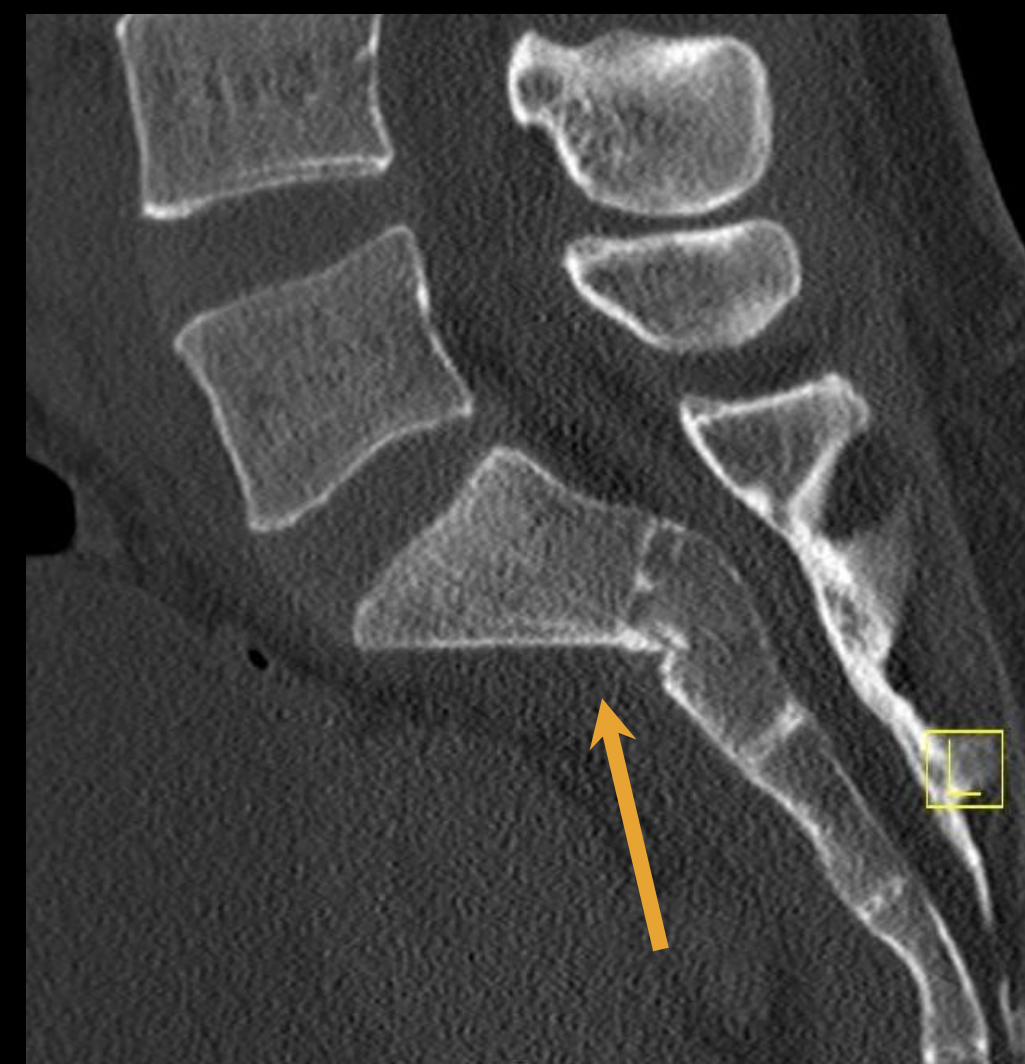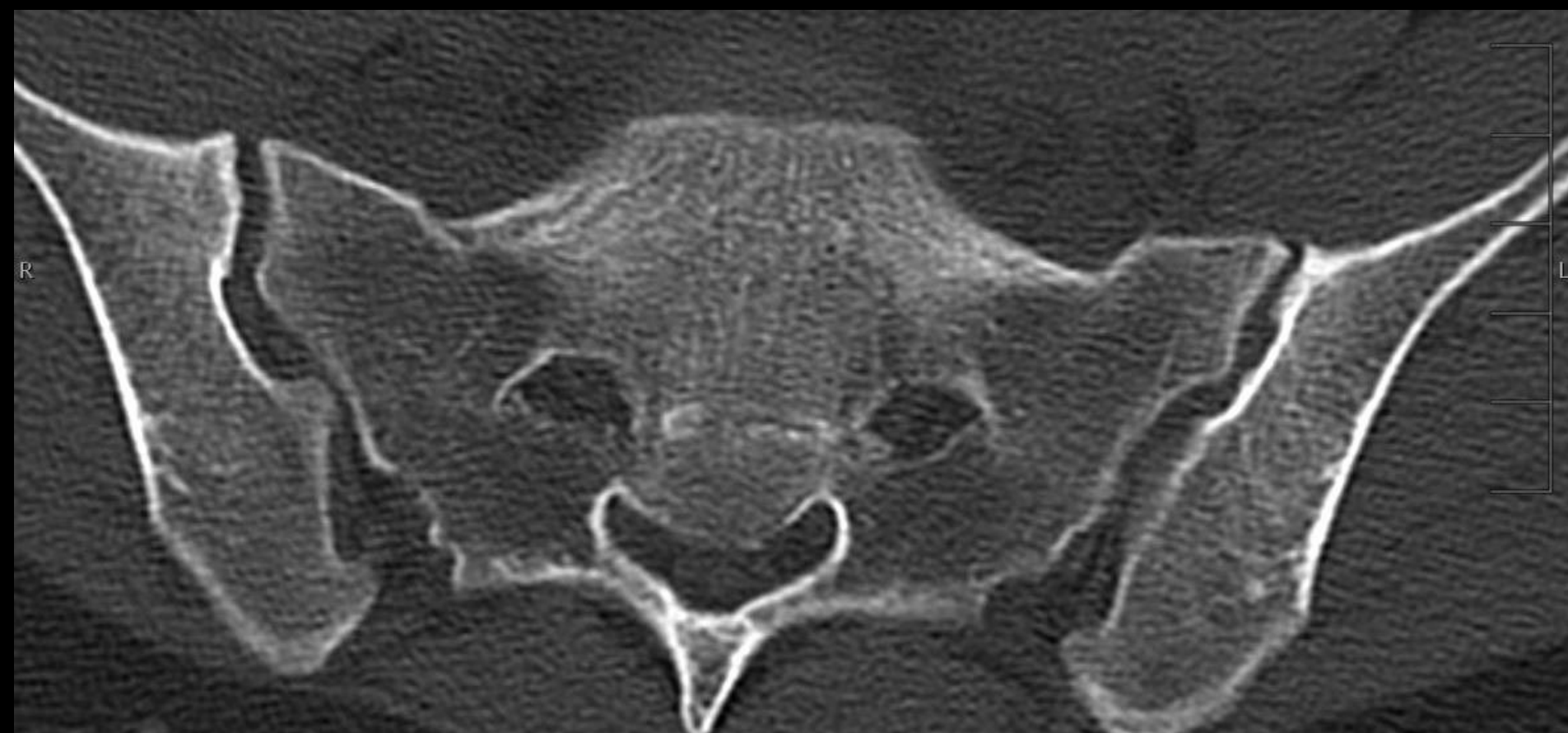Zone 2: 34%

Zone 3: 6%

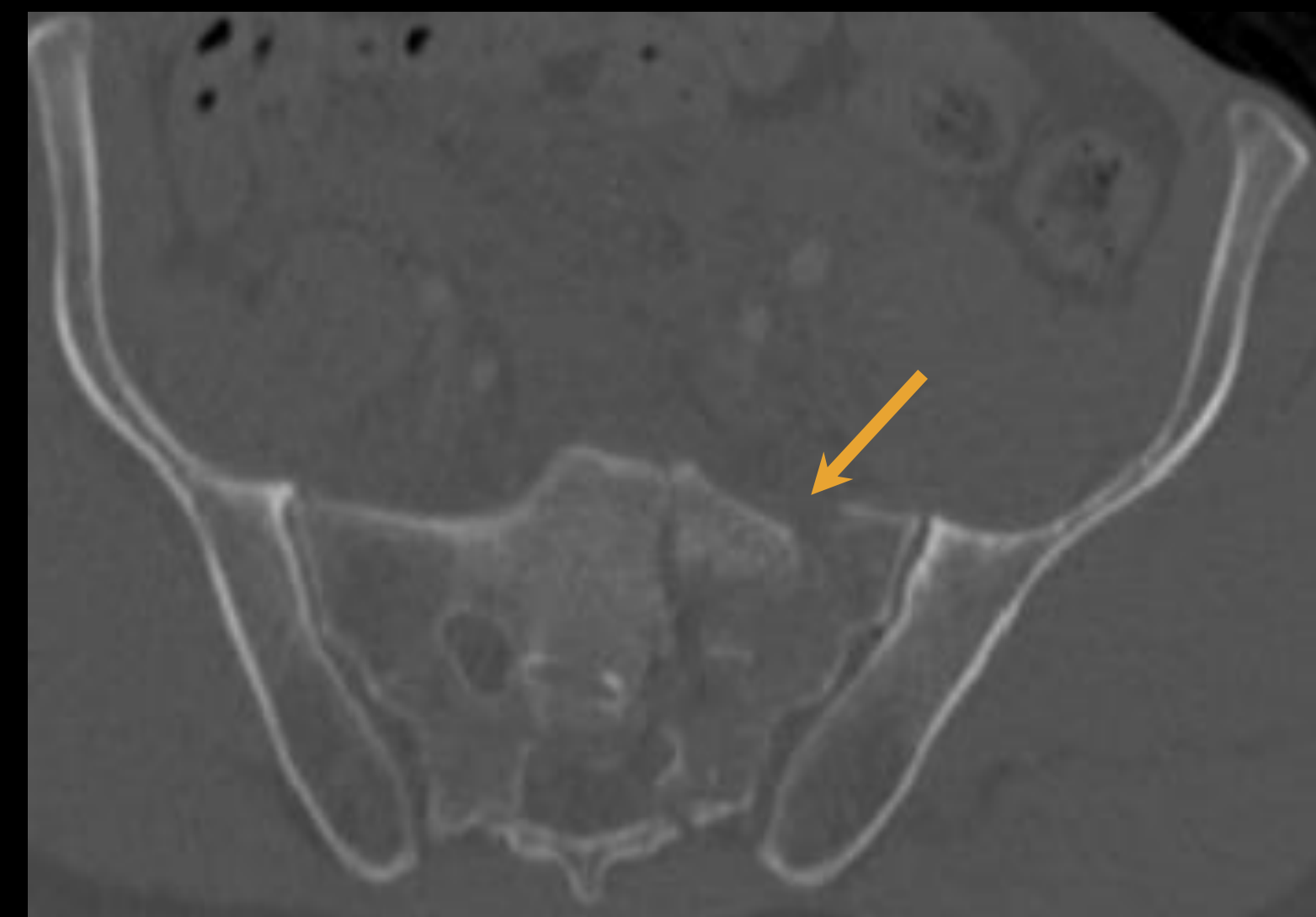
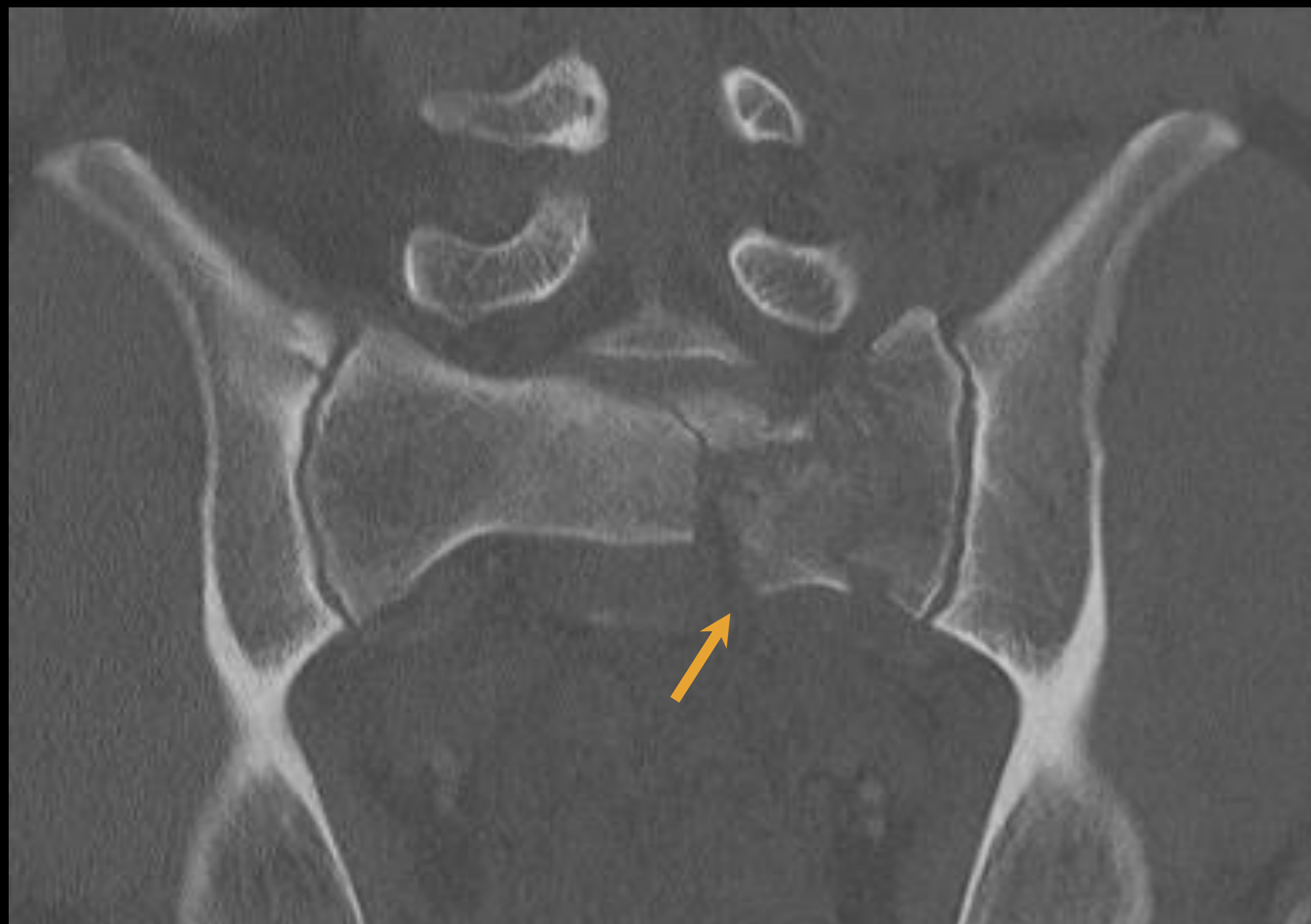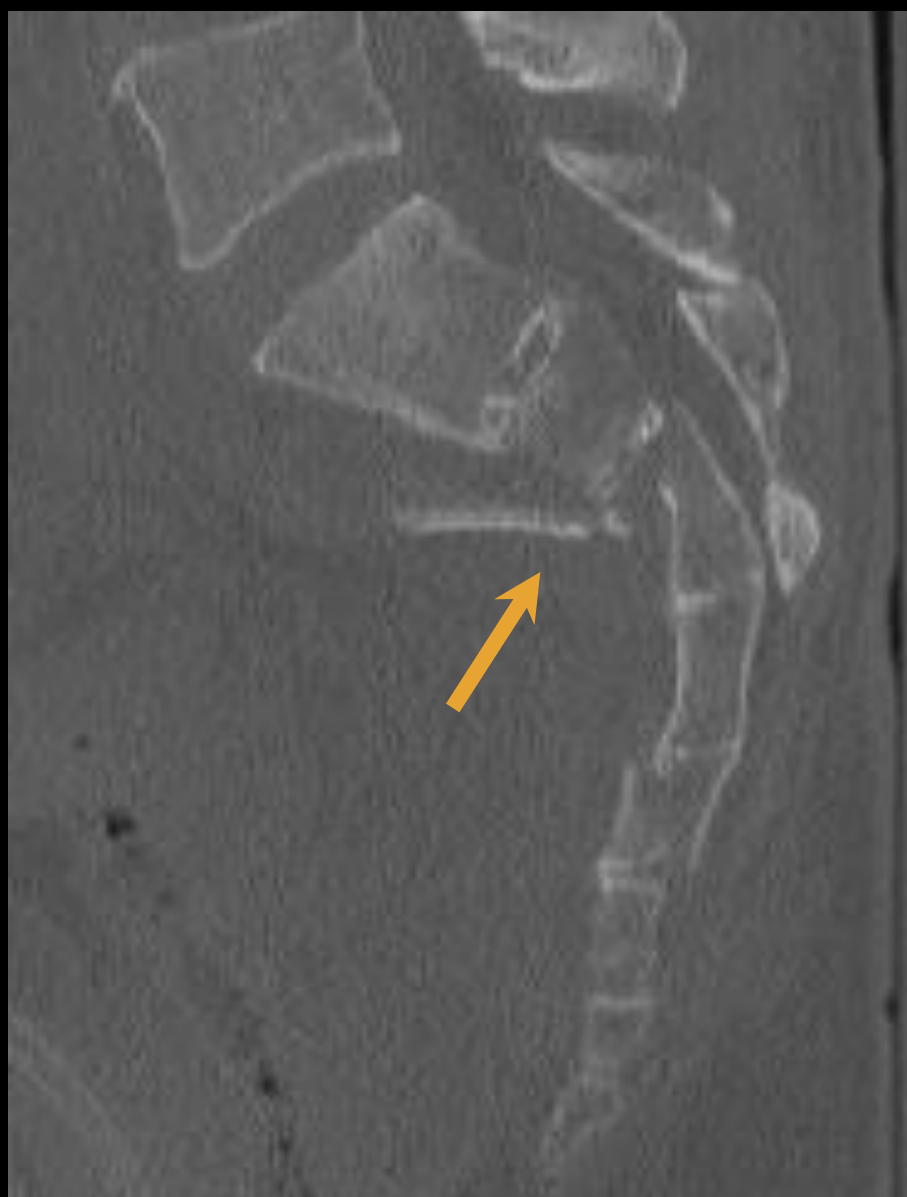Zone 3



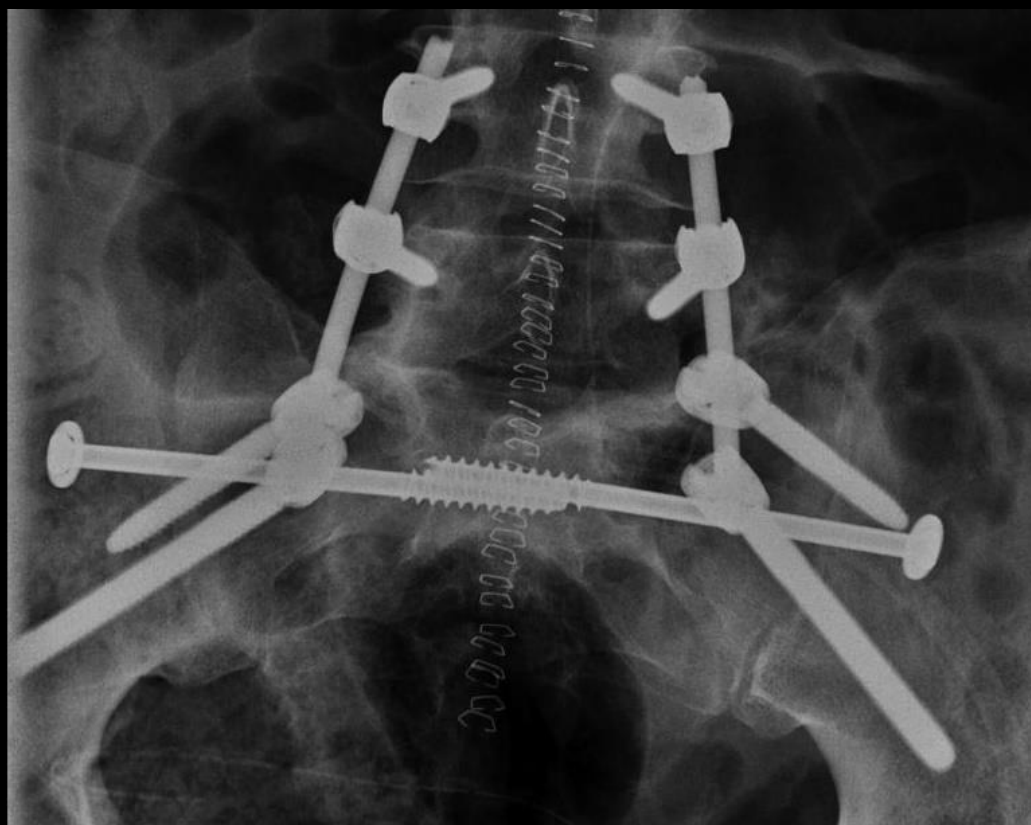
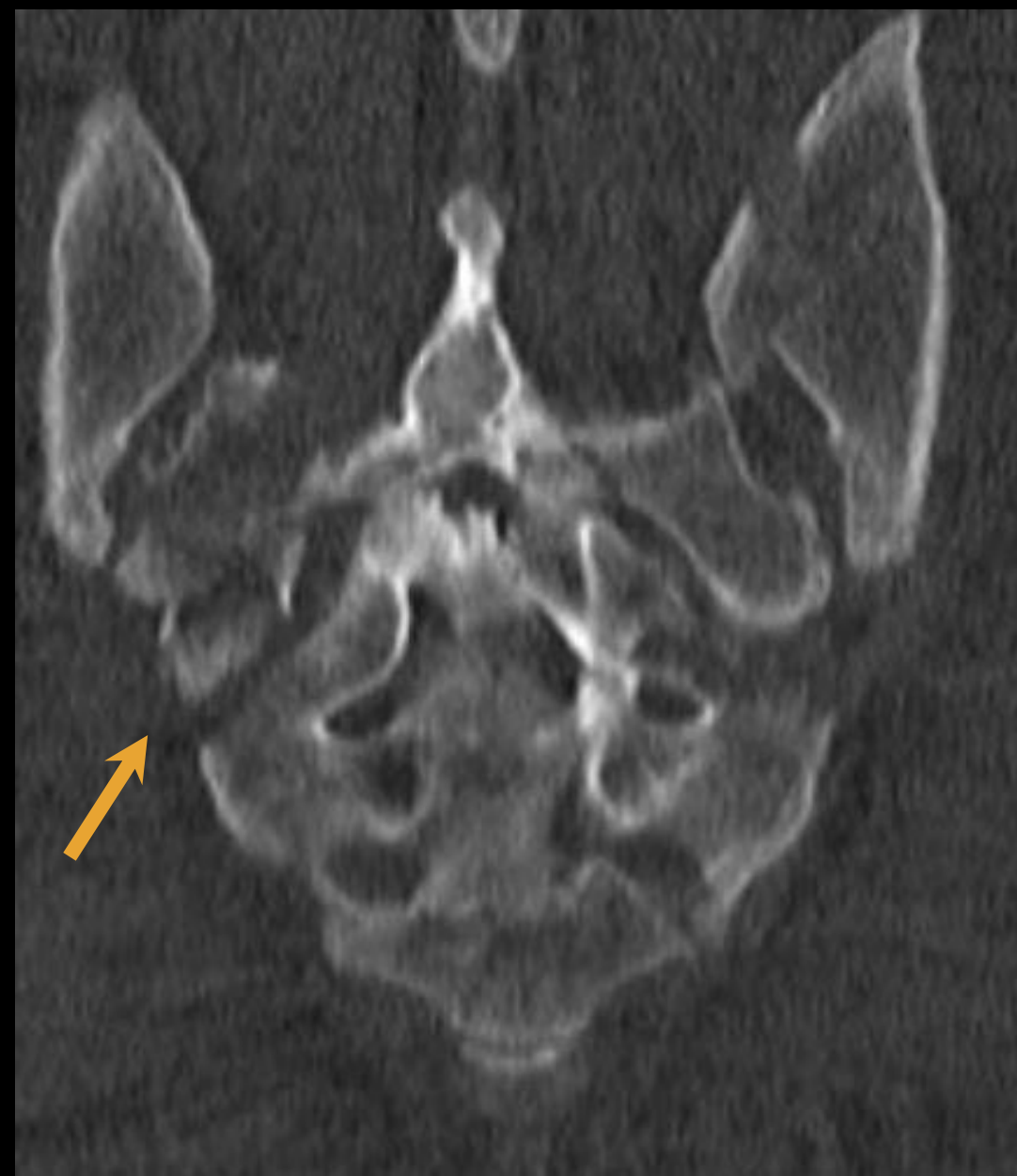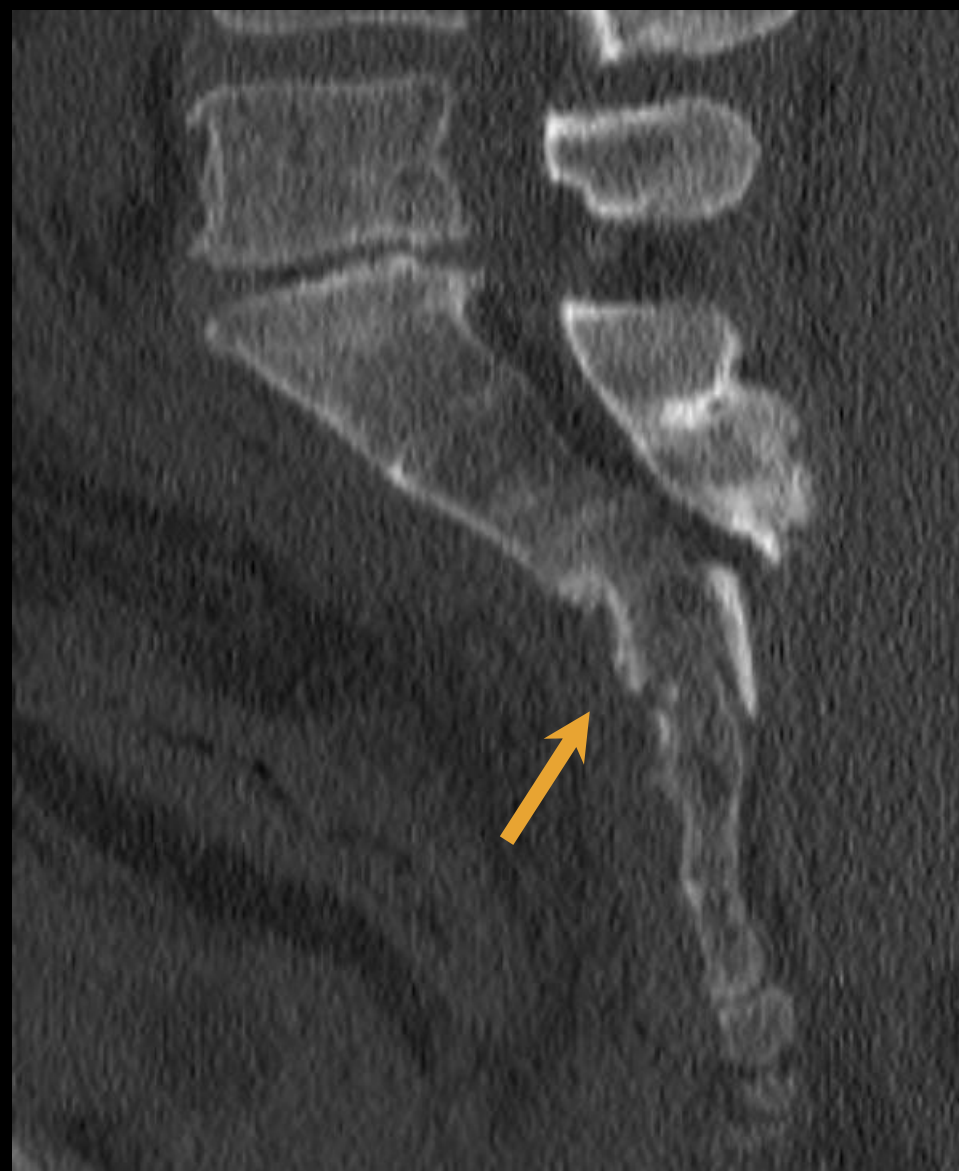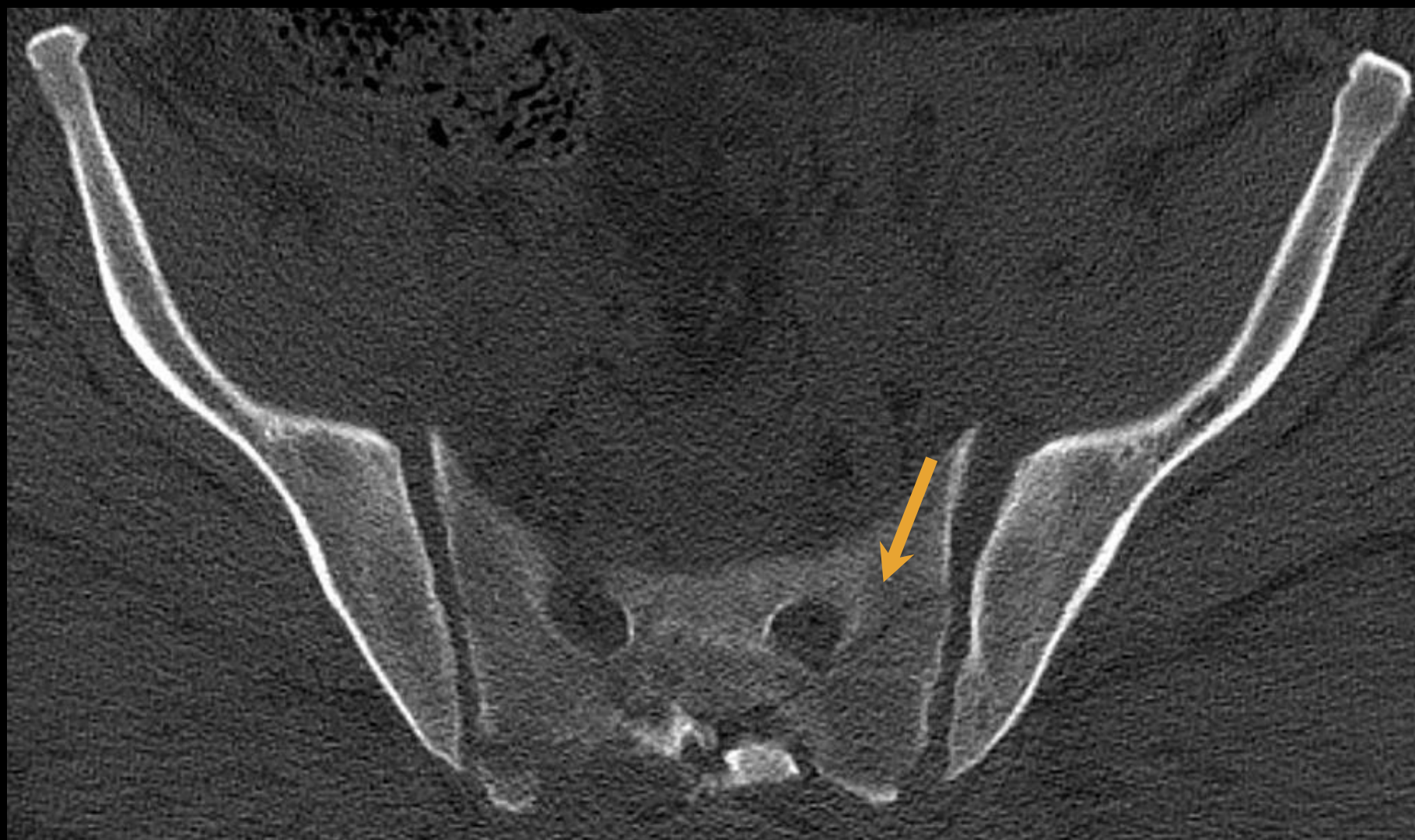Lumbopelvic dissociation



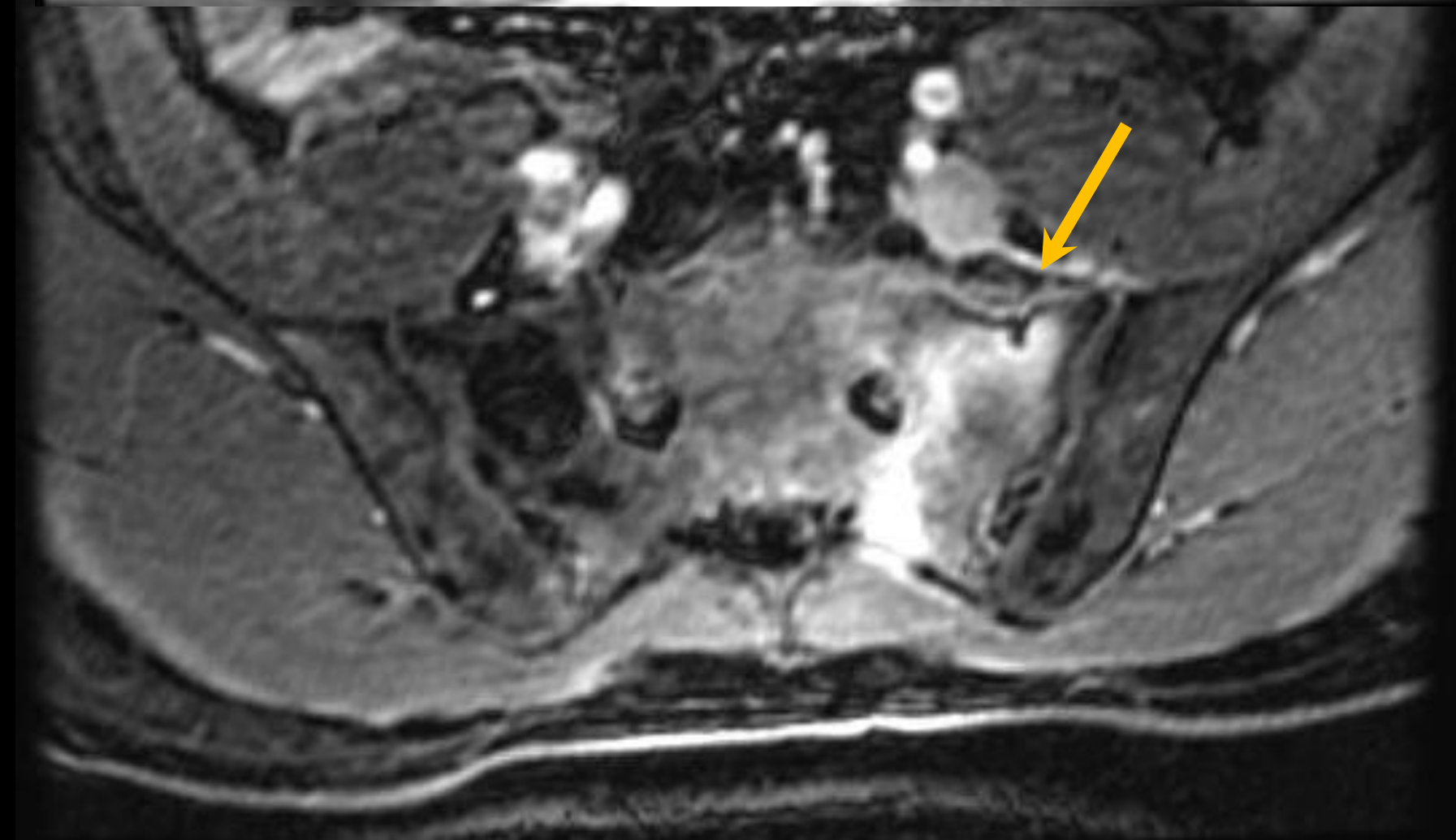
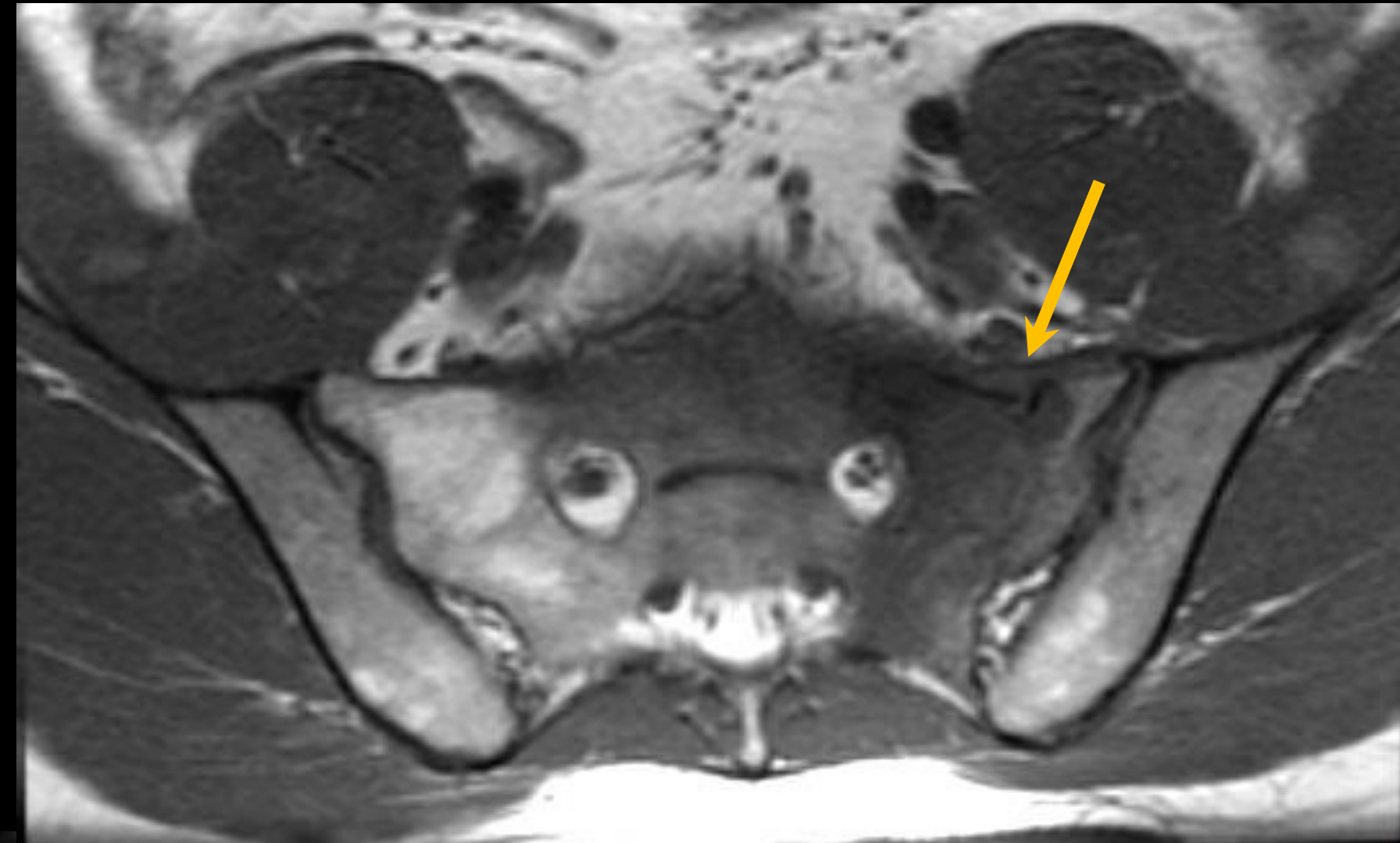
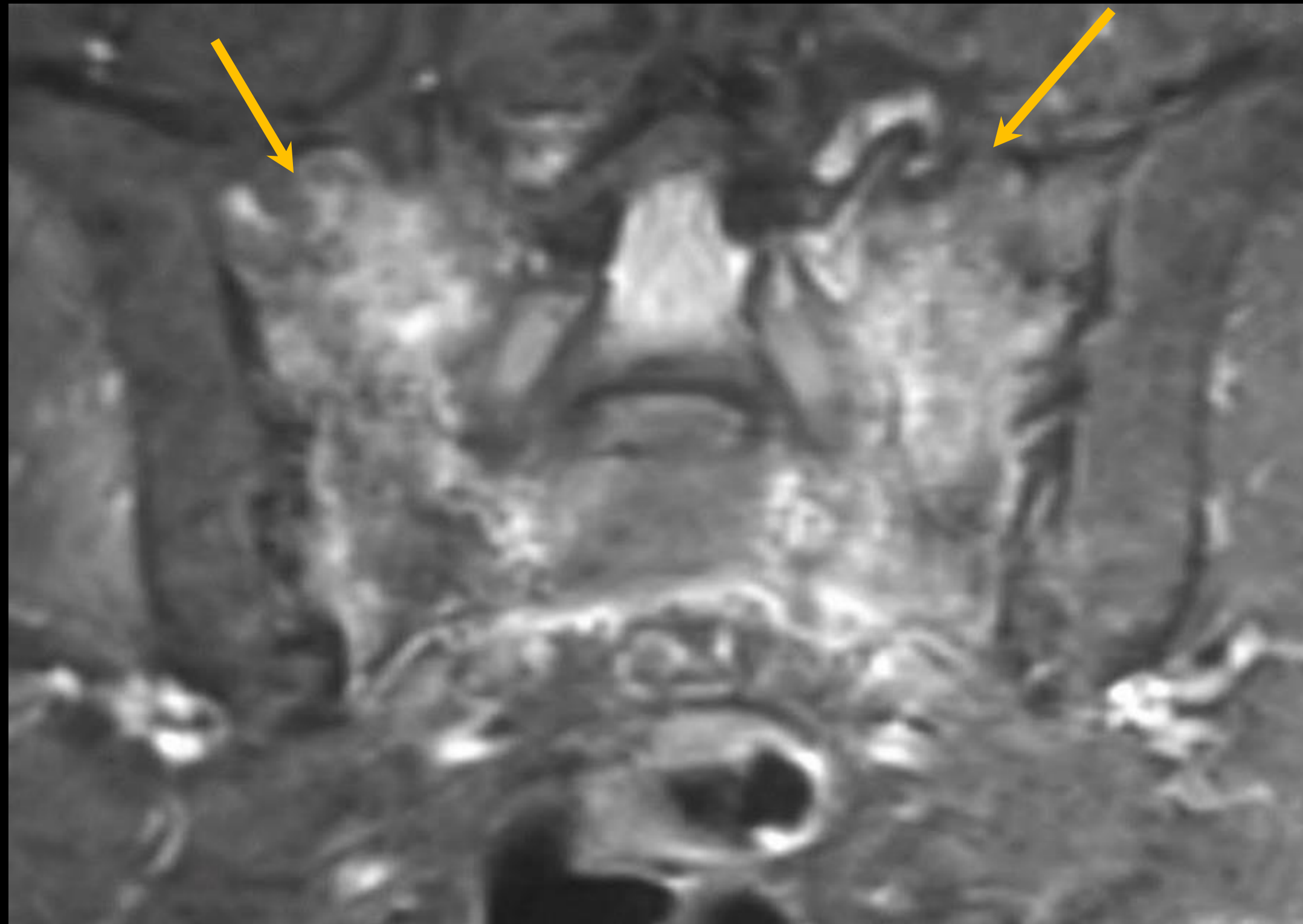
Lumbopelvic Dissociation



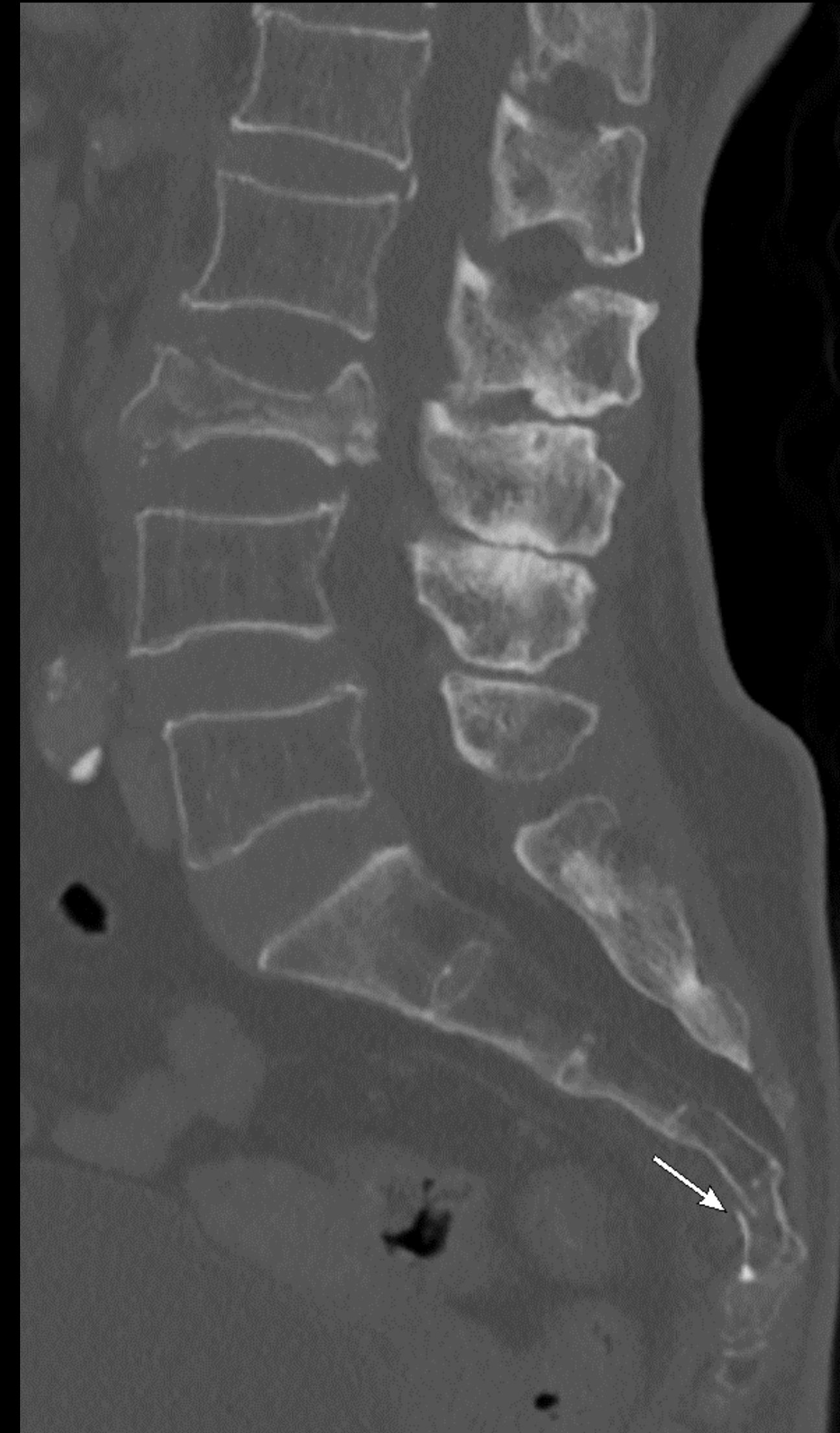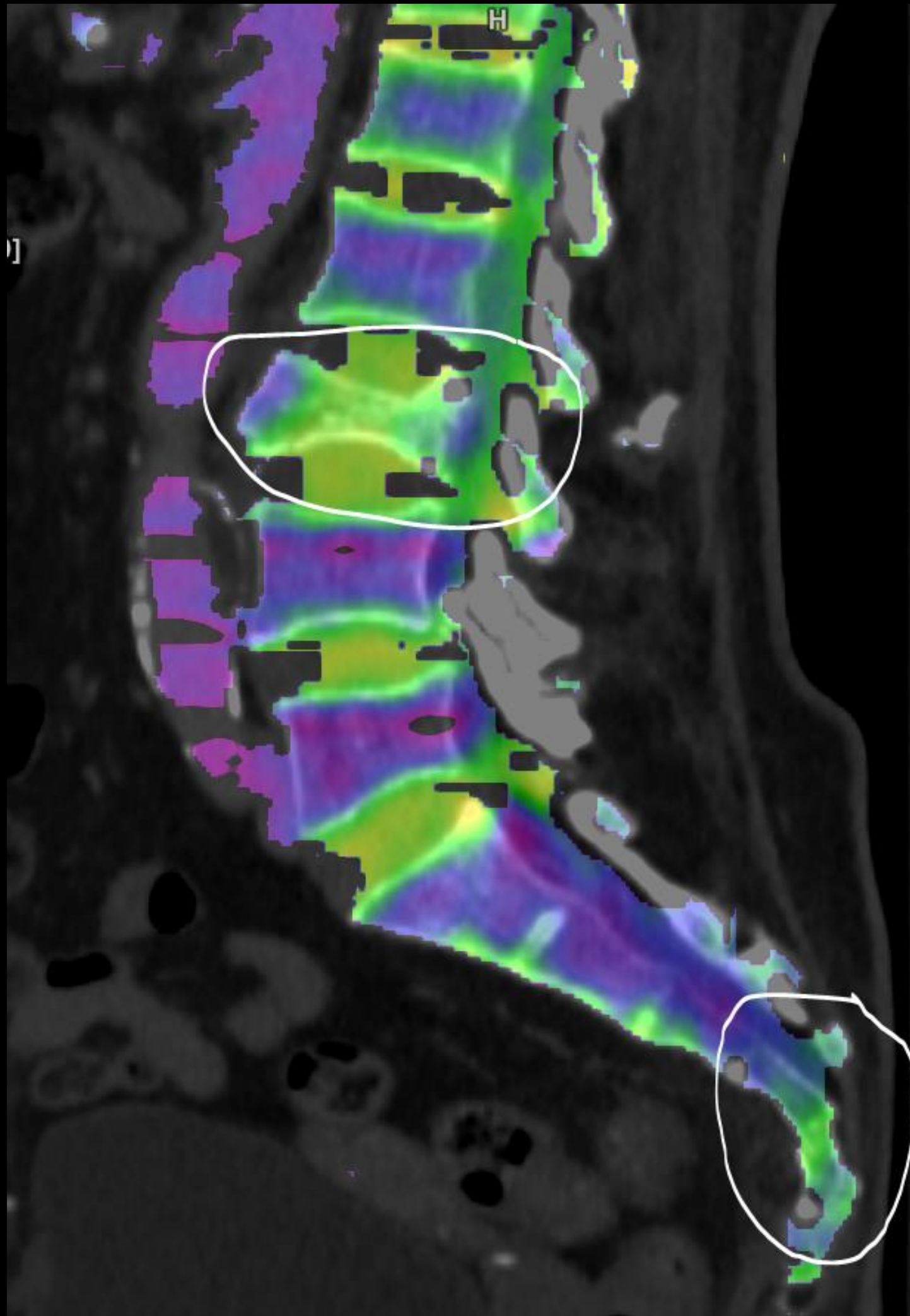Lumbopelvic Dissociation



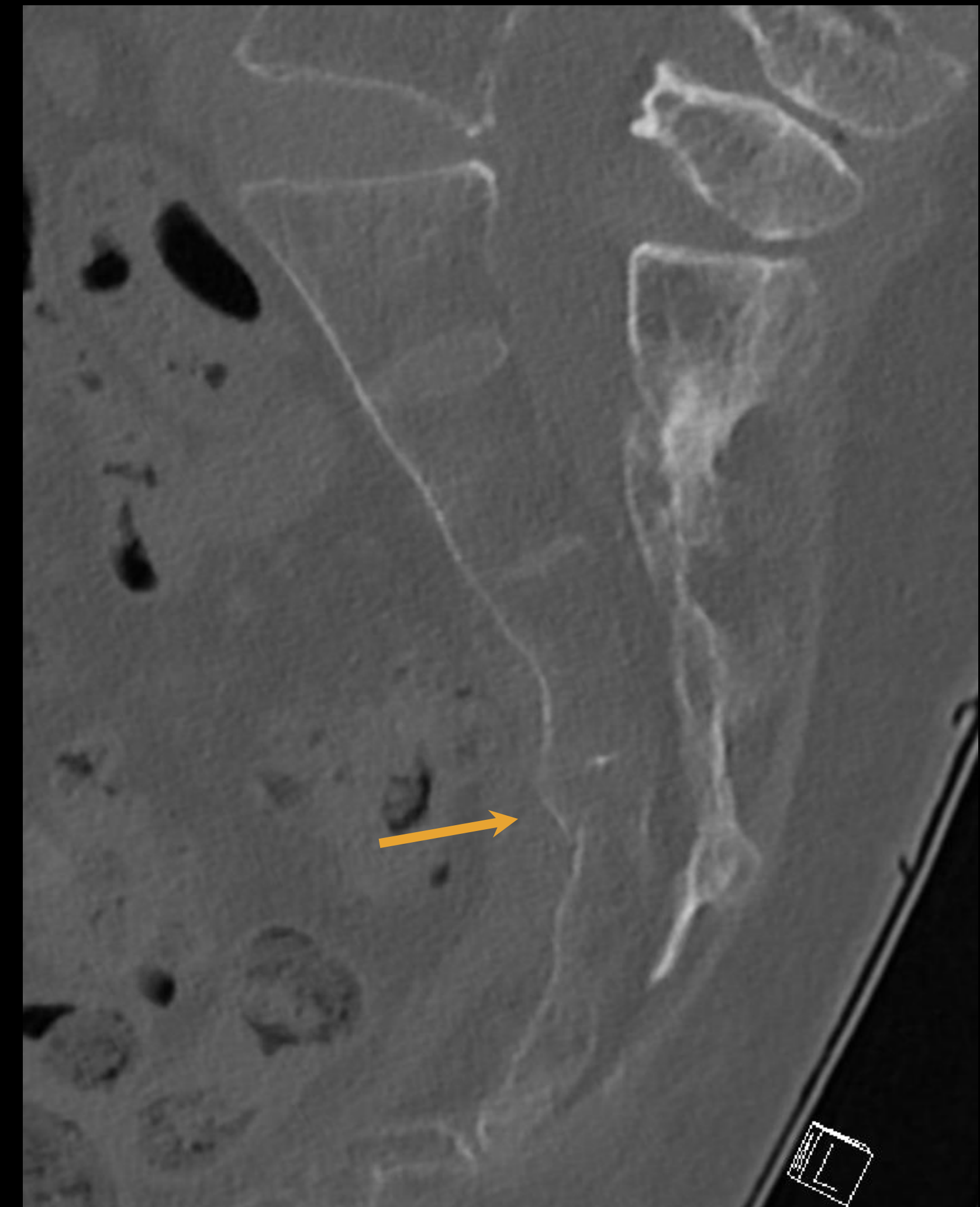
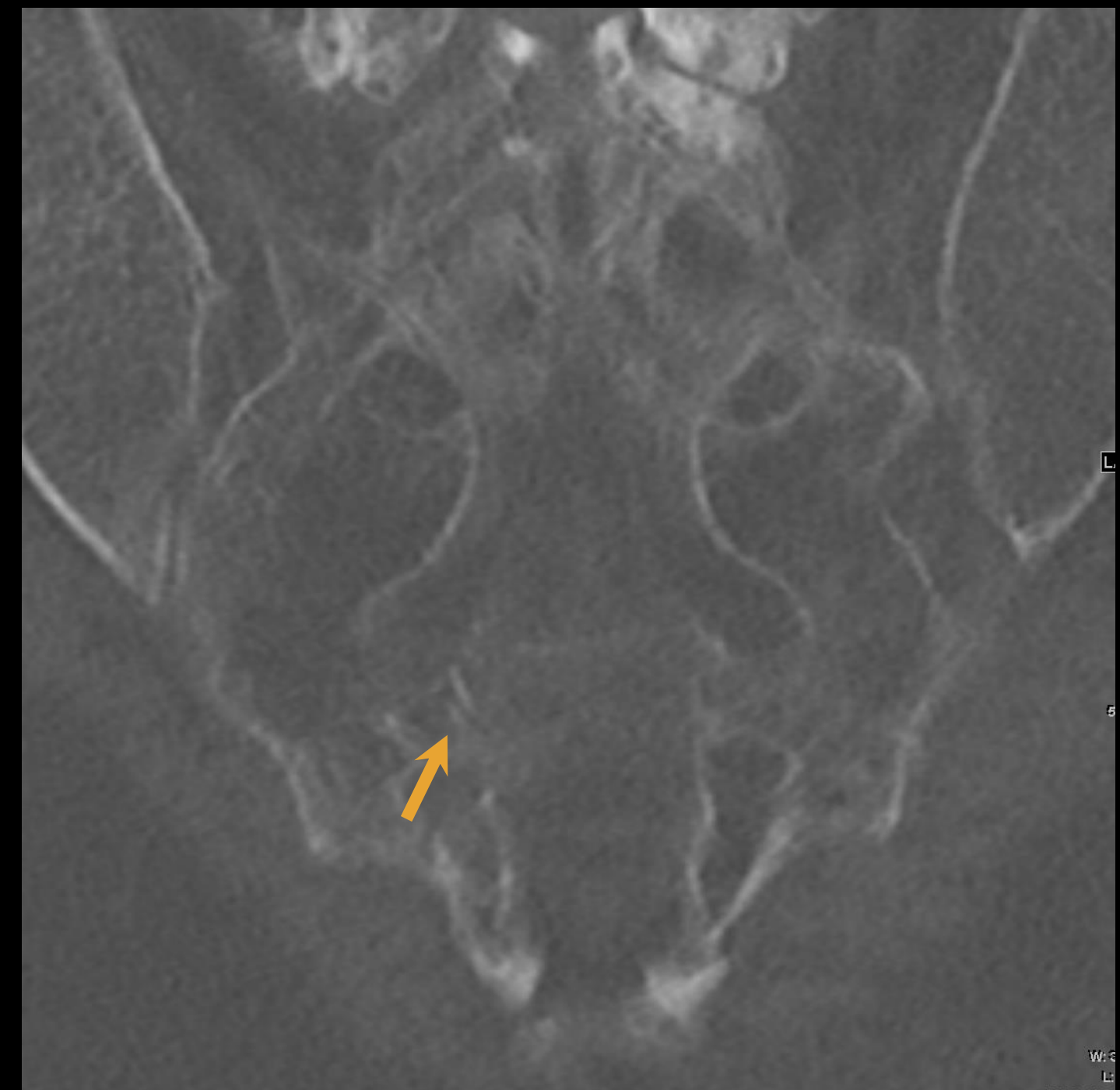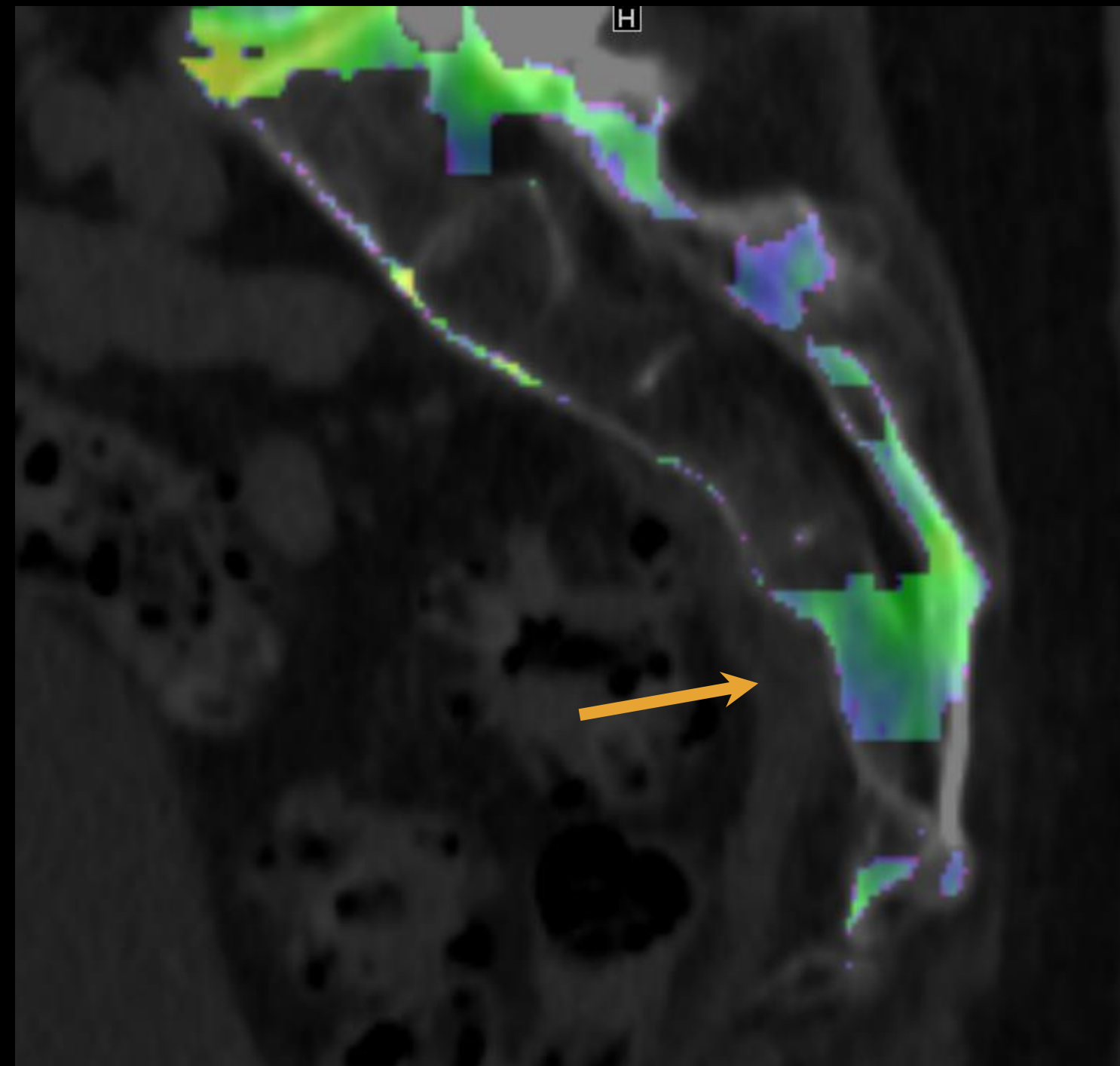
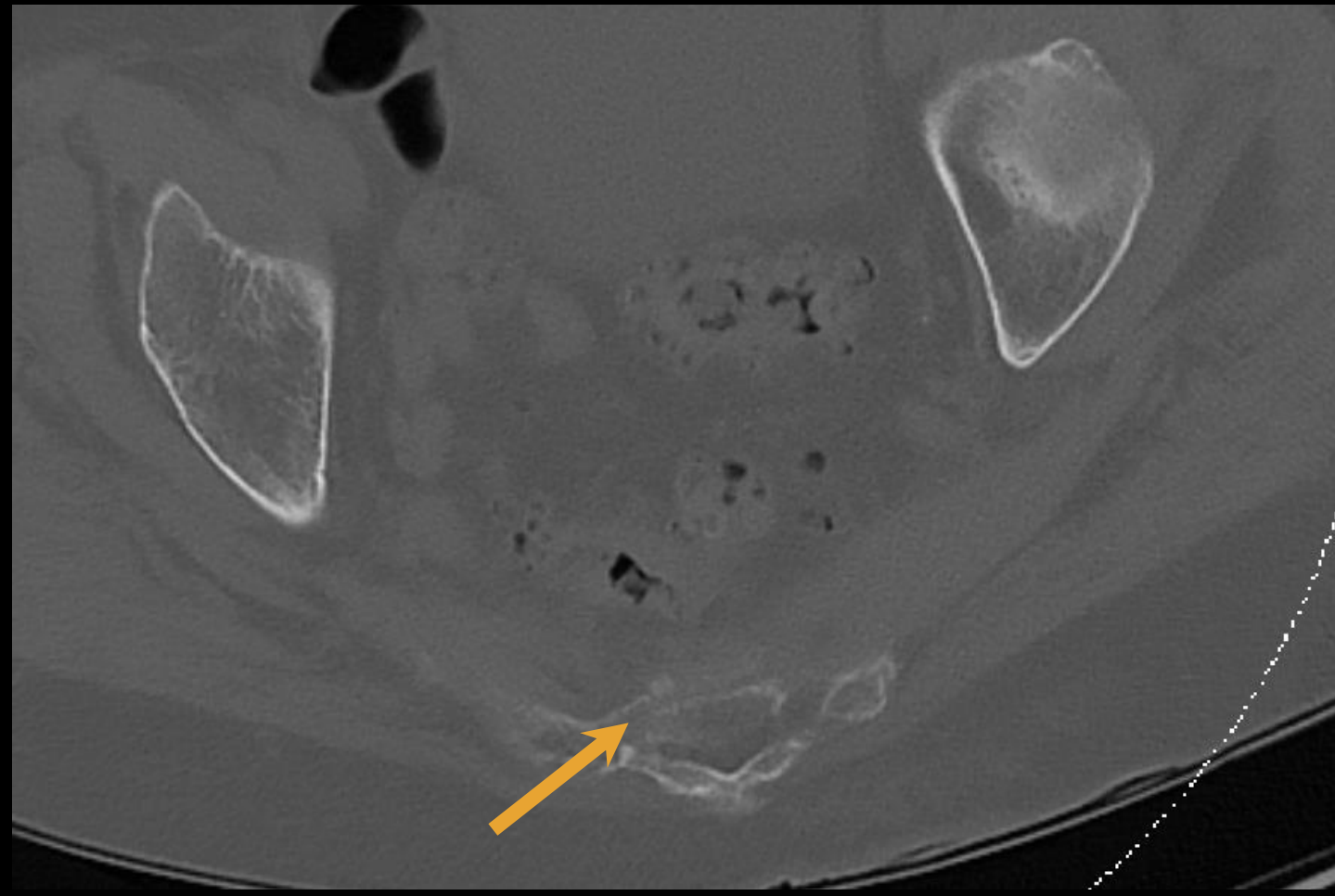
Sacral Insufficiency Fr



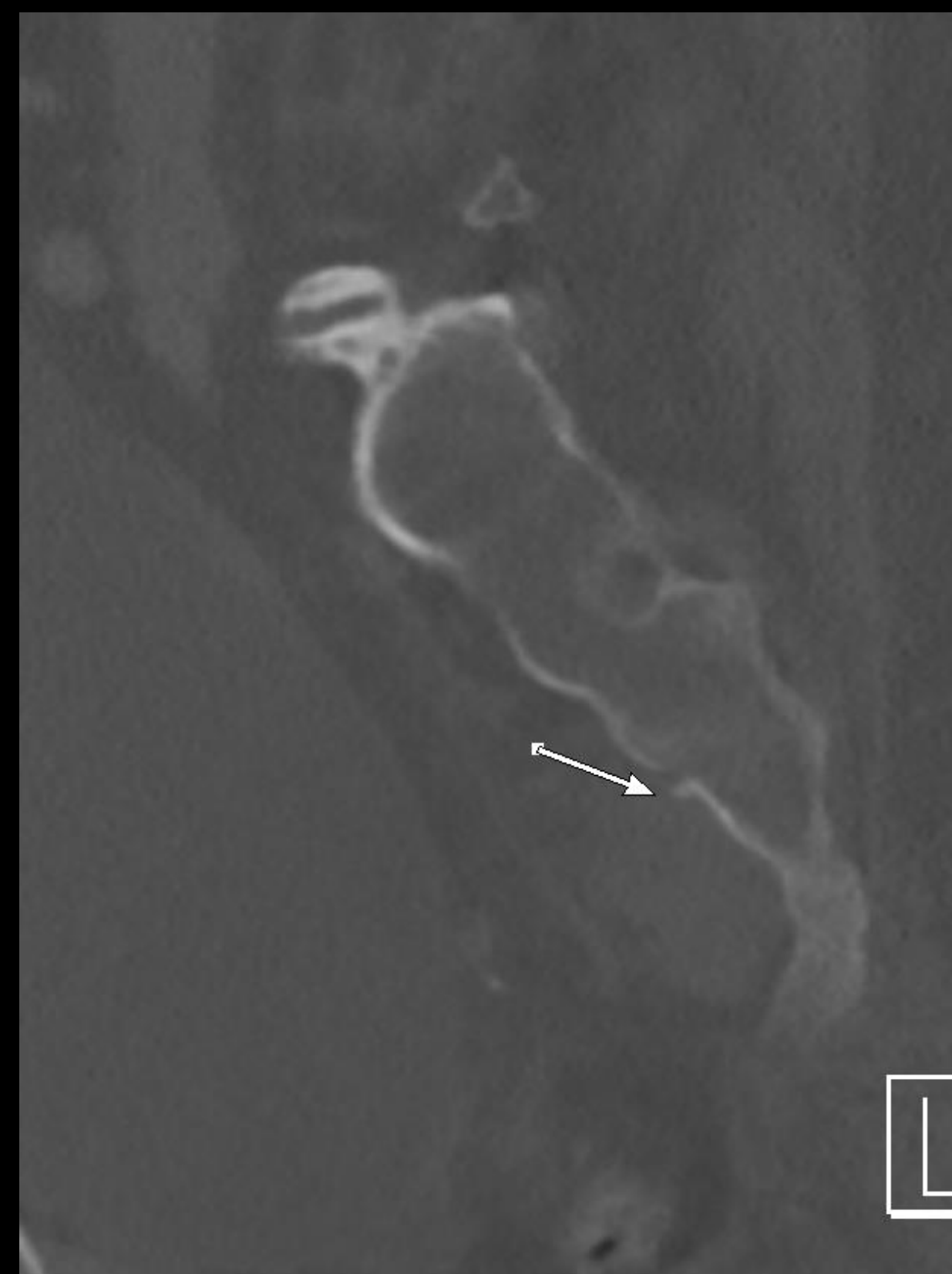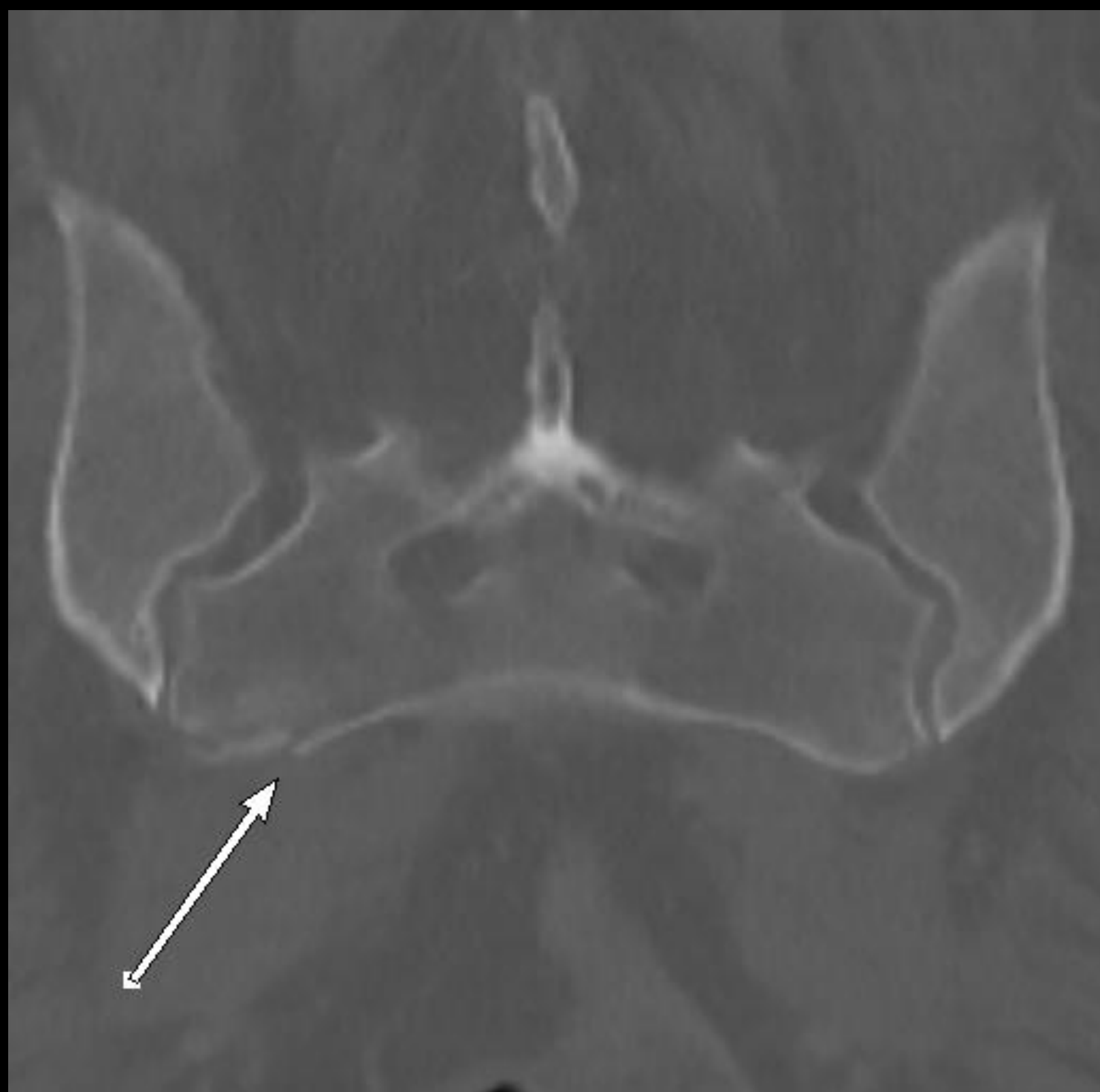Sacral Impaction Fx



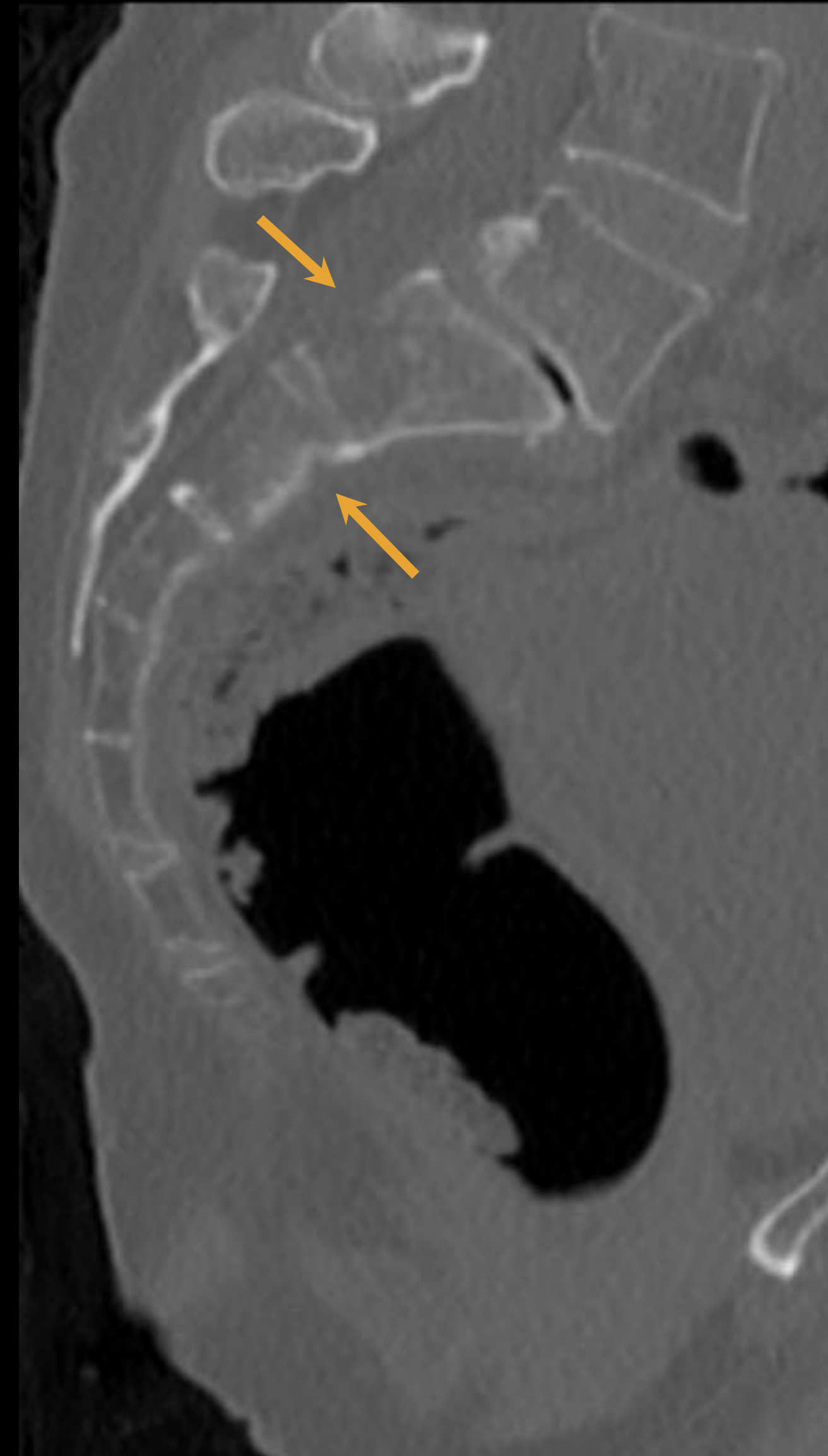
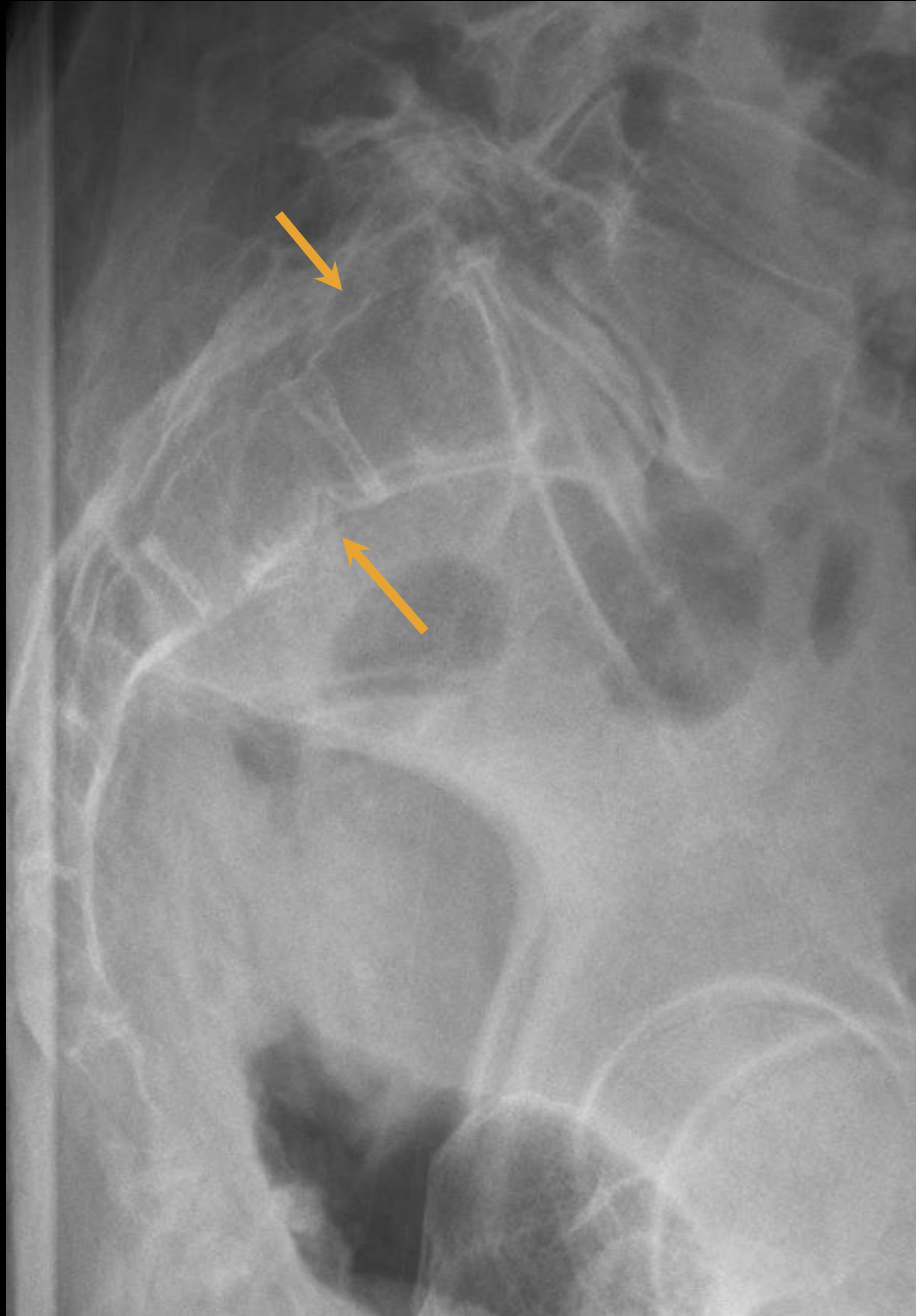
Sacral Impaction Fx




Sacral Impaction Fx



Sacral Impaction Fx





Acknowledgements



Mitch Harris MD

Chair, Orthopedic Surgery

MGH

Prof, Harvard Med School



Michael Weaver MD

Chief, Orthopedic Trauma

BWH

Assoc Prof, Harvard Med School



Scott Sheehan MD

Instructor, MSK Radiology

Univ of Wisconsin School of

Med