

# Liver Masses-Cirrhosis



Kathryn Fowler, MD  
Professor Diagnostic Radiology  
University of California San Diego

# Financial Disclosures

- Consulting: Epigenomics, GE, Bayer
- Institutional Grant Support: GE, Bayer, Median, Pfizer

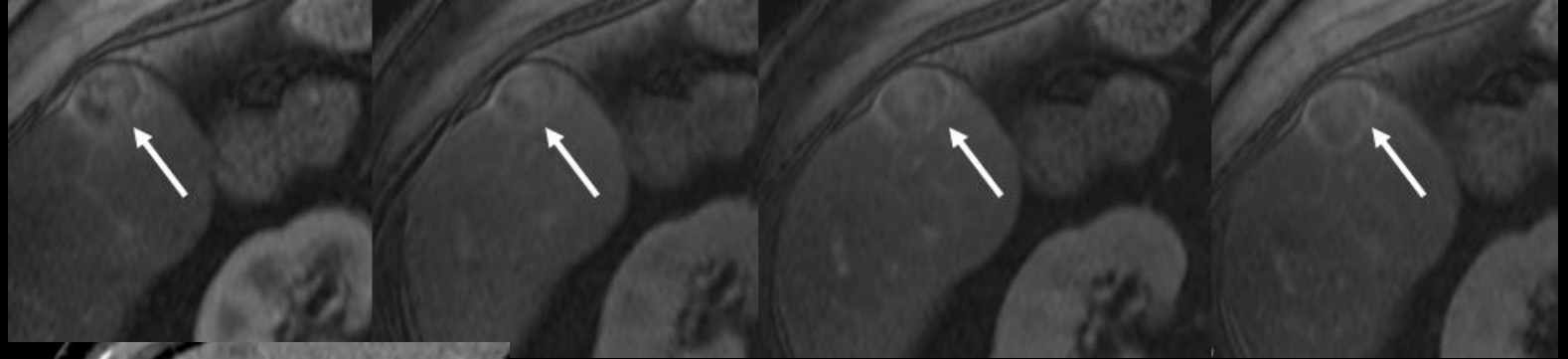
# Resources



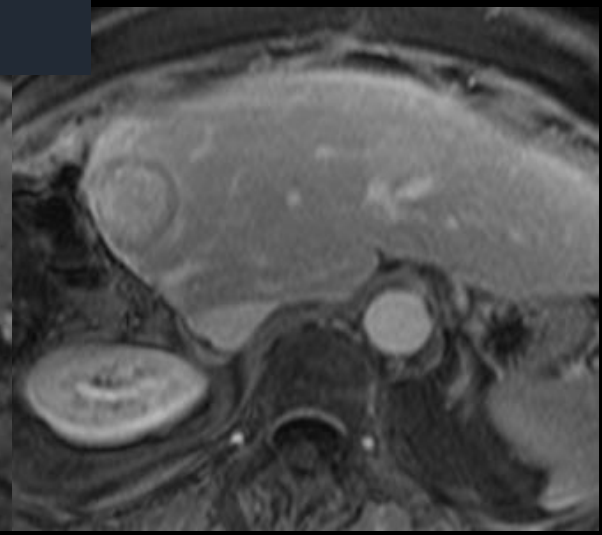
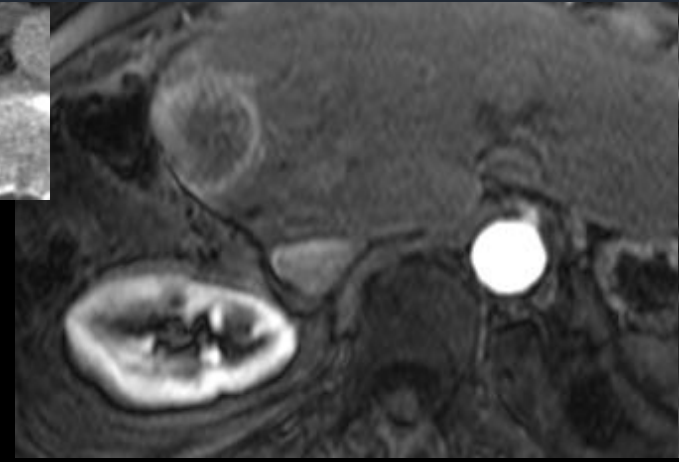
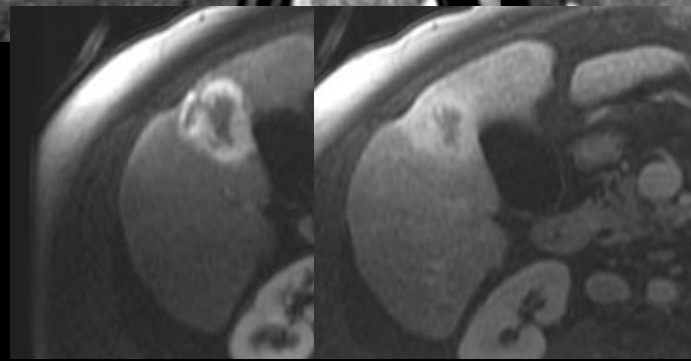
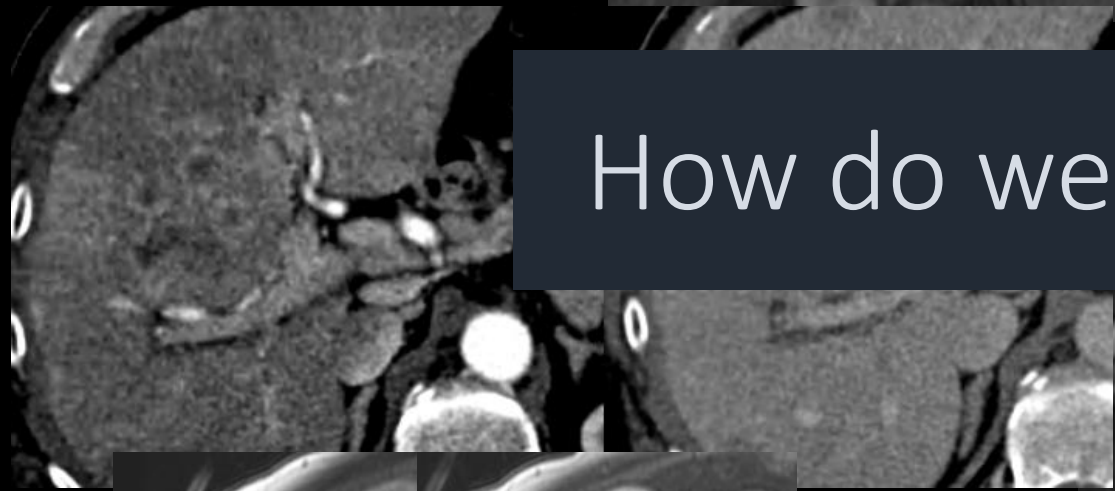
LI-RADS ACR website



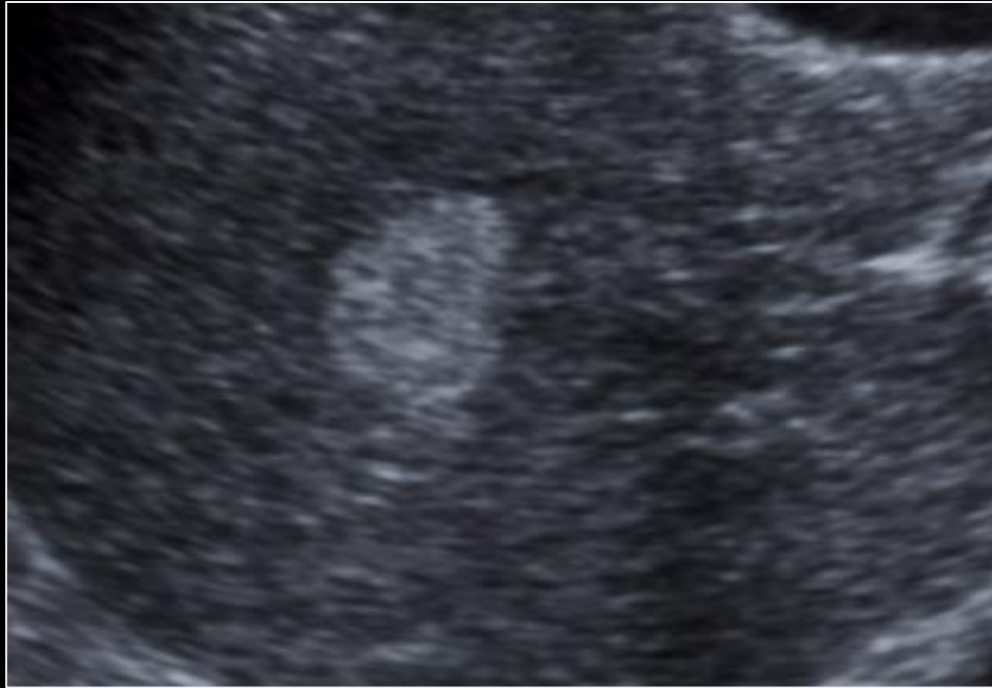
# What's that?



How do we figure it out?



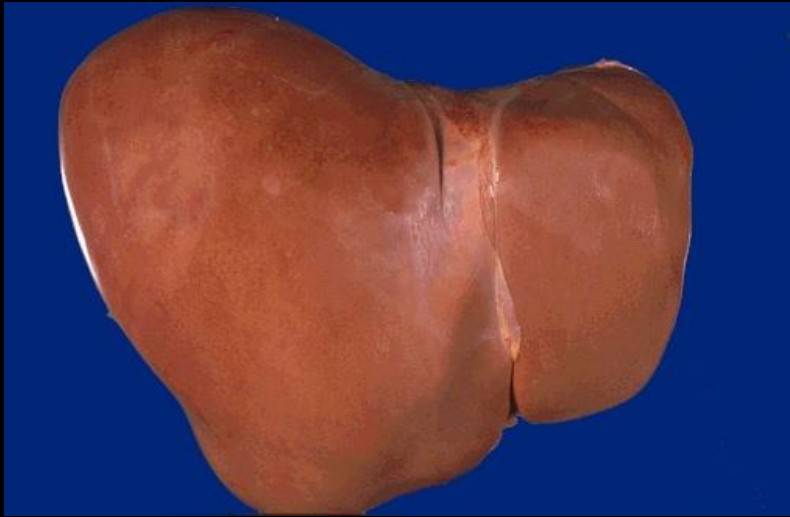
# Step 1: Determine Risk Factors



- Hyperechoic, lobular lesion with posterior acoustic enhancement

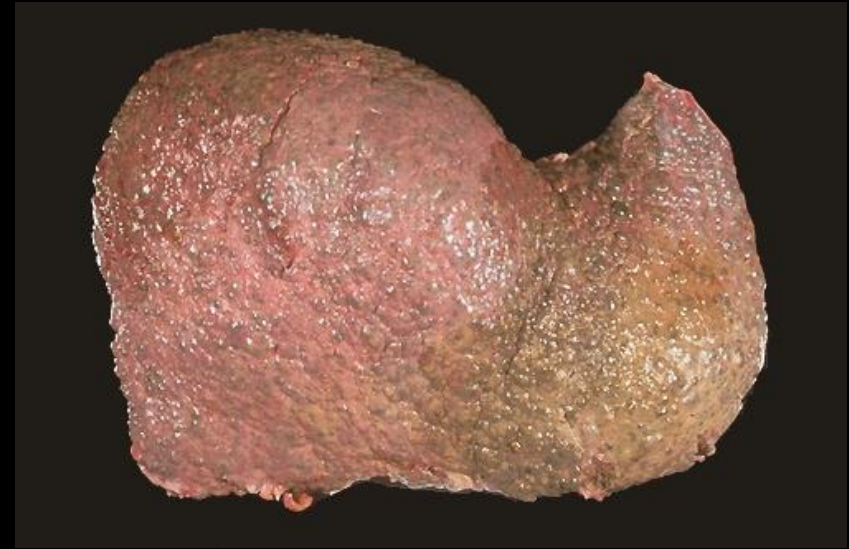
What is the most likely diagnosis?

If patient has cirrhosis...HCC!!!!



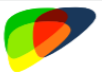Benign lesions!

Cancer is rare\*



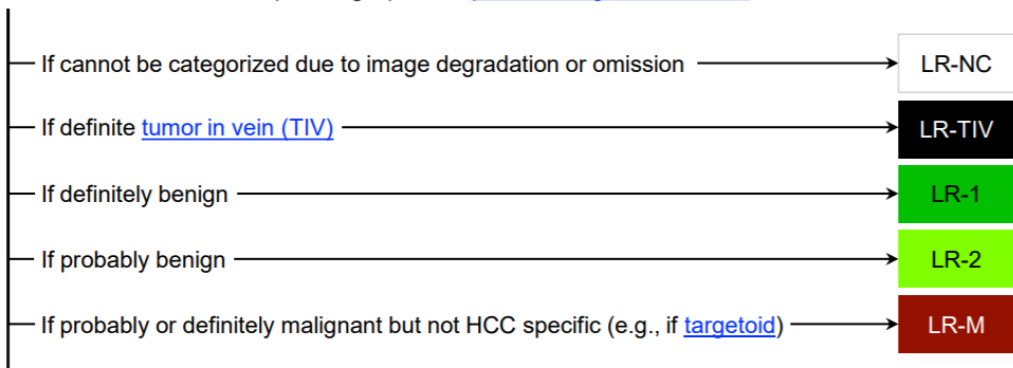
Cancer!  
-HCC, ICC

Metastatic disease-RARE

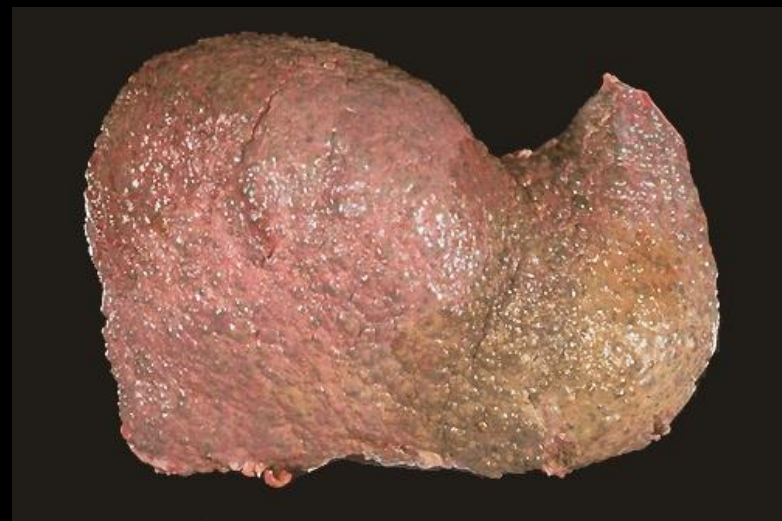
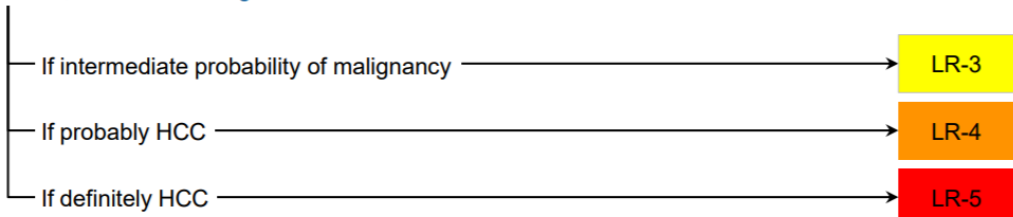


# CT/MRI LI-RADS® v2018 CORE

Untreated observation without pathologic proof in [patient at high risk for HCC](#)



Otherwise, use CT/MRI diagnostic table below



## CT/MRI Diagnostic Table

Arterial phase hyperenhancement (APHE)		No APHE		Nonrim APHE		
		< 20	≥ 20	< 10	10-19	≥ 20
Observation size (mm)						
Count additional major features: • Enhancing "capsule" • Nonperipheral "washout" • Threshold growth	None	LR-3	LR-3	LR-3	LR-3	LR-4
	One	LR-3	LR-4	LR-4	LR-4 / LR-5	LR-5
	≥ Two	LR-4	LR-4	LR-4	LR-5	LR-5

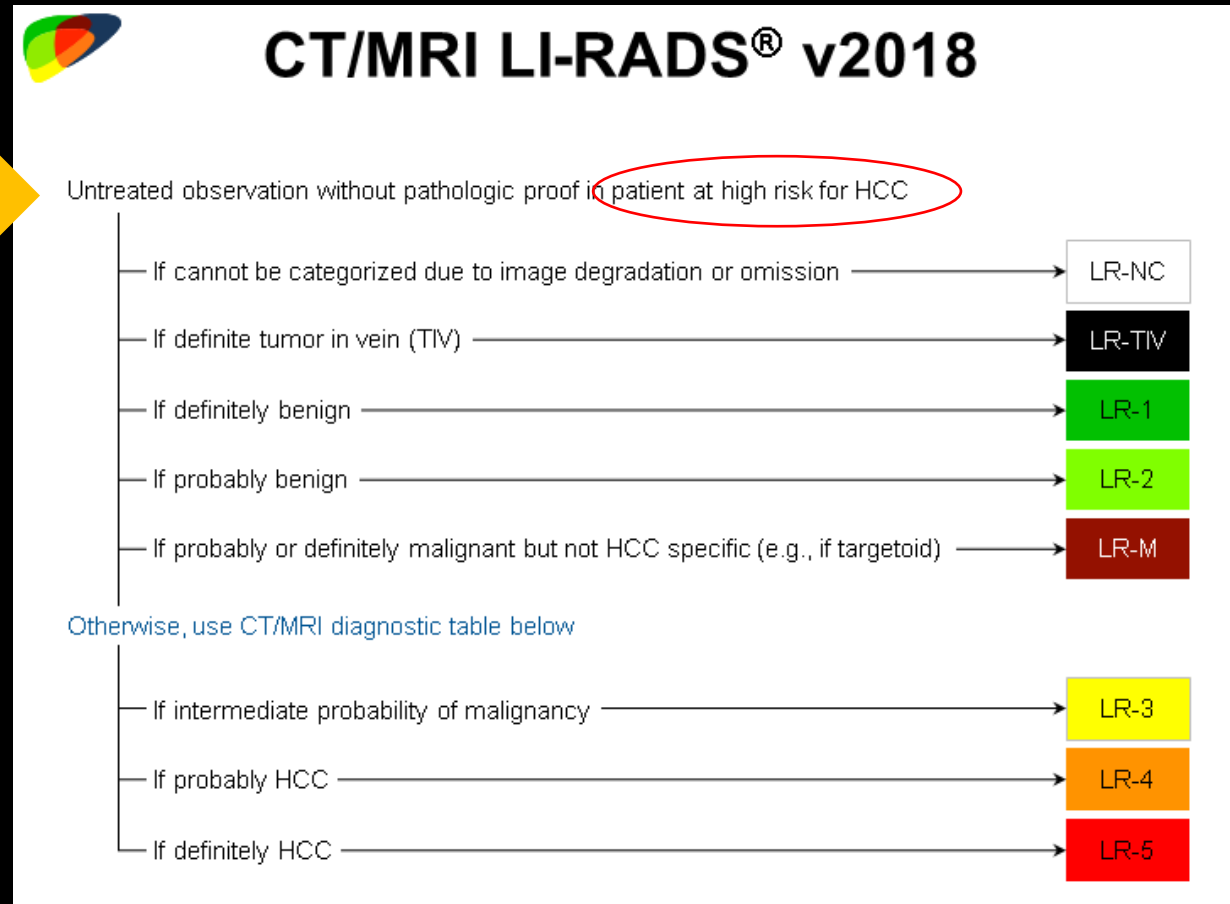

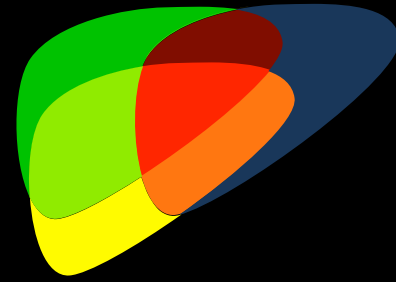
**LR-4 / LR-5** Observations in this cell are categorized based on one additional major feature:

- LR-4 – if enhancing "capsule"
- LR-5 – if nonperipheral "washout" **OR** threshold growth

*If unsure about the presence of any major feature: characterize that feature as absent*

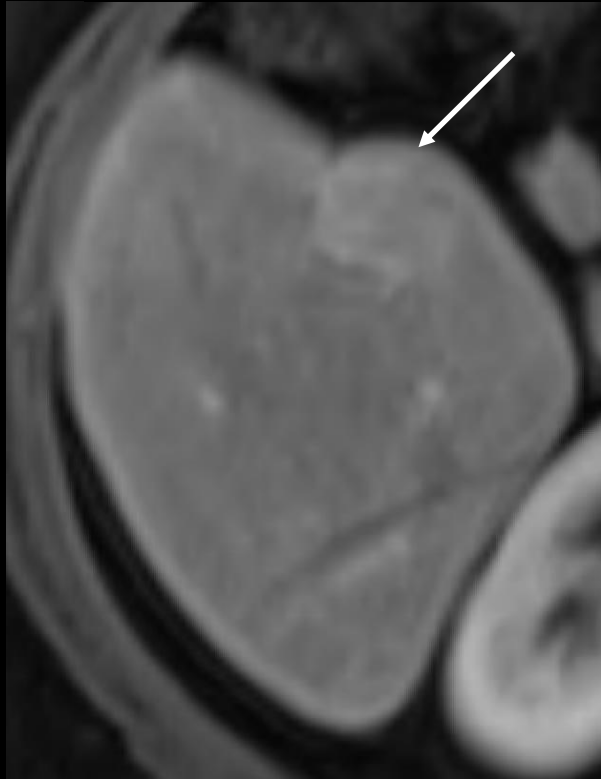


# Step-wise algorithm

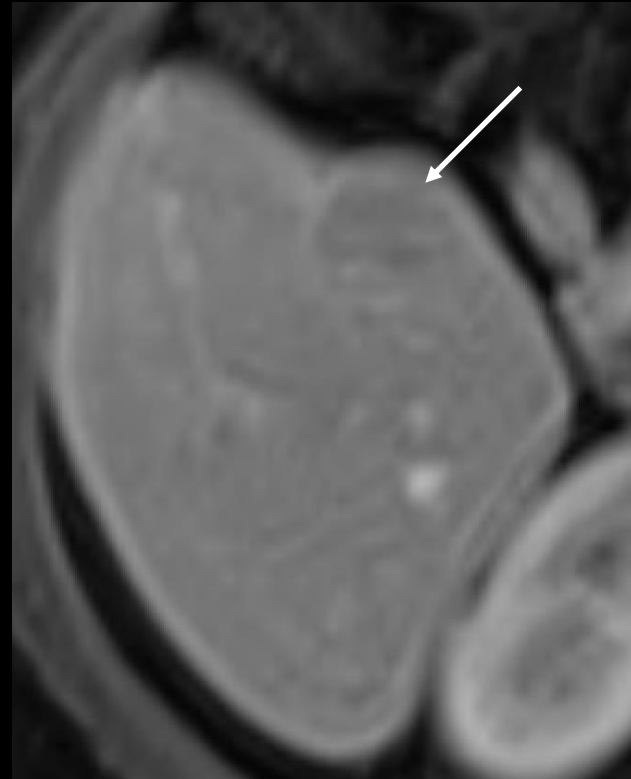




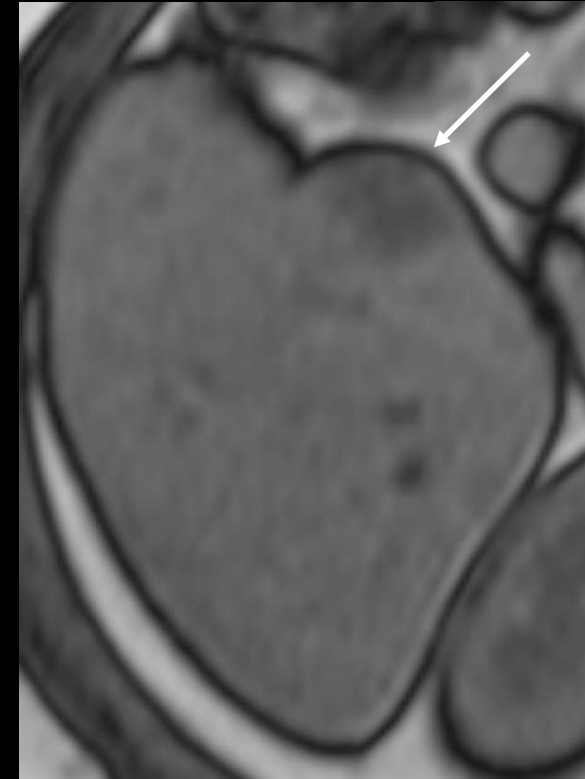
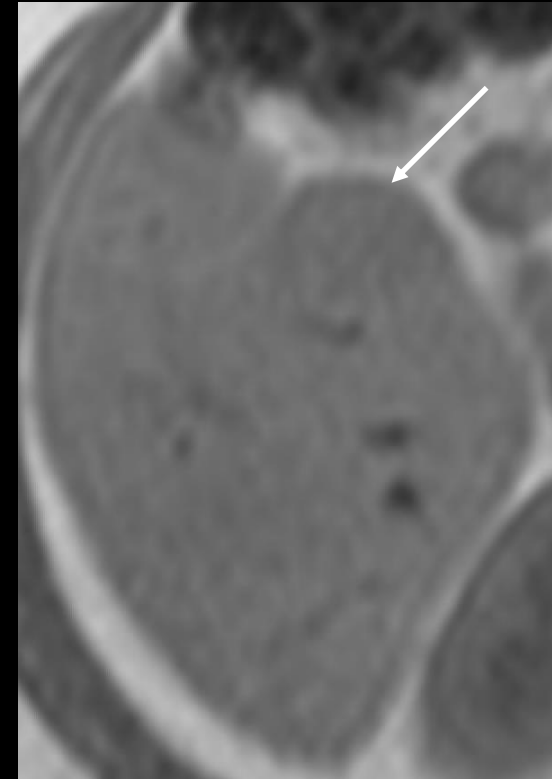
# HCC?



APHE



Washout appearance



Fat in mass

**NO...Adenoma, 30 yo woman NAFLD**

# How do we achieve a specific diagnosis?

Step 1: Apply imaging diagnosis only in population with high pre-test probability of HCC



**APPLY LI-RADS**

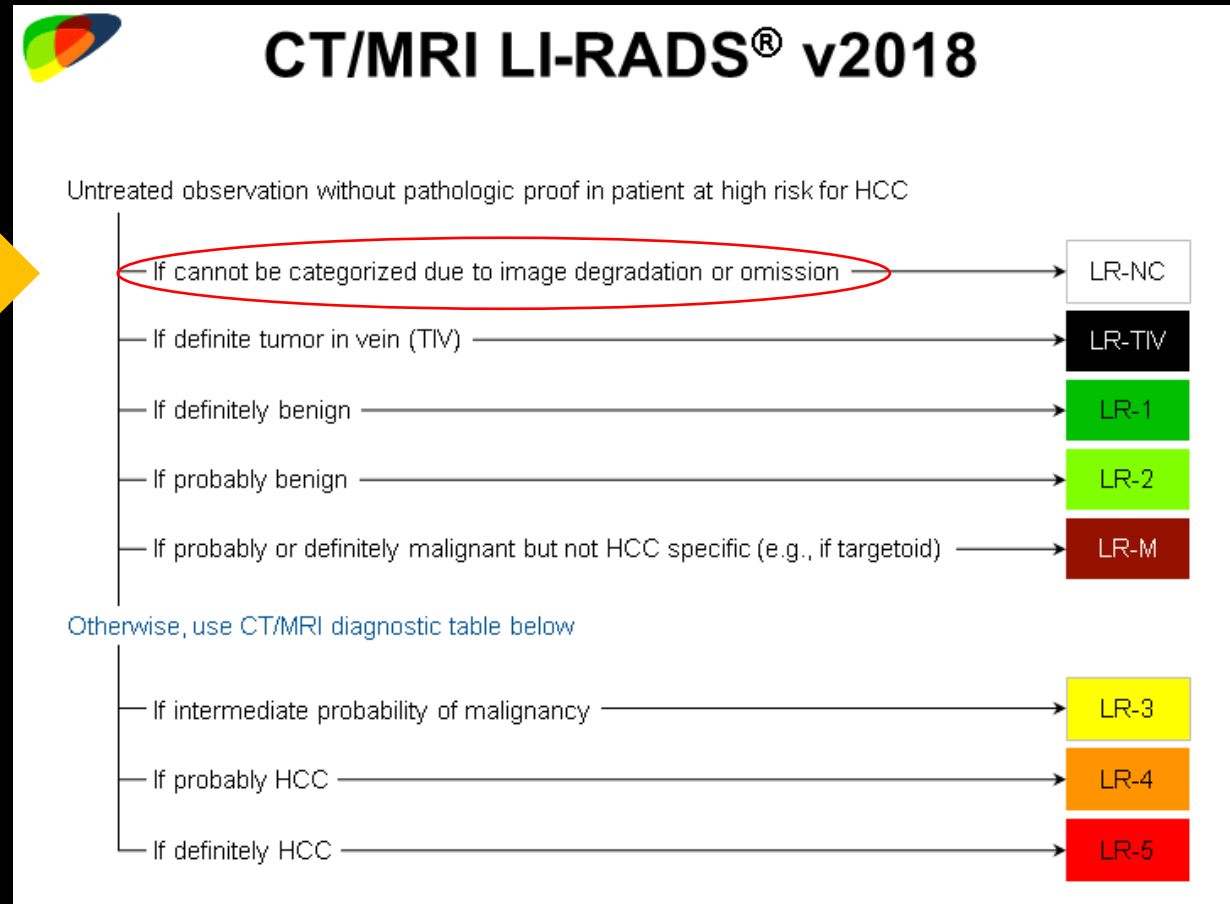

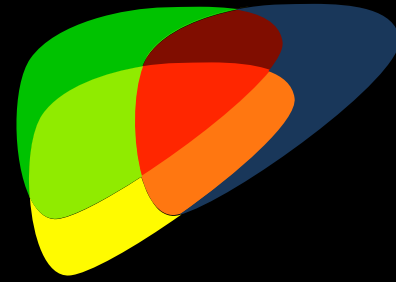
Cirrhosis  
Hepatitis B viral infection  
Current or prior HCC



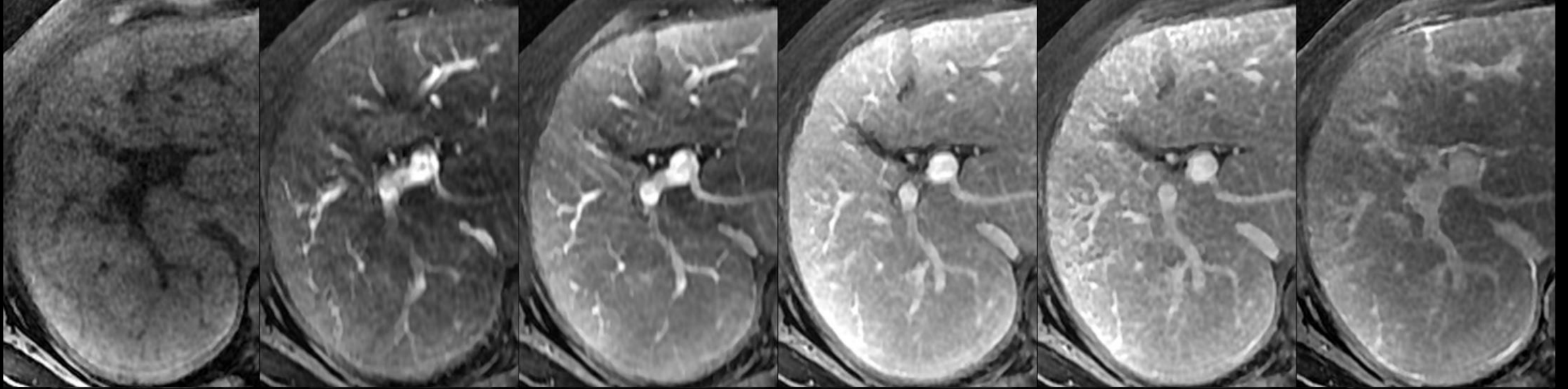
**DO NOT APPLY**

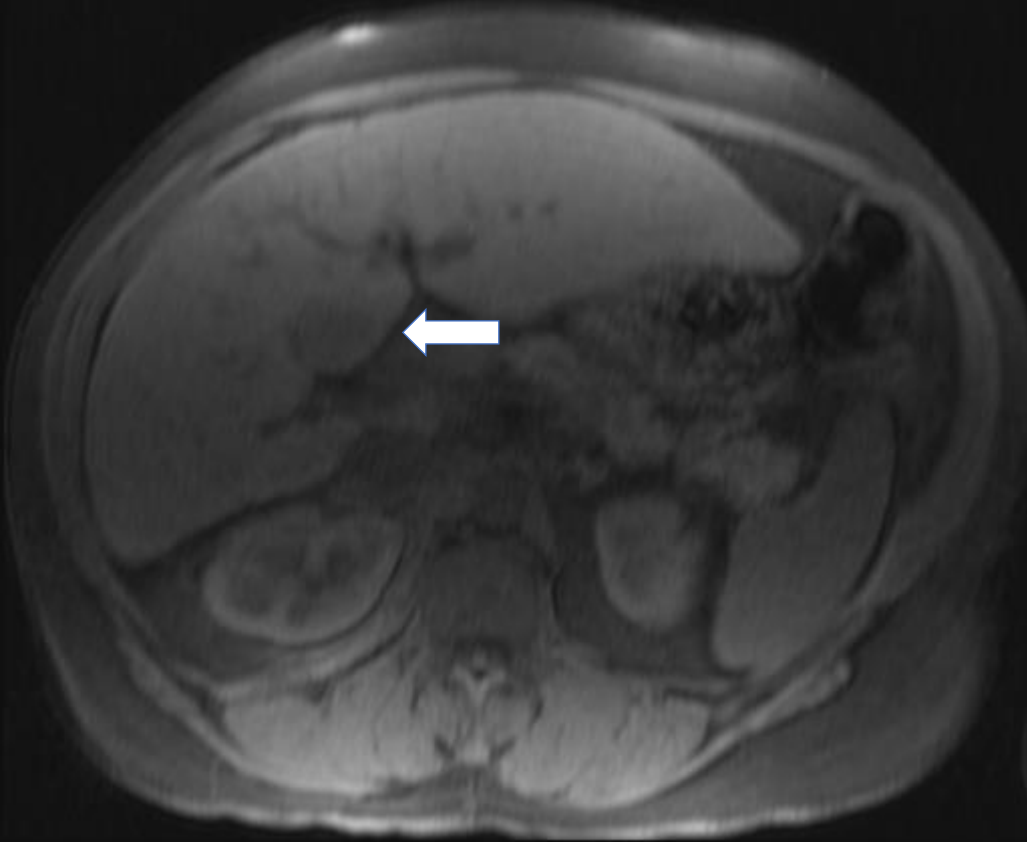
Children < 18  
Cirrhosis due to vascular etiology, cardiac disease, or congenital hepatic fibrosis

# Step-wise algorithm



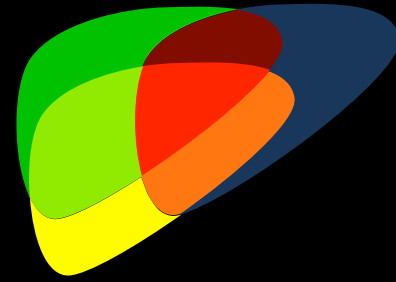
# Multiphase liver protocol



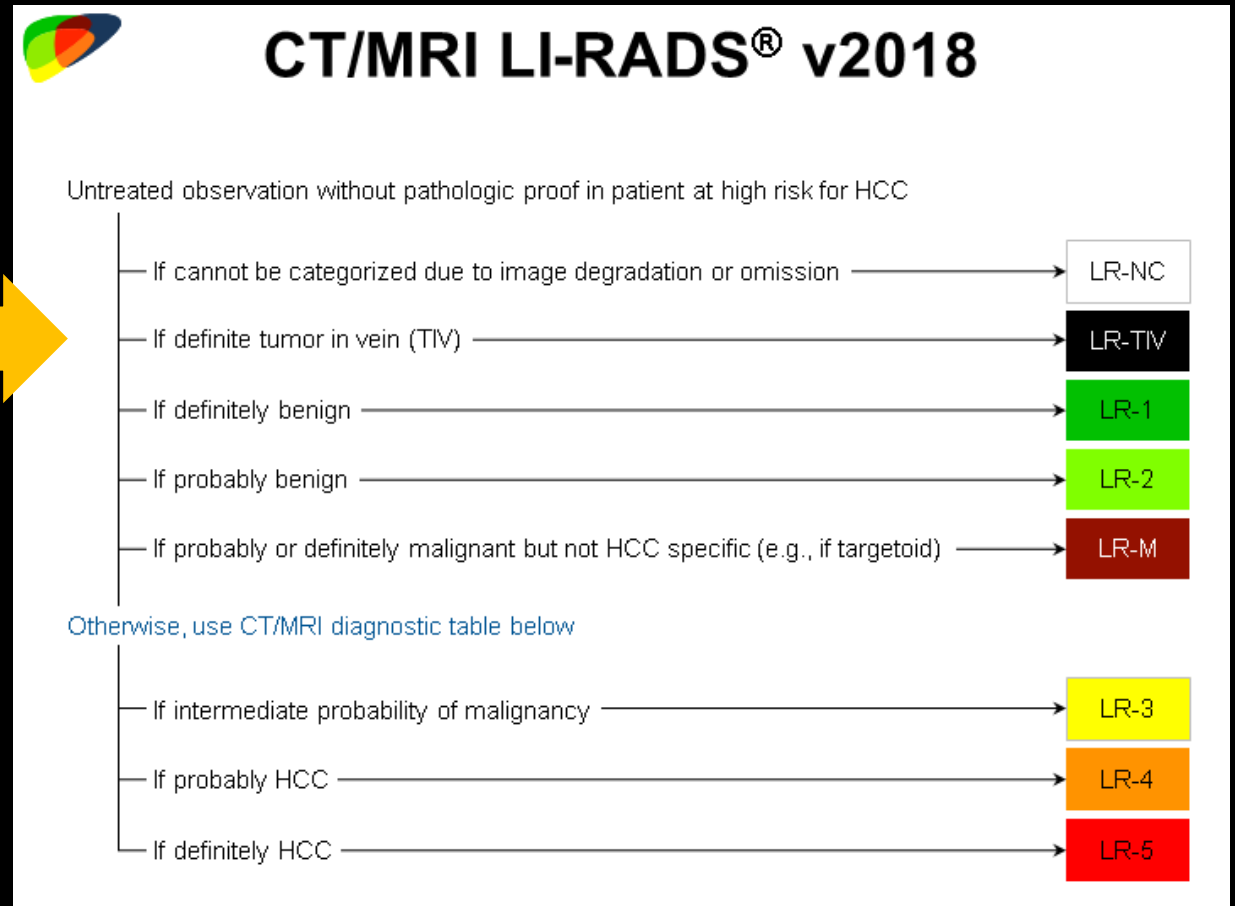
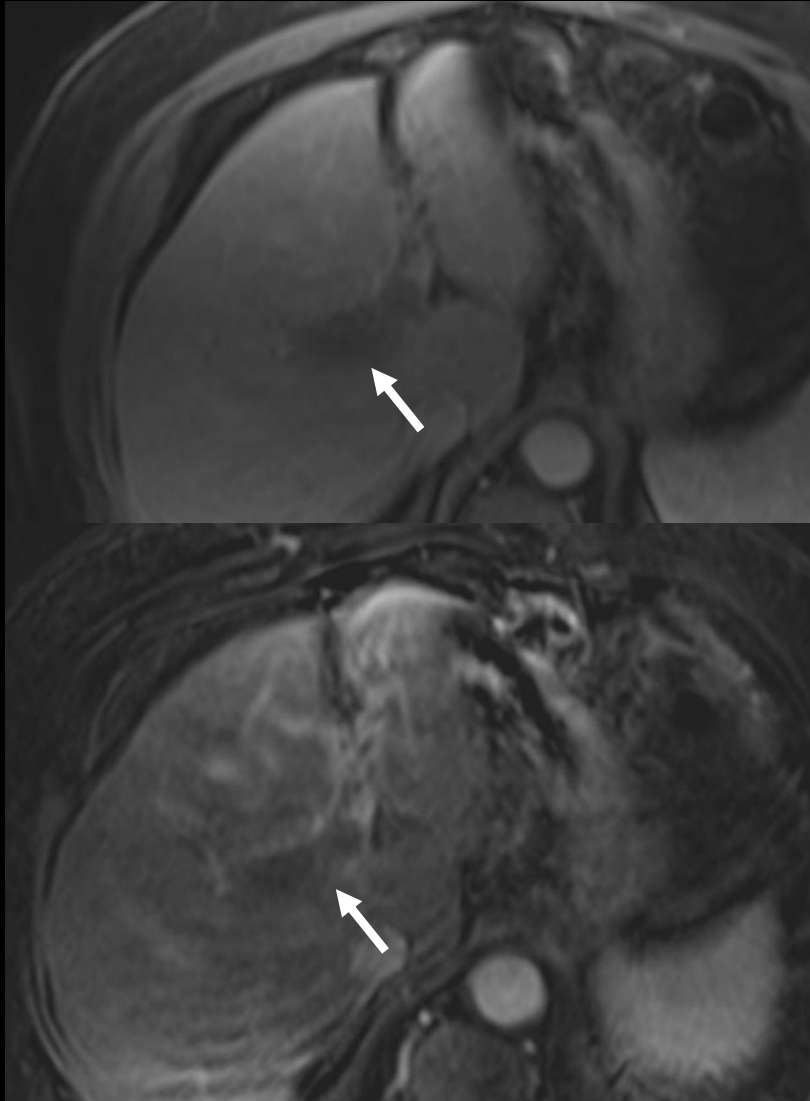


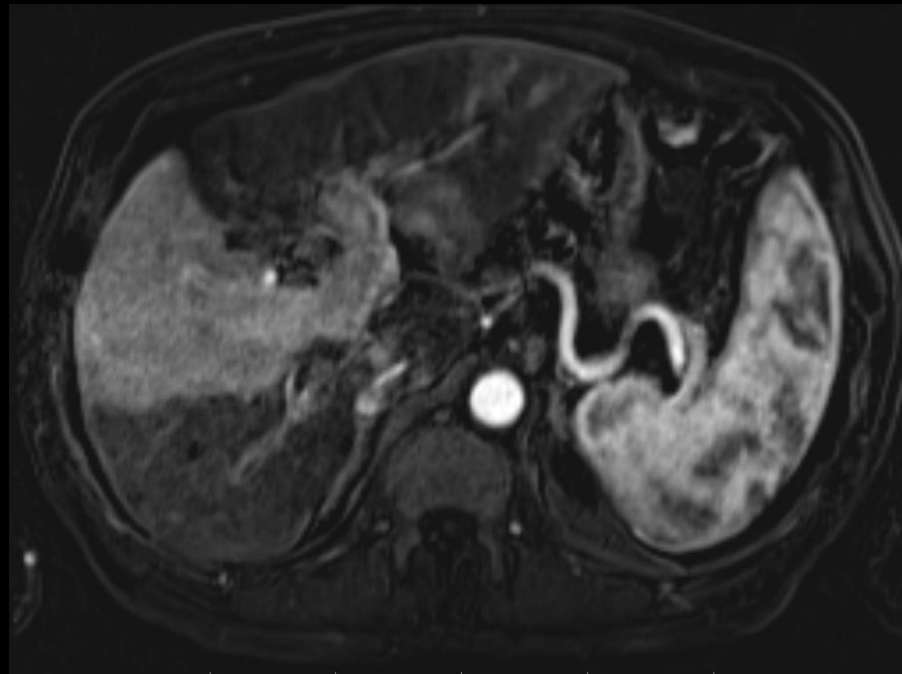
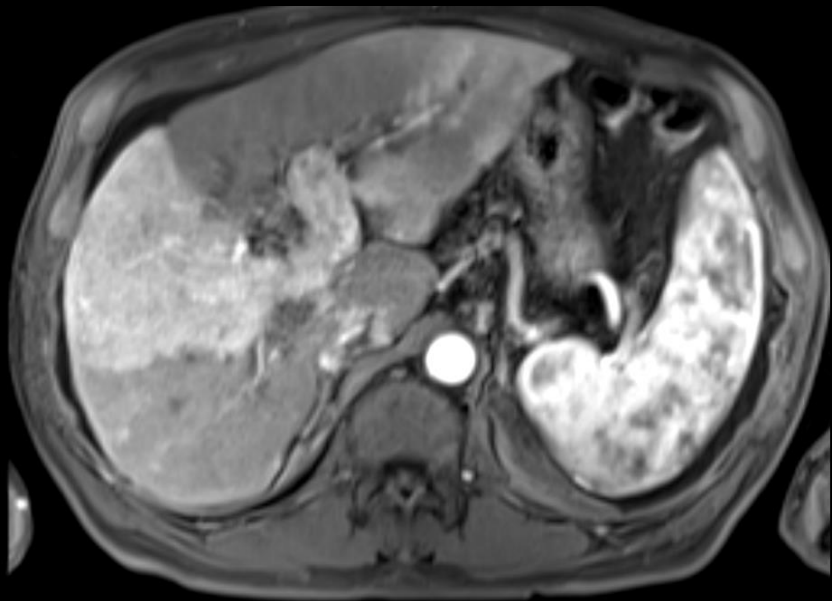
- LR-NC
- Differentiation of malignant from benign observations cannot be made
- Possible categories range from LR-1/2 to LR-4/5 or M

# Step-wise algorithm

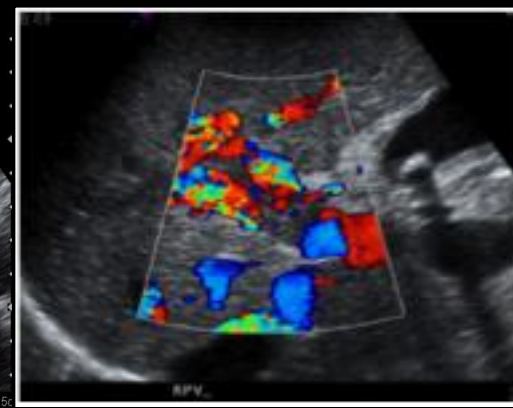
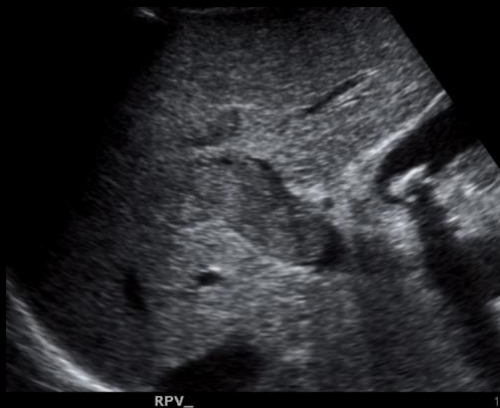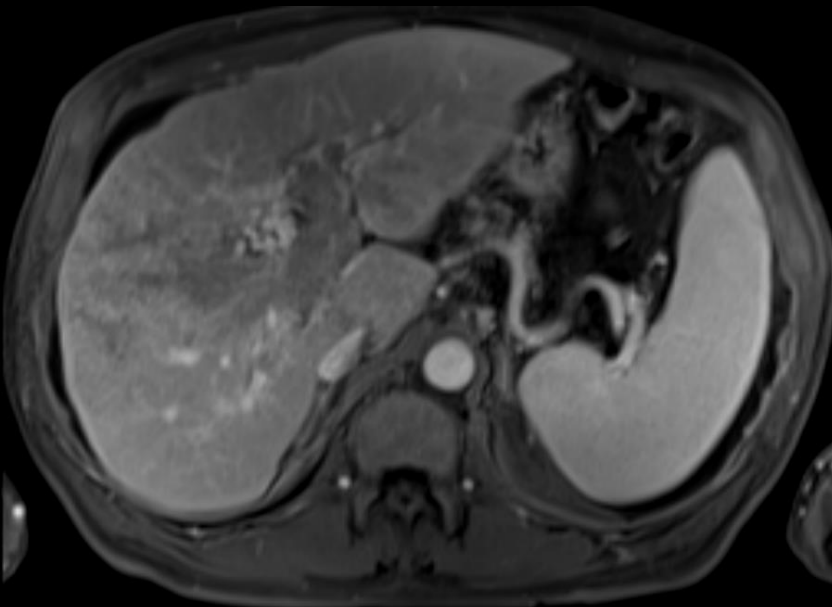


Unequivocal enhancing soft tissue in vein





## Tumor in Vein



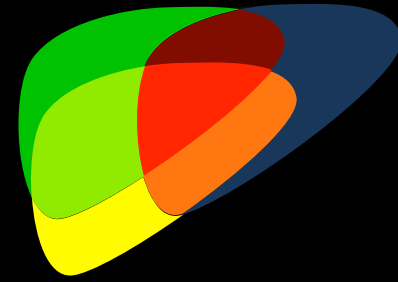
RPV\_

15c

RPV\_



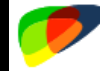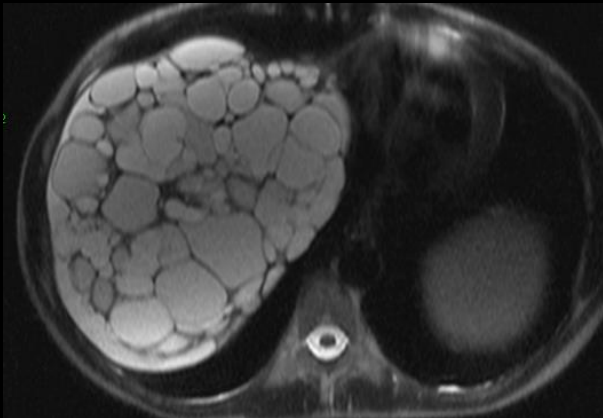
# Step 3-Rule out Benign disease



LR-1: Definitely Benign

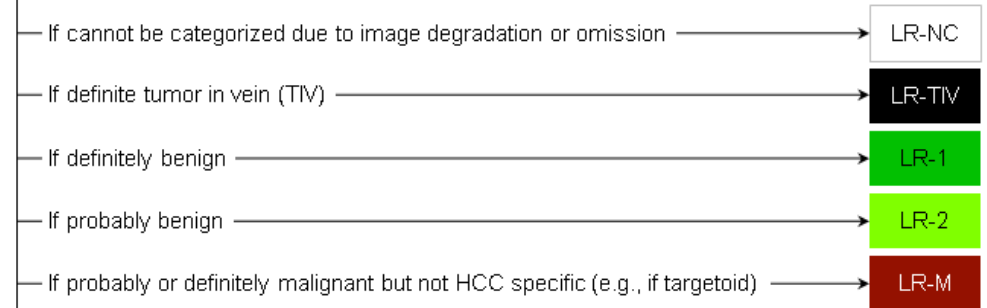
LR-2: Probably Benign

- Cysts, hemangiomas, cirrhotic nodules, focal fat, perfusion abnormalities

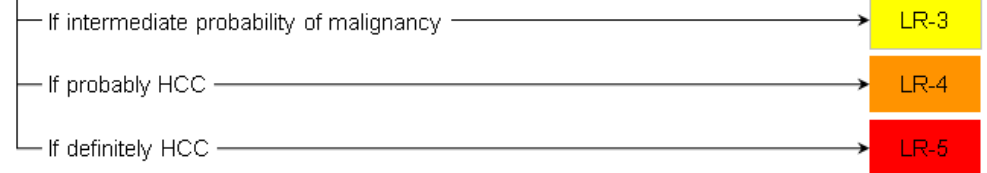


## CT/MRI LI-RADS® v2018

Untreated observation without pathologic proof in patient at high risk for HCC

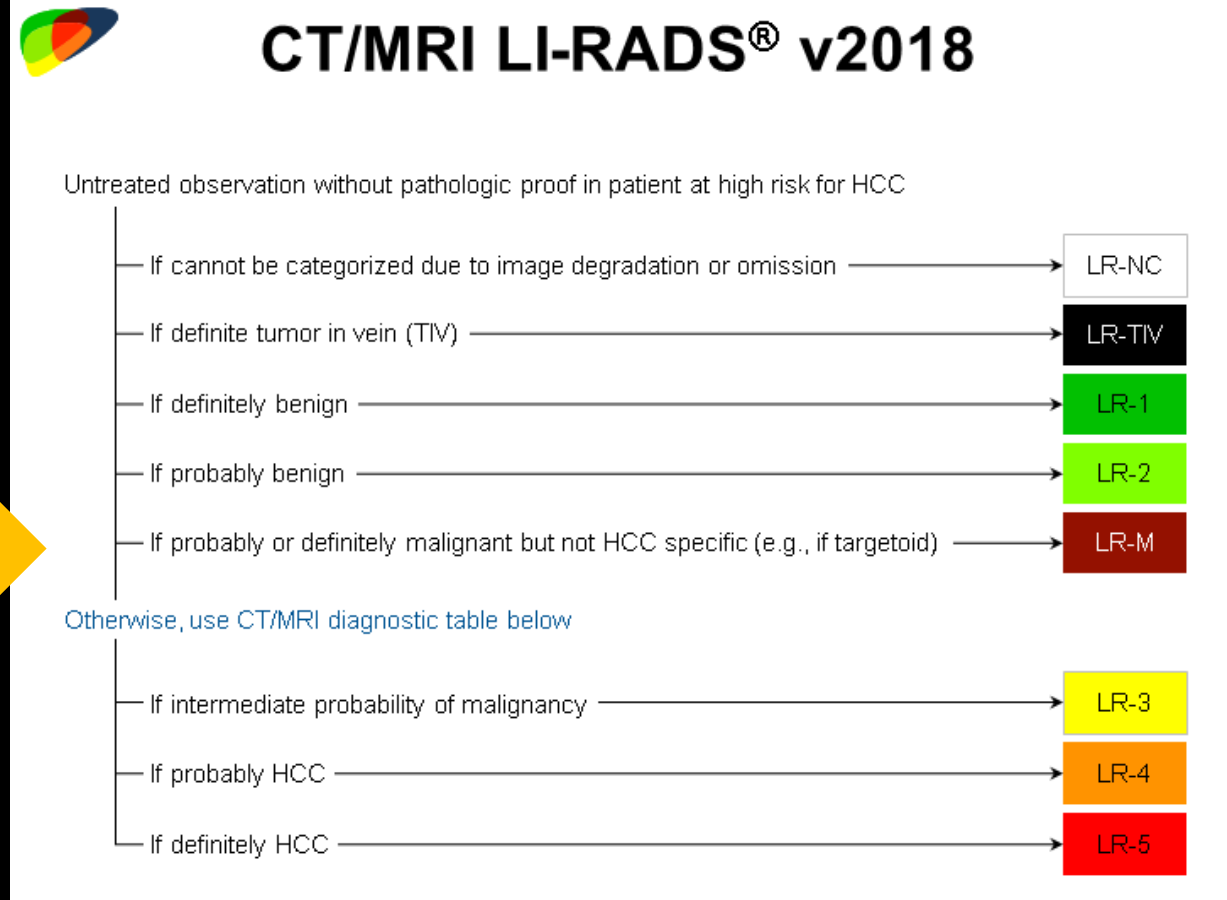

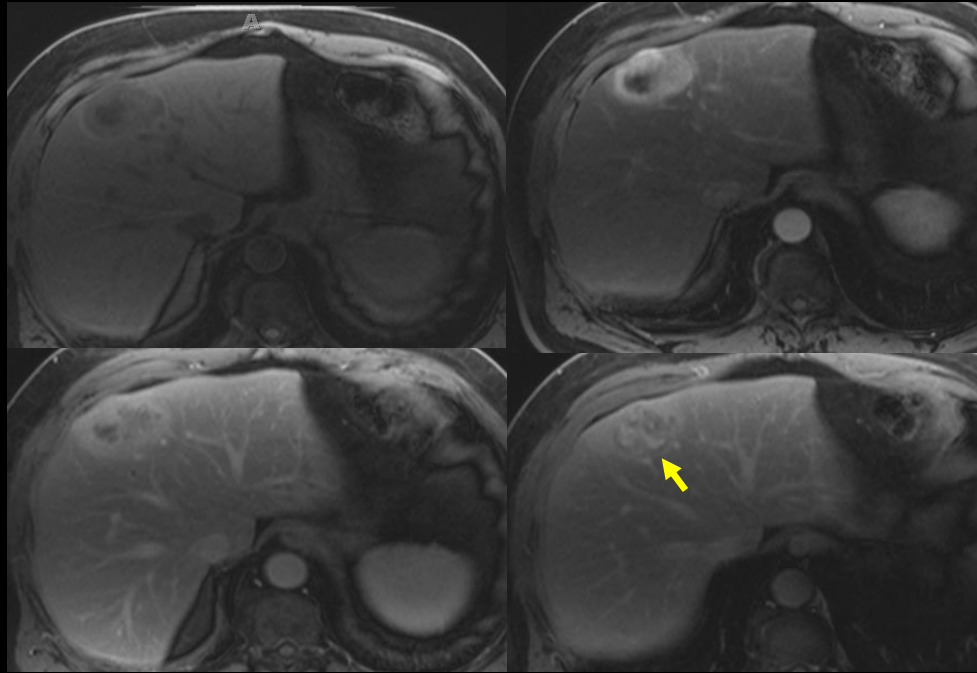
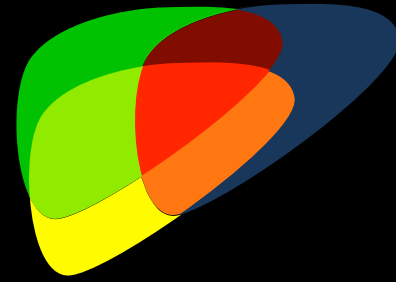


Otherwise, use CT/MRI diagnostic table below



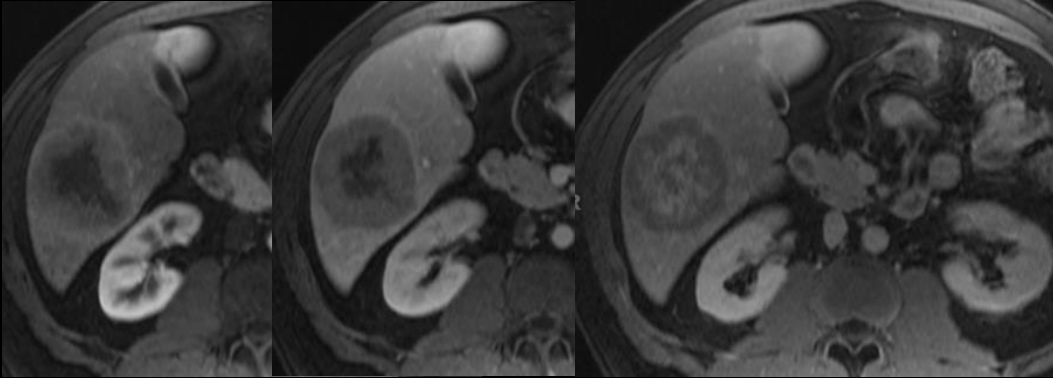


# Step-wise algorithm

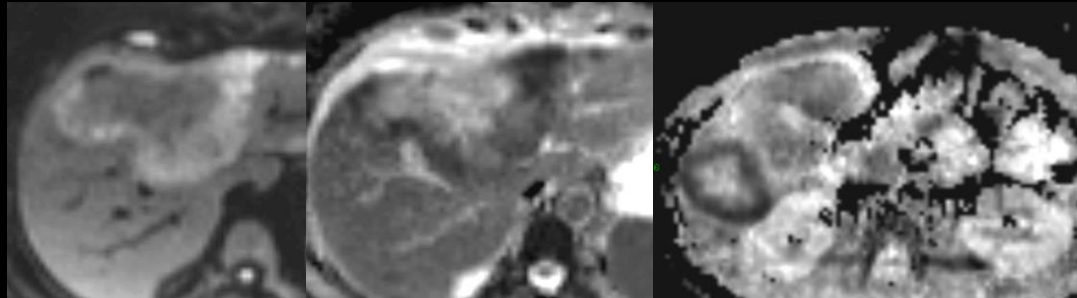


**LR-M: Probably or definitely malignant, not HCC specific**

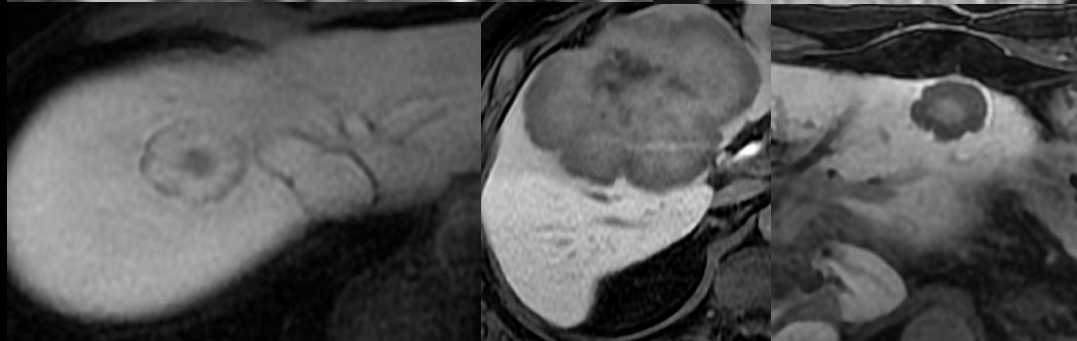
# Targetoid Features



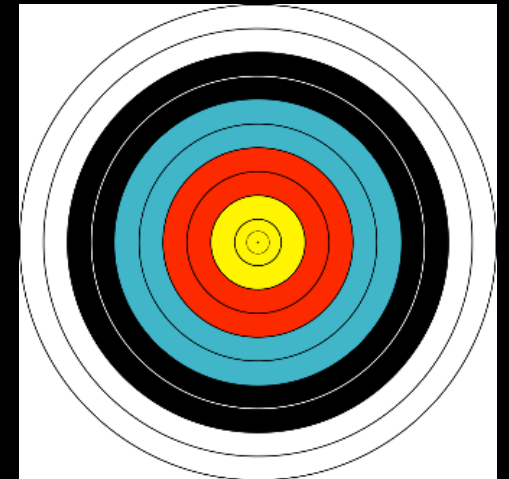
Targetoid dynamic  
enhancement pattern



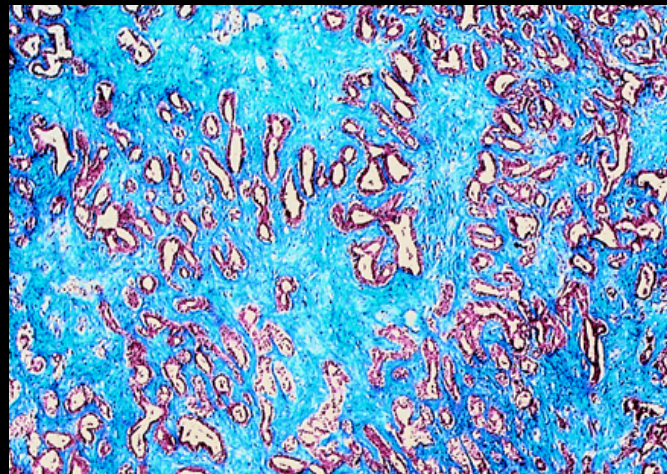
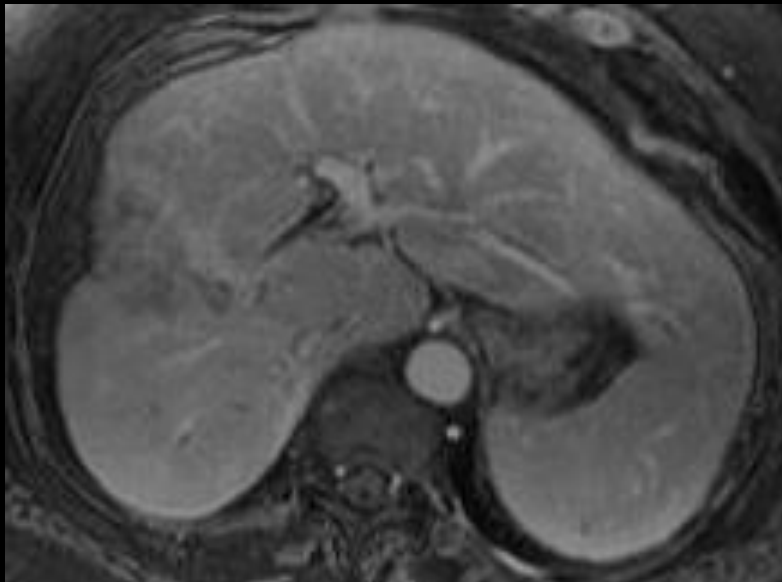
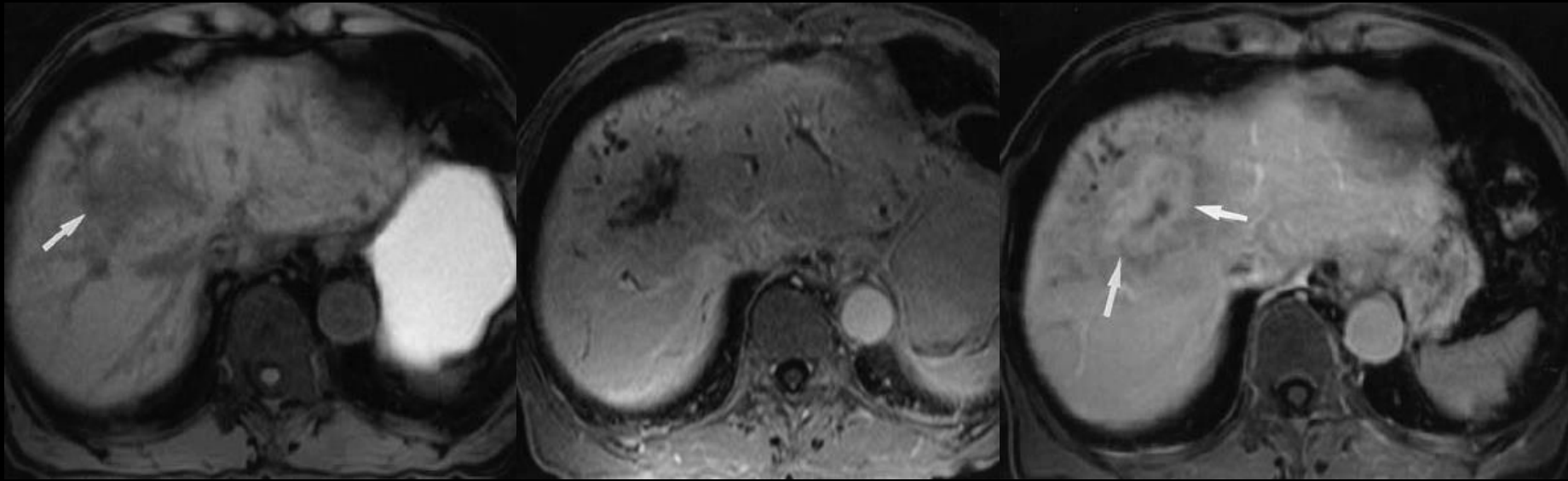
Targetoid DWI



Targetoid HBP



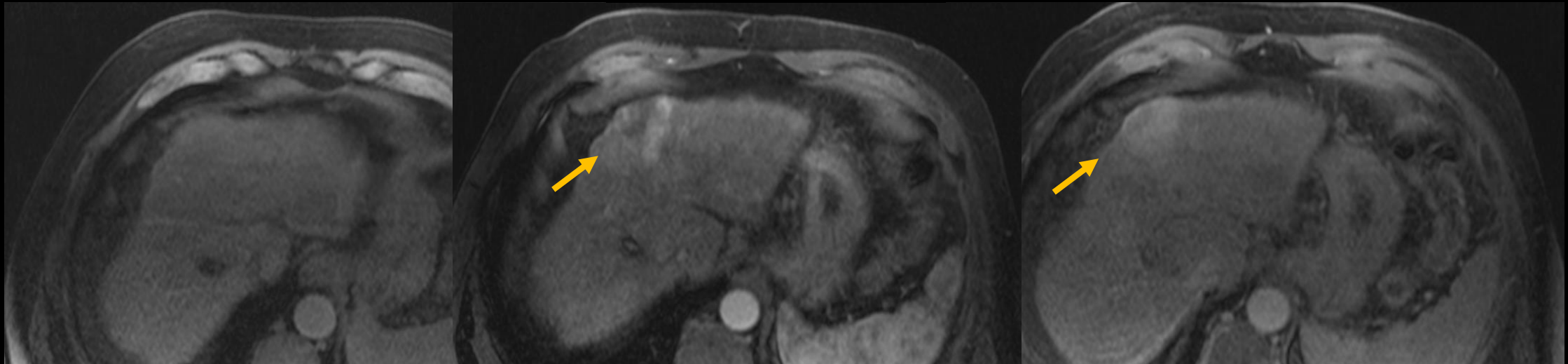

# Cholangiocarcinoma



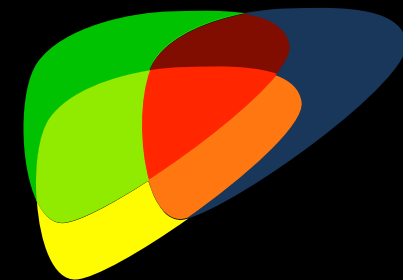
Maetani Y et al. AJR 2001;  
176:1499- 1507

# LR-M Scirrhous HCC

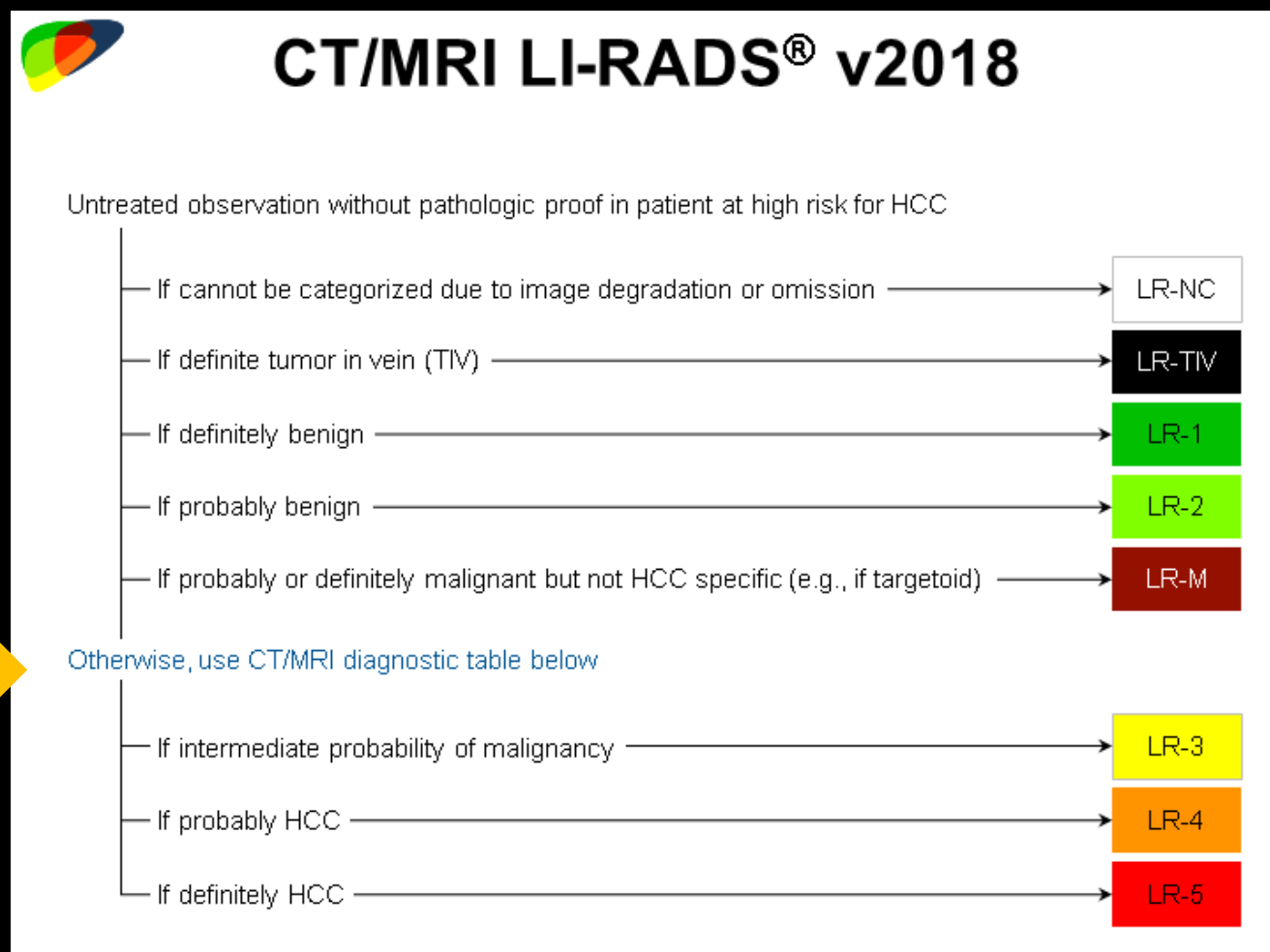

- Resembles ICC
  - Targetoid appearance and/or
  - Marked DWI
  - Fibrotic



# Step-wise process

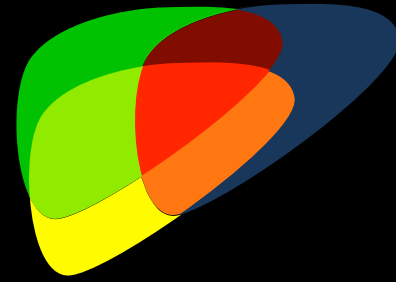


- Left with solid (hepatocellular) nodules
- Apply stringent criteria to establish diagnosis of “Definite HCC”



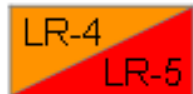

# LR Major Features-



## CT/MRI Diagnostic Table

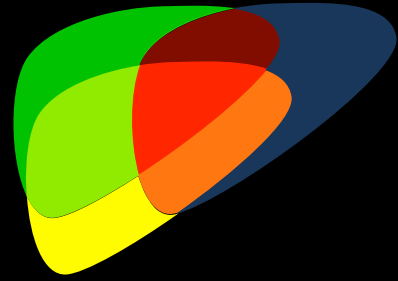
Arterial phase hyperenhancement (APHE)		No APHE		Nonrim APHE		
Observation size (mm)		< 20	≥ 20	< 10	10-19	≥ 20
Count additional major features: <ul style="list-style-type: none"> <li>• Enhancing "capsule"</li> <li>• "Nonperipheral "washout"</li> <li>• Threshold growth</li> </ul>	None	LR-3	LR-3	LR-3	LR-3	LR-4
	One	LR-3	LR-4	LR-4	LR-4 / LR-5	LR-5
	≥ Two	LR-4	LR-4	LR-4	LR-5	LR-5



Observations in this cell are categorized based on one additional major feature:

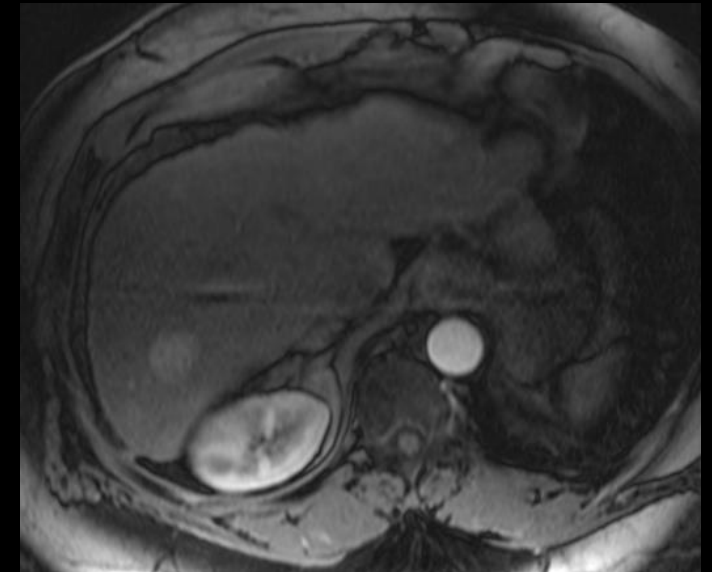
- LR-4 – if enhancing "capsule"
- LR-5 – if nonperipheral "washout" **OR** threshold growth

# LR-3: Criteria

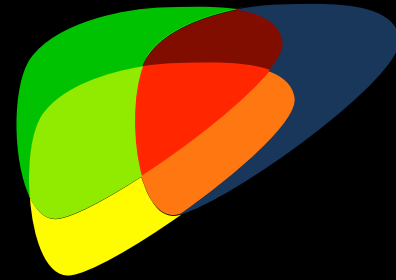


## LR-3: Intermediate

- Intermediate probability of HCC or malignancy
- < 20 mm single MF or Afs
- Tie breaking rules

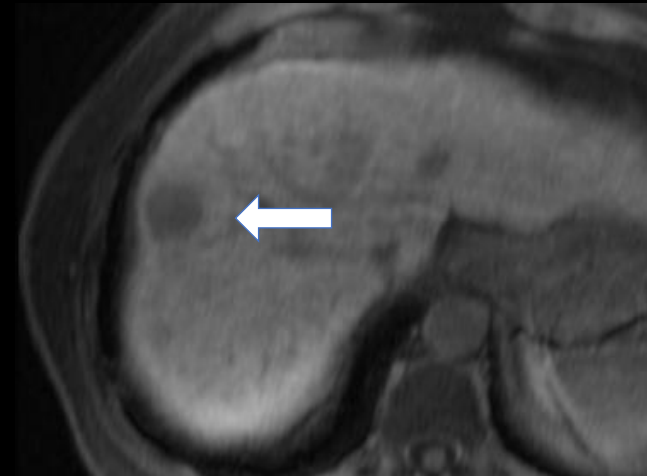


# LR-4: Criteria



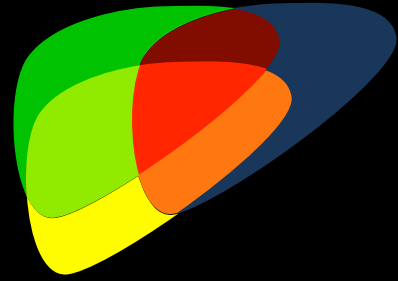
## LR-4: Probably HCC

- Unequivocal features
  - 10-19 mm: non-rim APHE + Capsule
  - $\geq 20$  mm: non-rim APHE
  - No APHE, but Capsule, WO, or TG
- Tie breaking rules LR-5 becomes LR-4



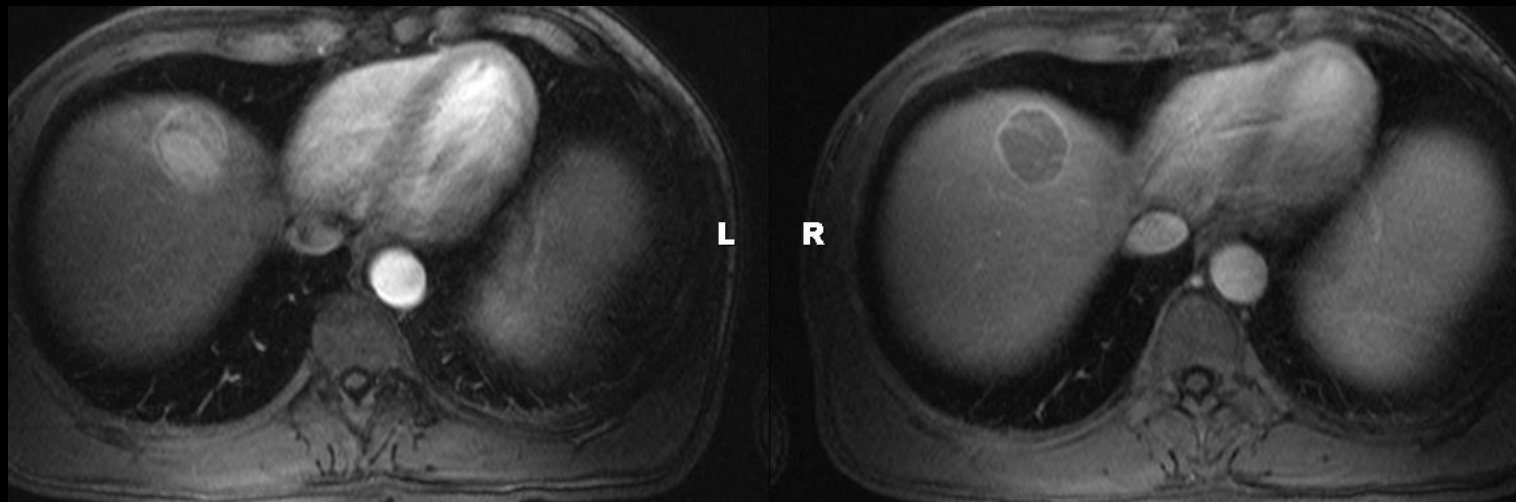


# LR-5: Criteria



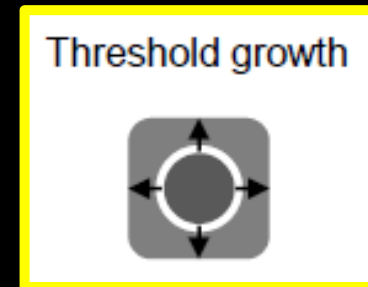
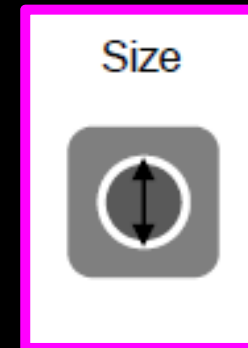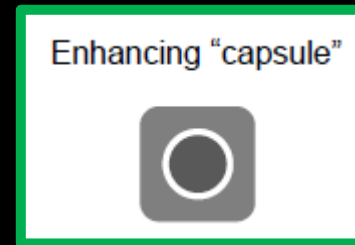
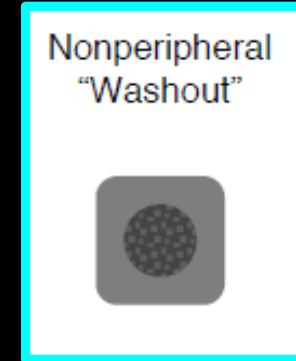

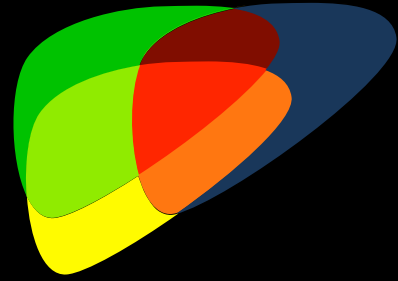
## LR-5: Definitely HCC

- Unequivocal features
  - 10-19 mm: non-rim APHE + WO or APHE + TG
  - $\geq 20$  mm: non-rim APHE + WO, or APHE + Capsule, or APHE + TG

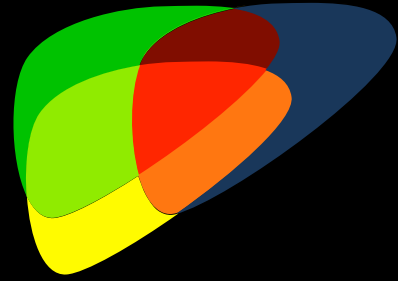


# Major Features

- Nonrim APHE
- Nonperipheral washout appearance
- Enhancing capsule appearance
- Size
- Threshold growth



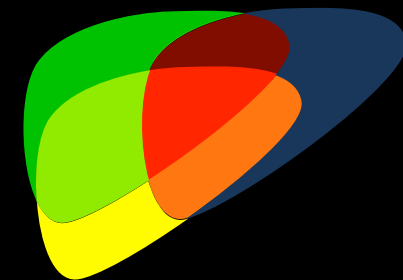
# Rules of the Game



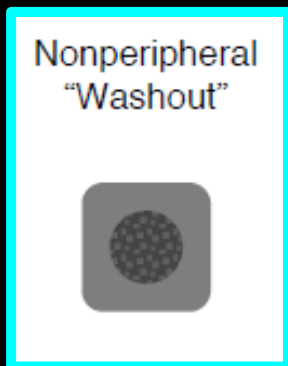

- Major Features must be unequivocally present
- When in doubt-throw it out!



# Rules of the Game



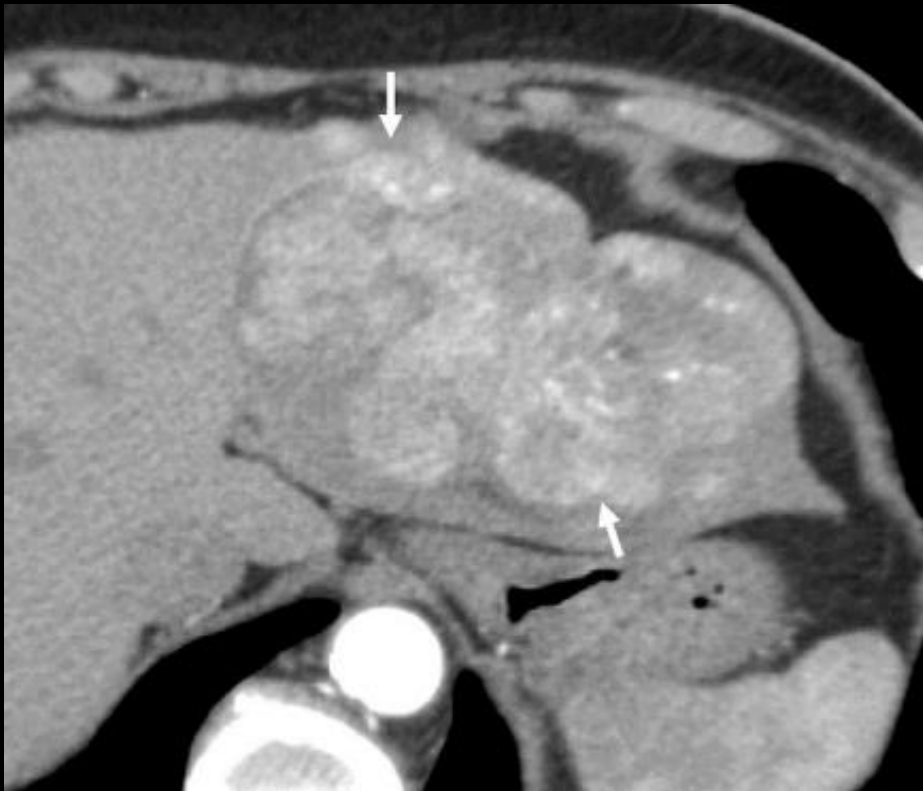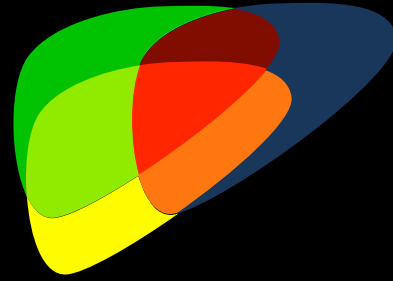
- Major Features must be differentiated from LR-M Features



Nonrim APHE



# Nonrim APHE

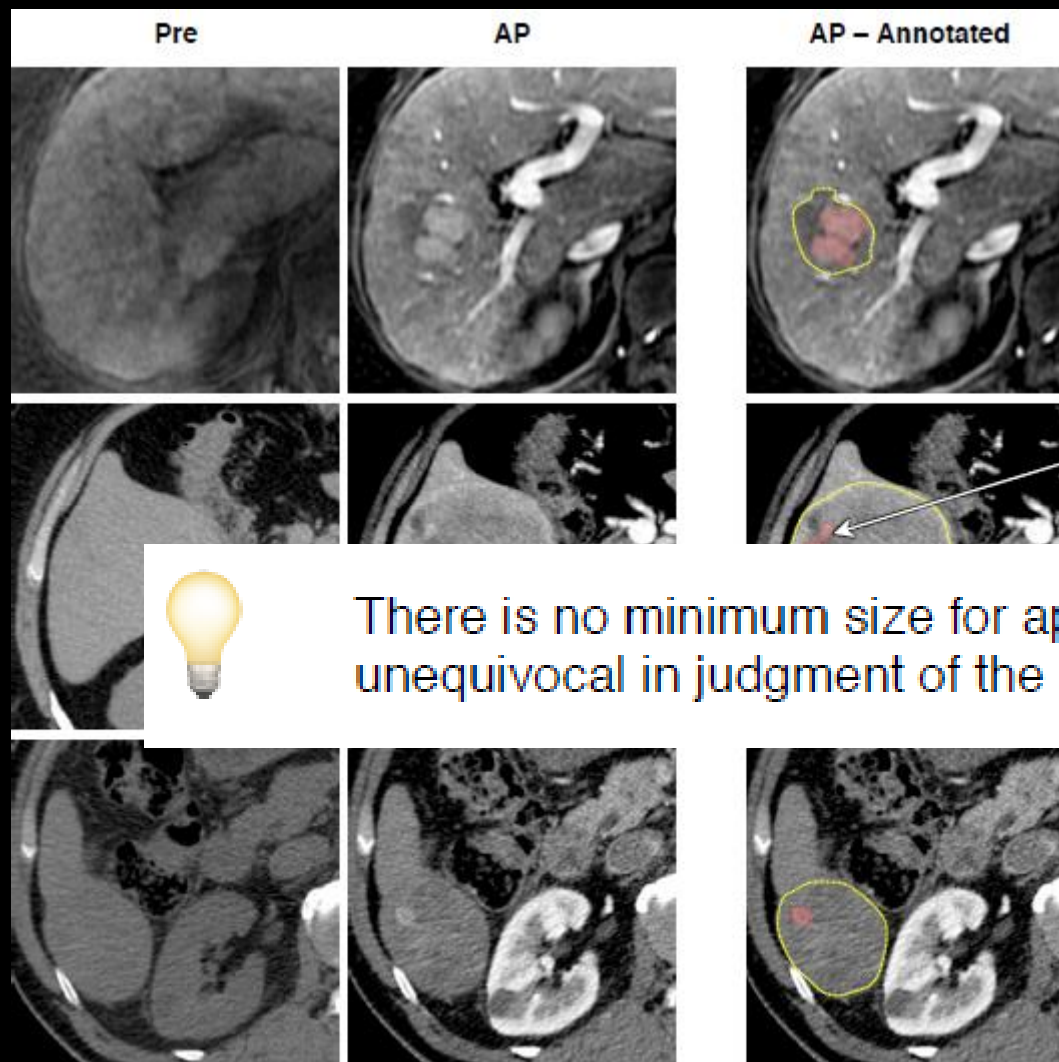
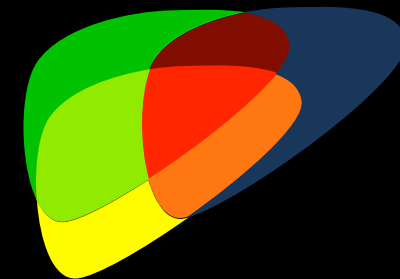


Enhancement in arterial phase  
unequivocally greater in whole or  
in part than liver and not confined  
to the rim

Nonrim APHE



# Nonrim APHE



In whole or in part

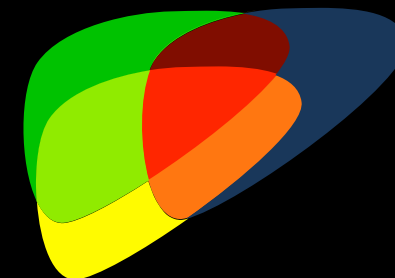


There is no minimum size for application of APHE, rather its presence should be unequivocal in judgment of the radiologist.

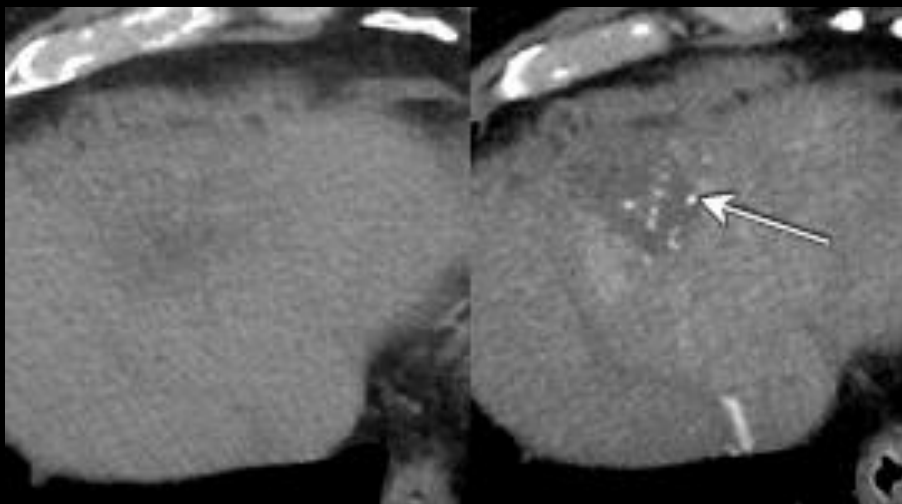
Nonrim APHE




# Nonrim APHE



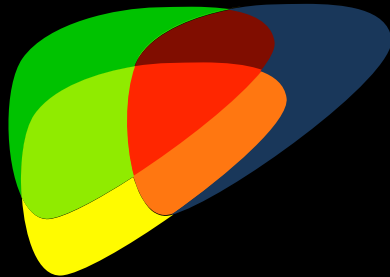
Scattered or patchy



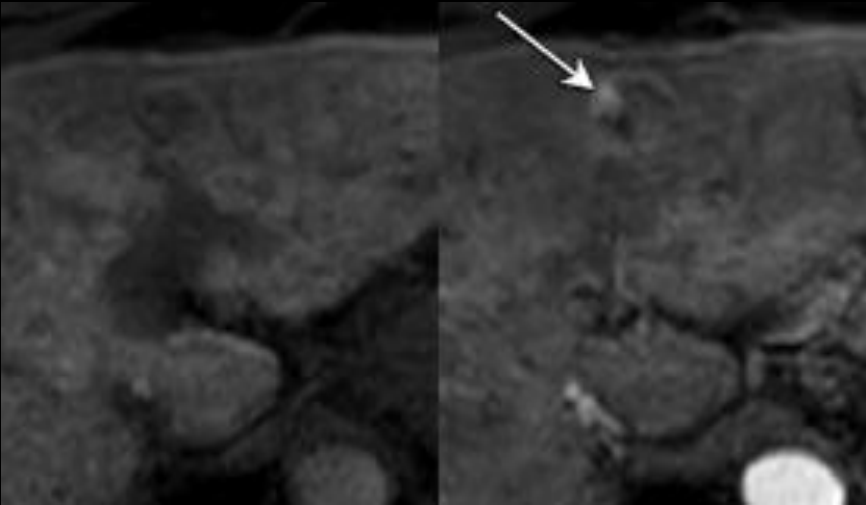
	Pre	AP
Diffuse, homogeneous		
Diffuse, heterogeneous		
Scattered (patchy, spotty)		
Nodule in nodule		
Mosaic		



# Nonrim APHE



## Nodule-in-nodule



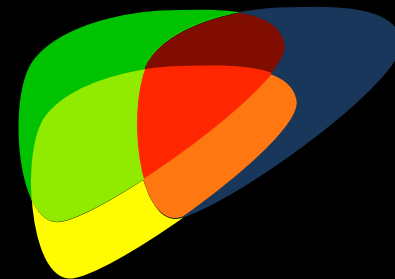
	Pre	AP
Diffuse, homogeneous		
Diffuse, heterogeneous		
Scattered (patchy, spotty)		
Nodule in nodule		
Mosaic		



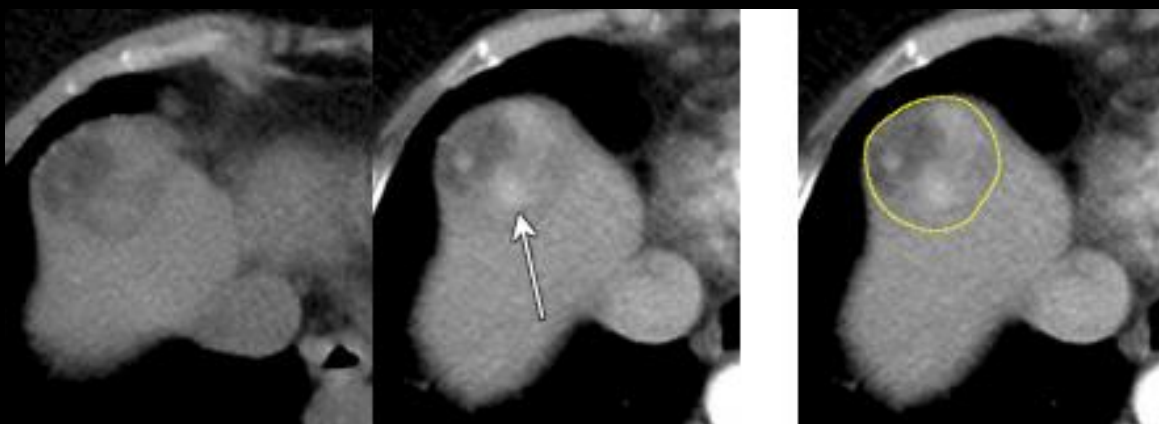Nonrim APHE



# Nonrim APHE




## Mosaic

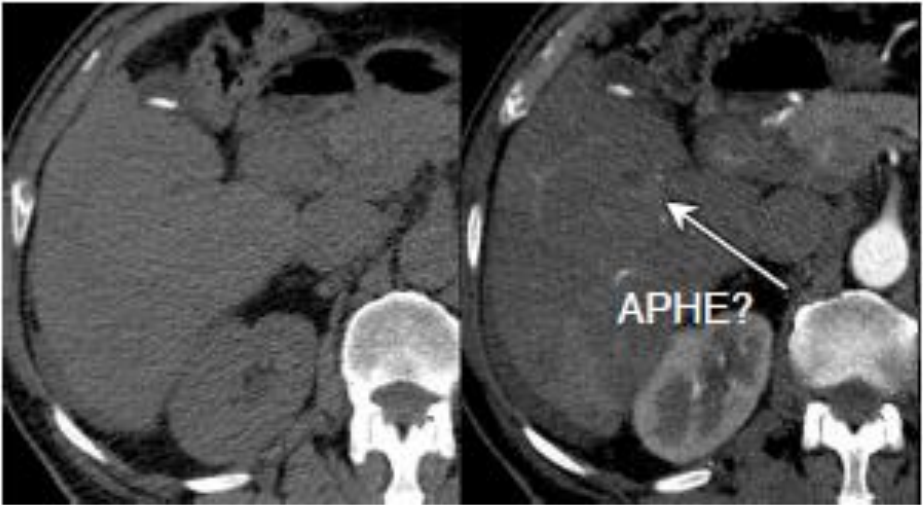


	Pre	AP
Diffuse, homogeneous		
Diffuse, heterogeneous		
Scattered (patchy, spotty)		
Nodule in nodule		
Mosaic		

# Is it unequivocally present?

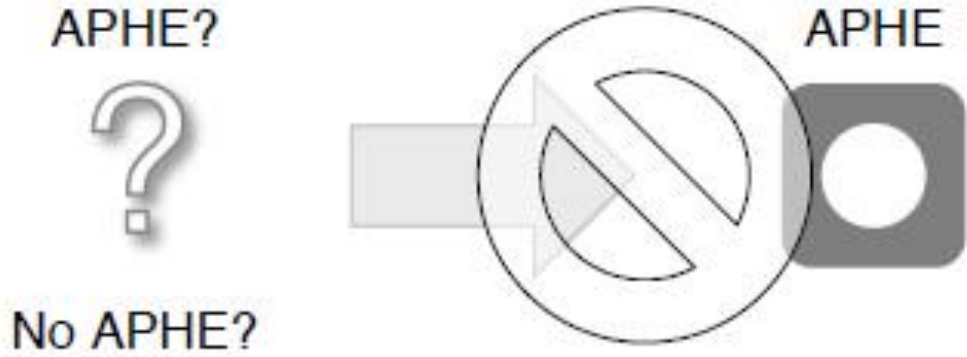


Pre AP

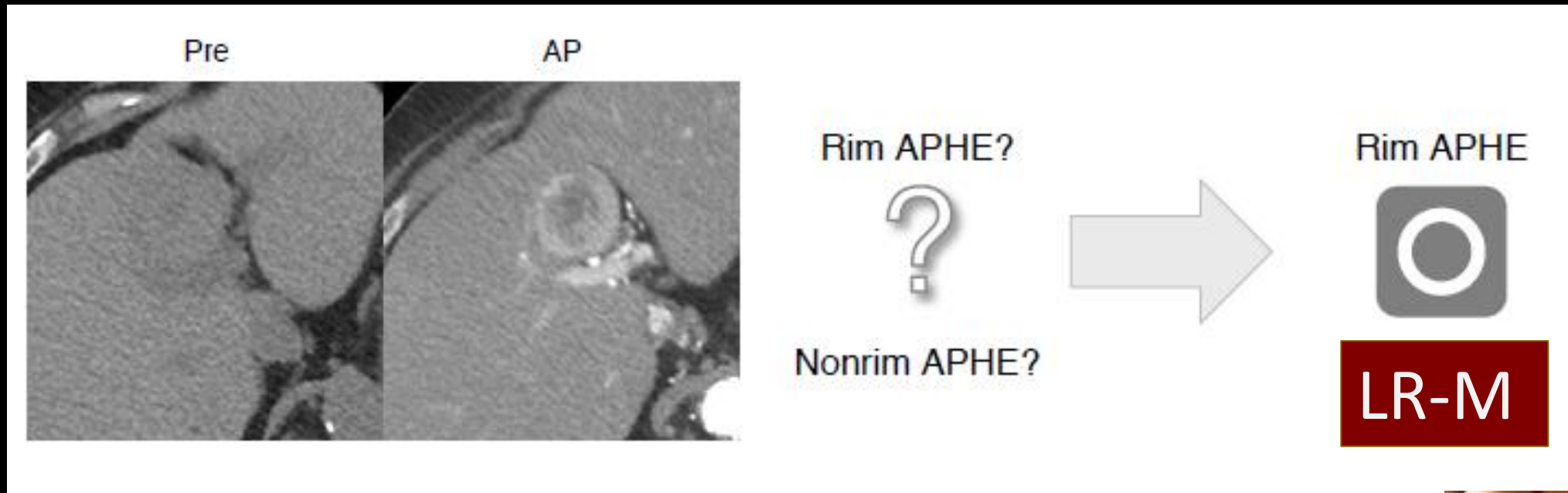
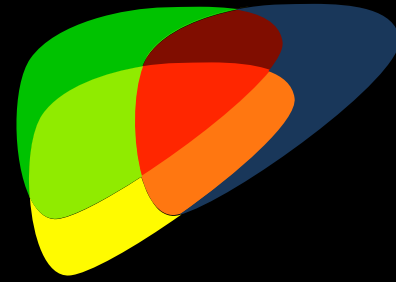


APHE?

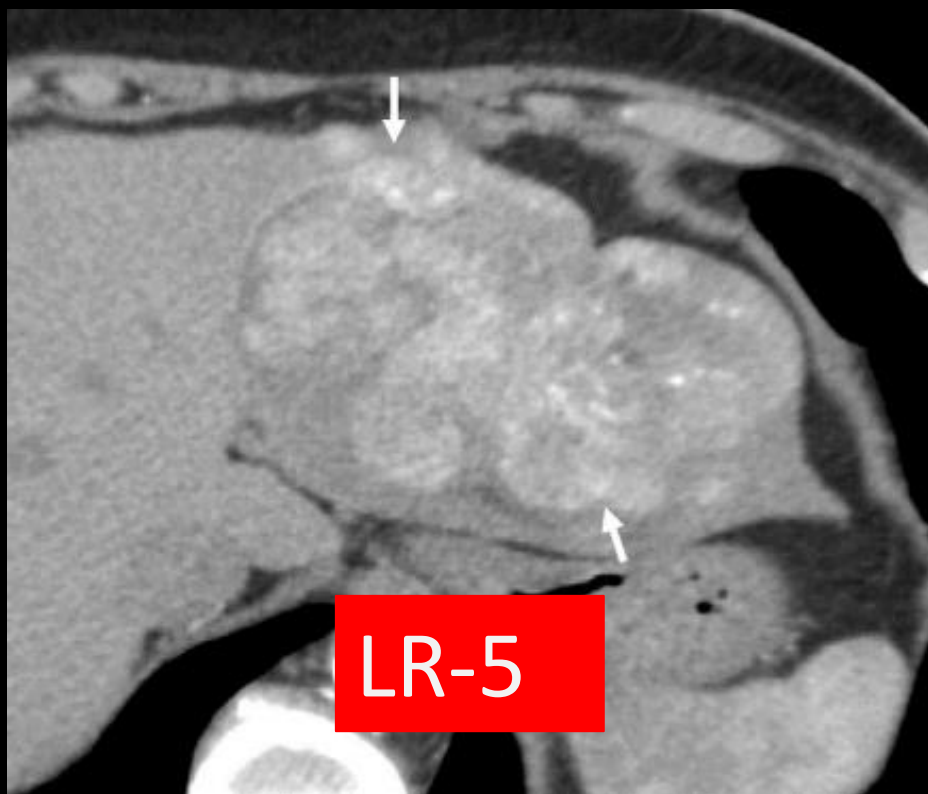
No APHE?



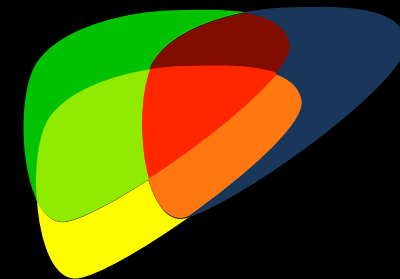
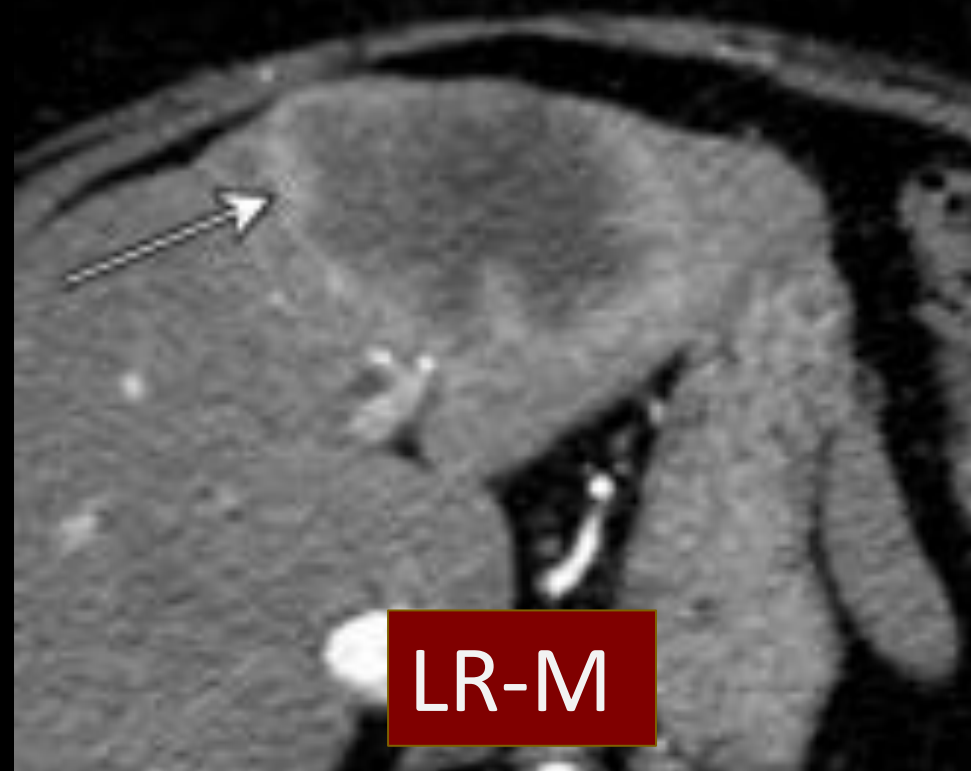
# Major Feature versus LR-M Feature?



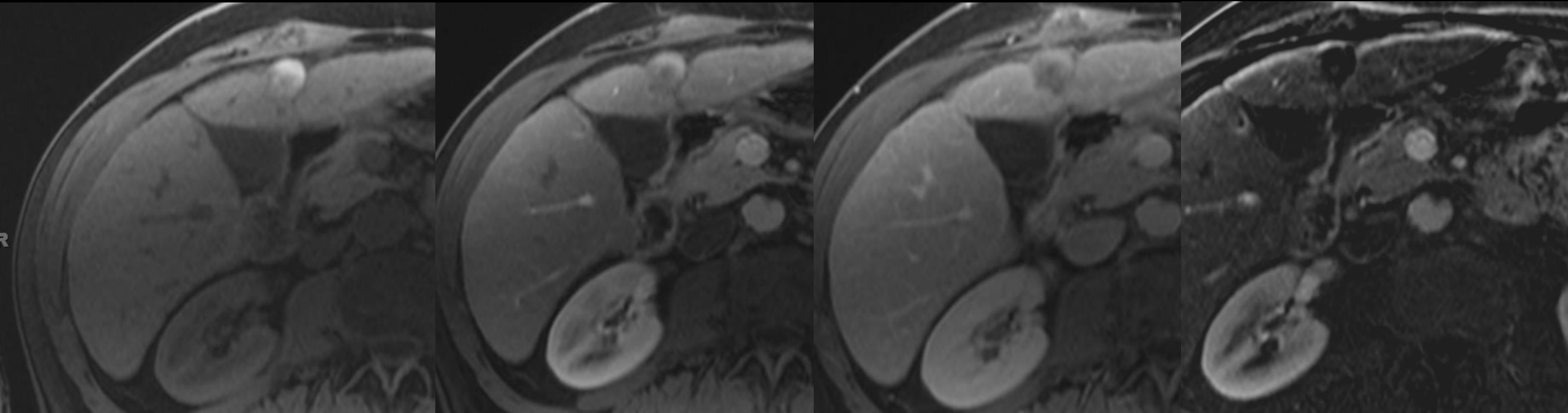
# Nonrim APHE



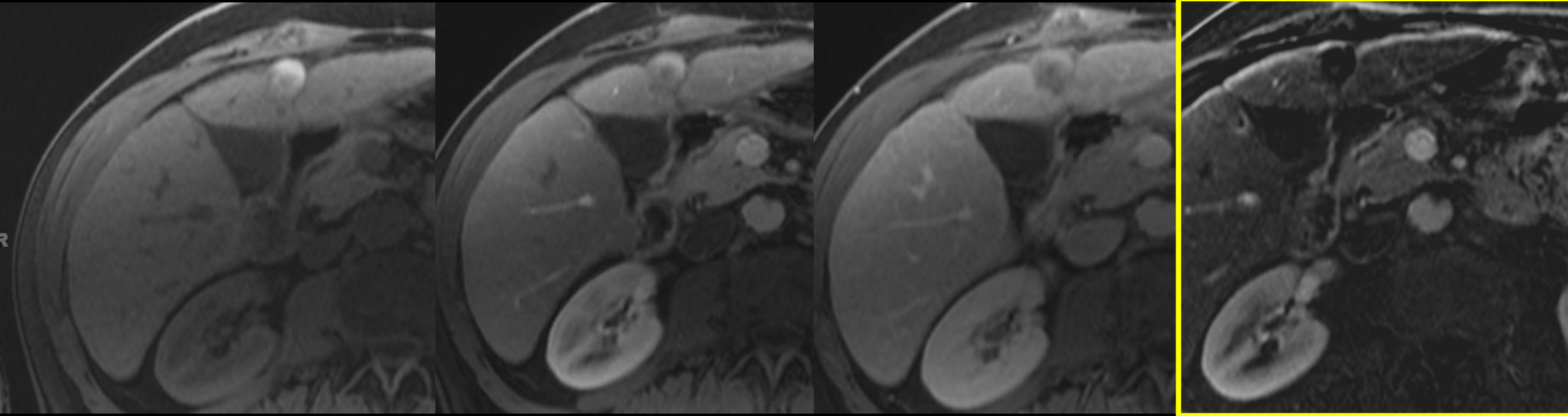
# Rim APHE



Case 1 Does this lesion show APHE?




# Case 1



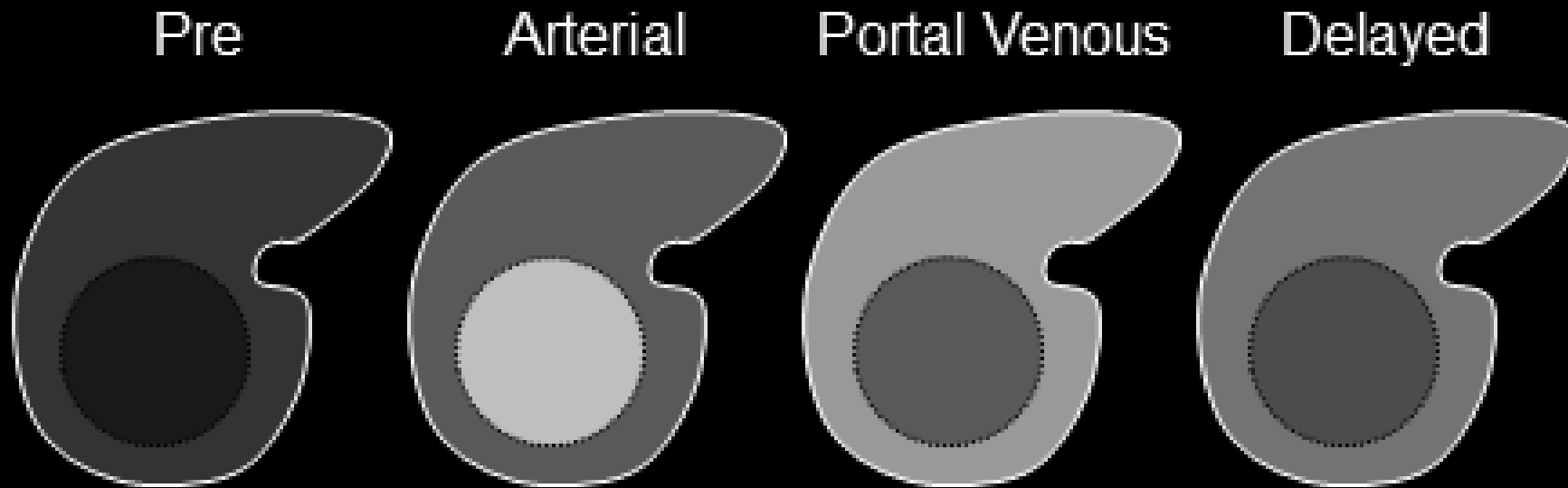
**No**

The mass is intrinsically T1 hyperintense due to blood products (an ancillary feature) and on subtraction images there is no APHE

# “Washout”

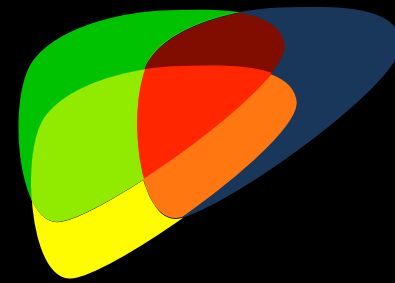


Temporal reduction in enhancement in whole or in part relative to composite liver tissue from earlier to later phase resulting in hypoenhancement in postarterial EC phase





# “Washout”

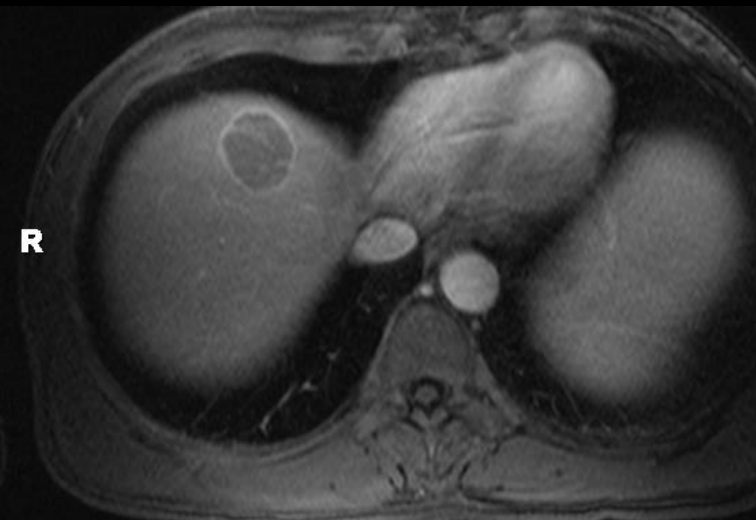
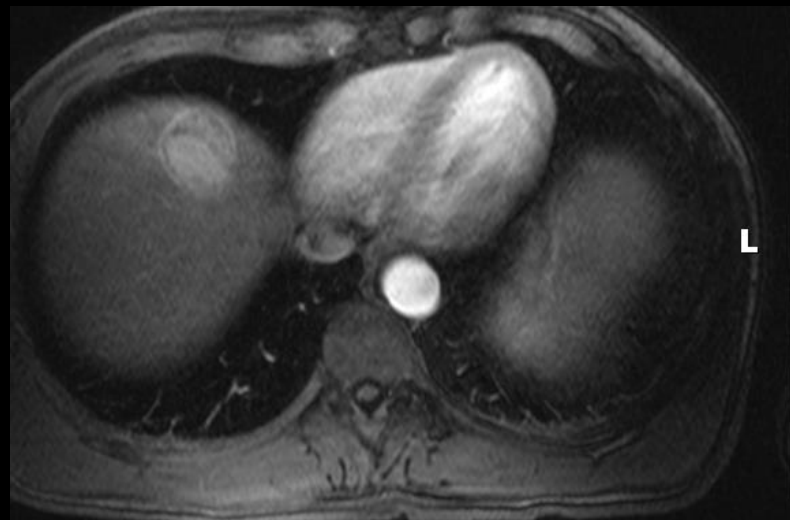



Pre

Arterial

Portal Venous

Delayed

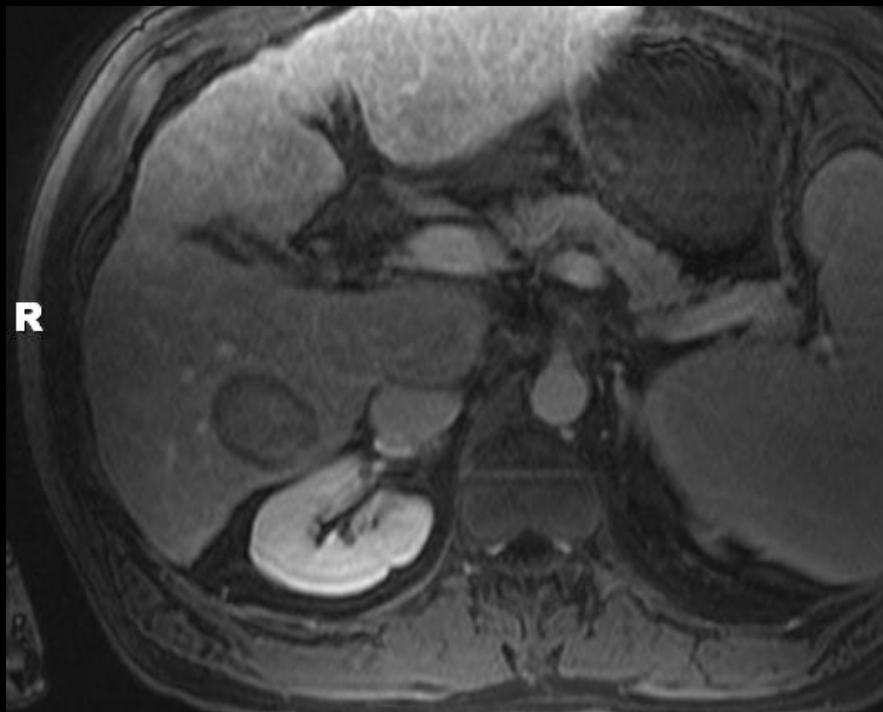
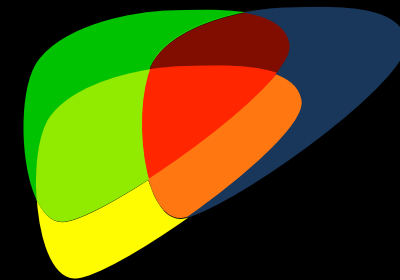




Nonperipheral  
"Washout"



# Nonperipheral "Washout"

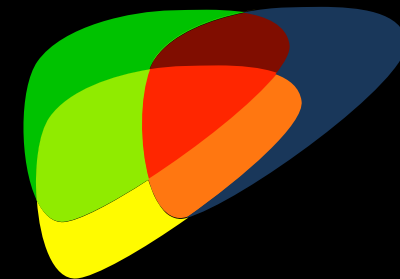


Washout that is **NOT** most pronounced  
in observation periphery


Nonperipheral  
"Washout"



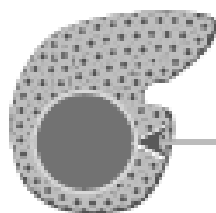
# Nonperipheral "Washout"



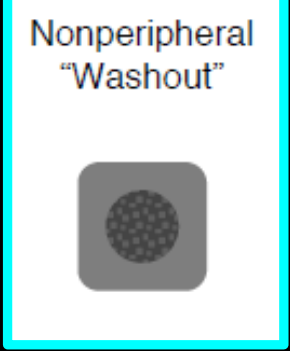AP




ECP



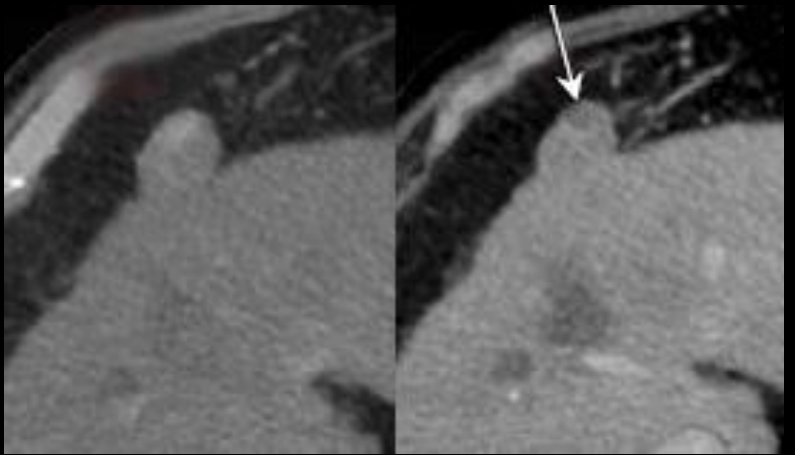
Darker than composite background liver













# Nonperipheral "Washout"




## Nodule-in-Nodule



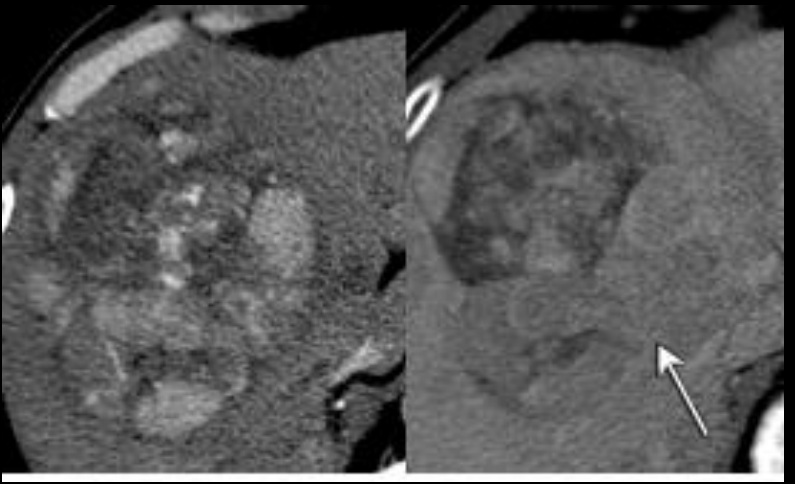
	Pre	ECP
Diffuse, homogeneous		
Diffuse, heterogeneous		
Scattered (patchy, spotty)		
Nodule in nodule		
Mosaic		



# Nonperipheral "Washout"

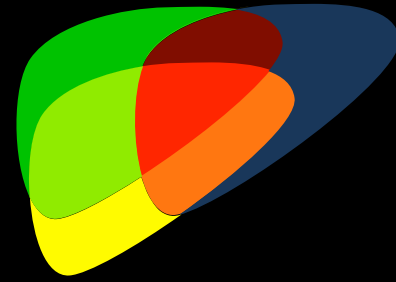


Mosaic



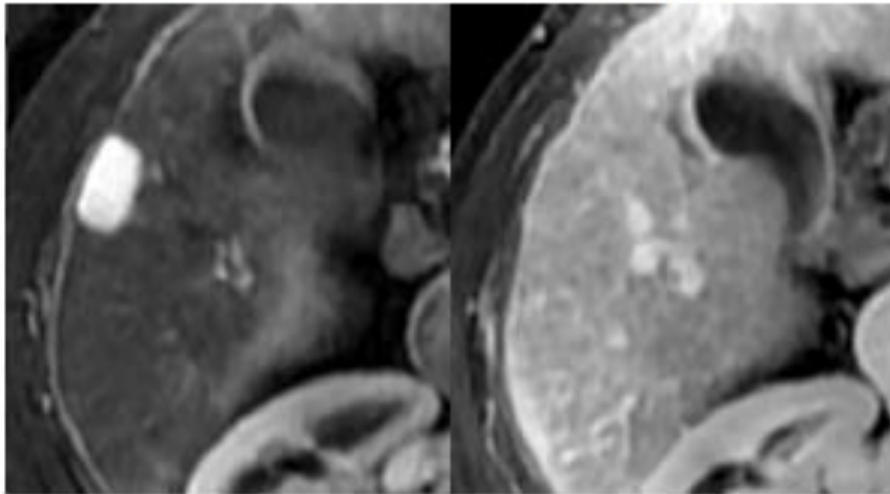
	Pre	ECP
Diffuse, homogeneous		
Diffuse, heterogeneous		
Scattered (patchy, spotty)		
Nodule in nodule		
Mosaic		

# Is it unequivocally present?



AP

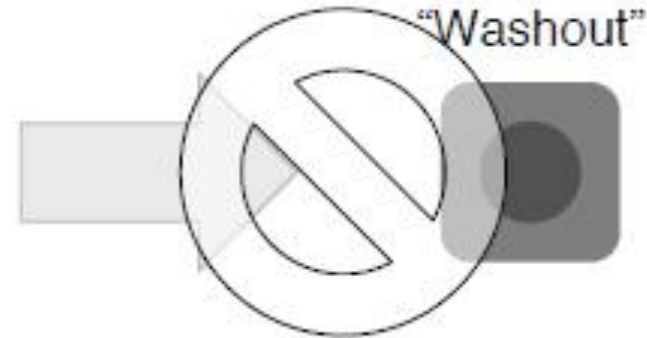PVP



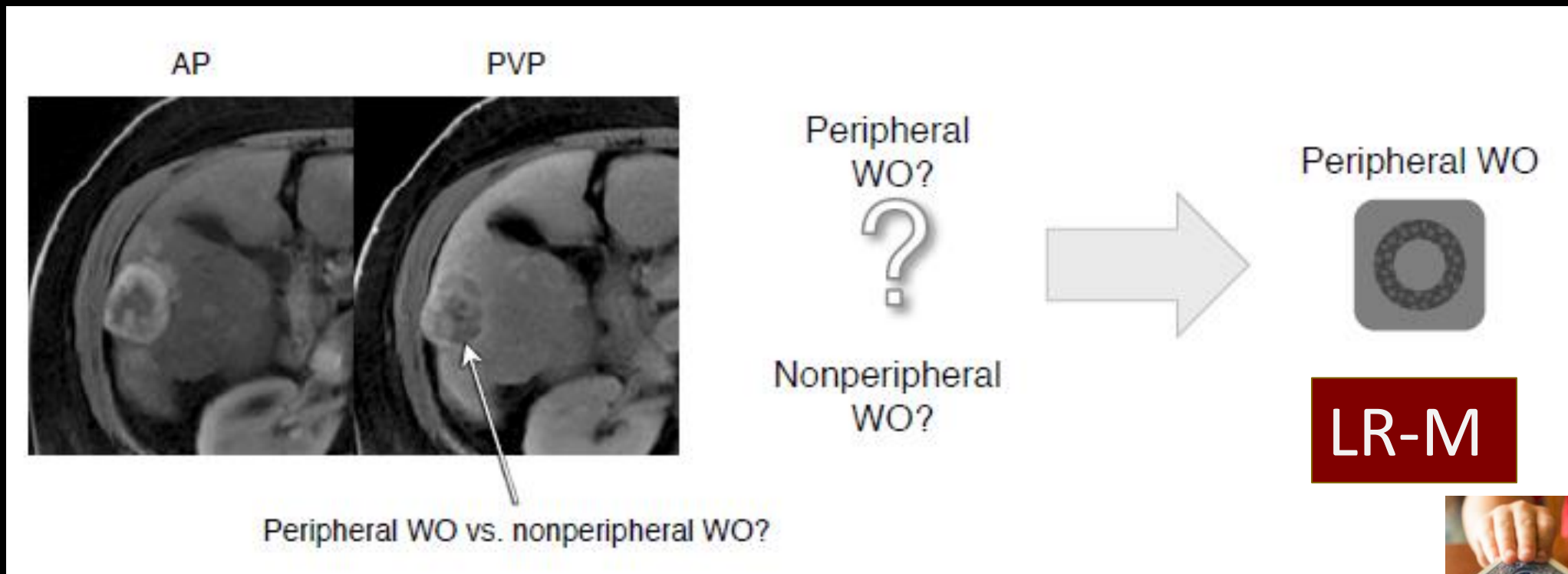
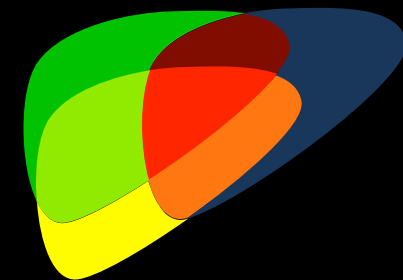
“Washout”?

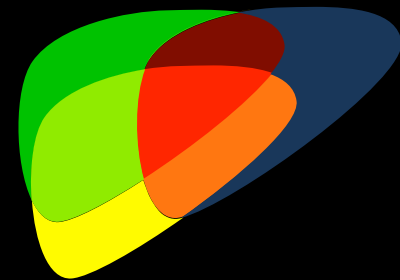


No “washout”?

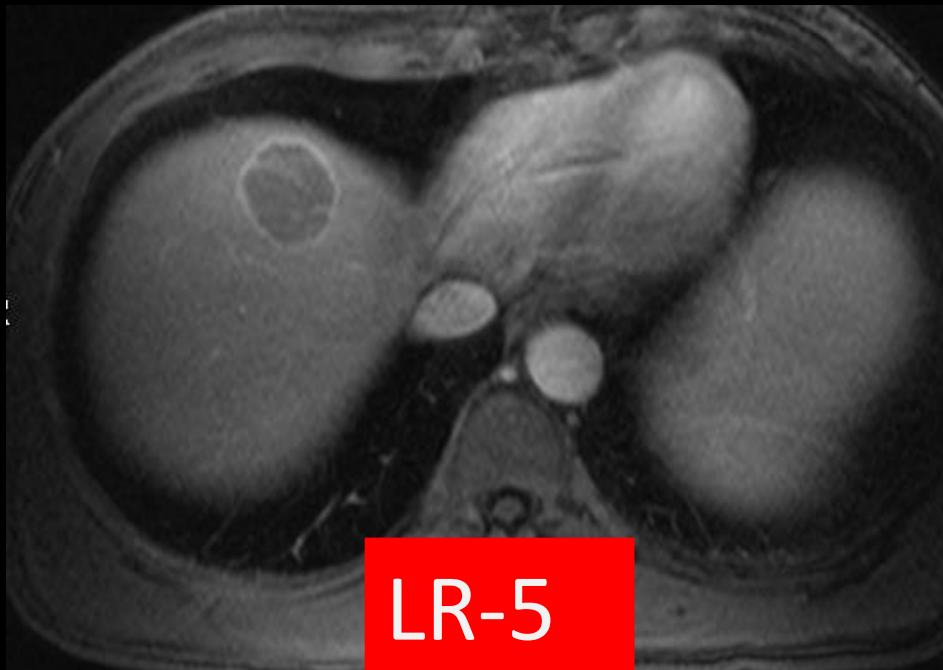


# Major Feature versus LR-M Feature?

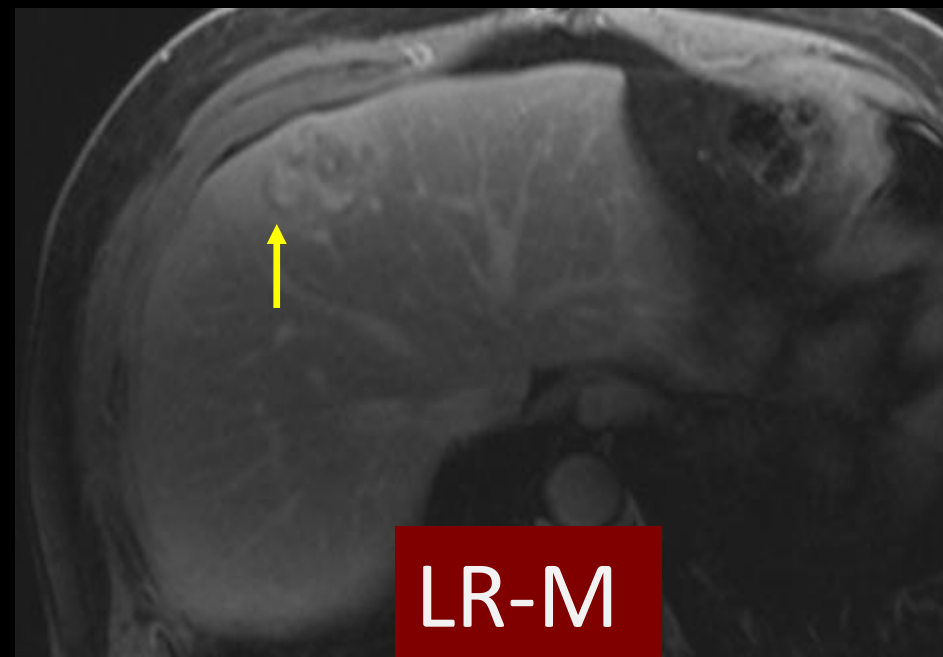




## Nonperipheral WO

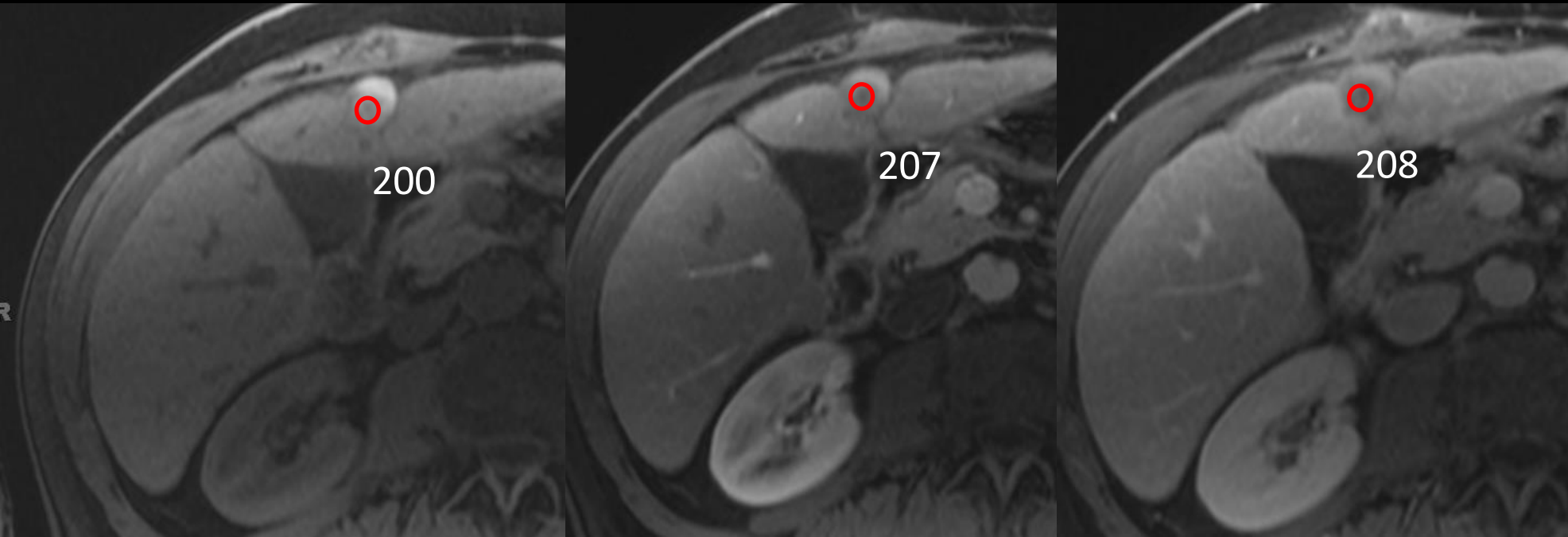


## Peripheral WO

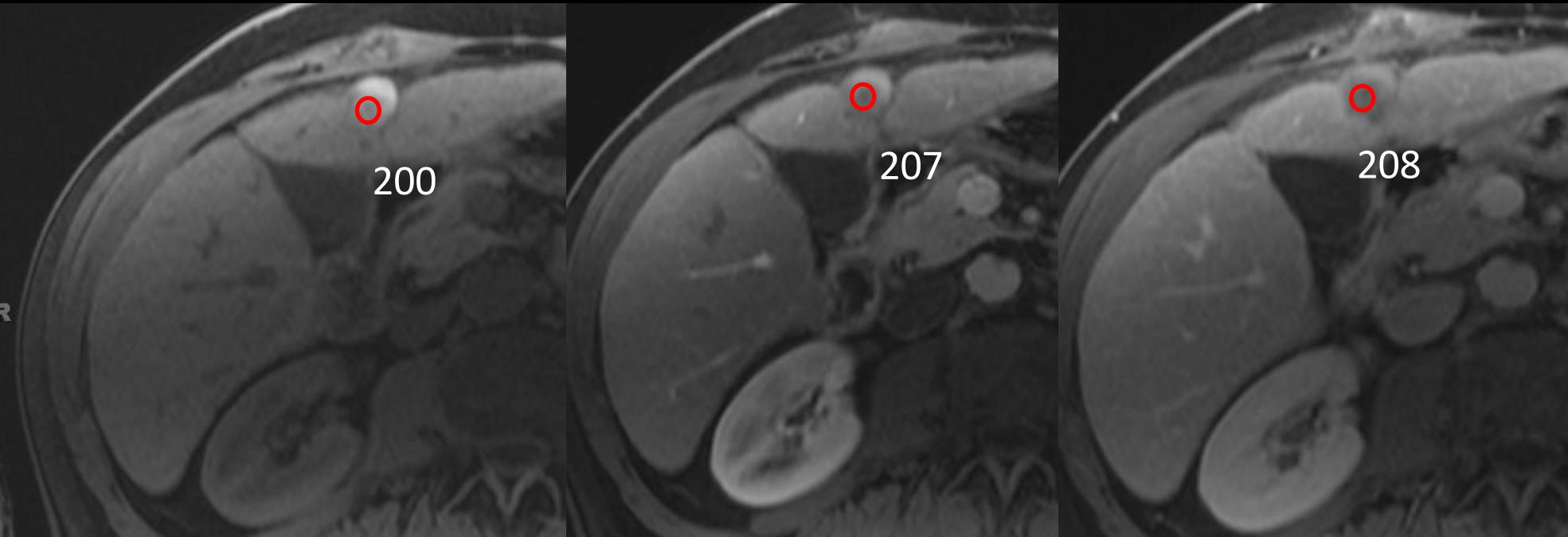




# Case 3 Does this lesion demonstrate nonperipheral washout appearance?



# Case 3 Does this lesion demonstrate nonperipheral washout appearance?

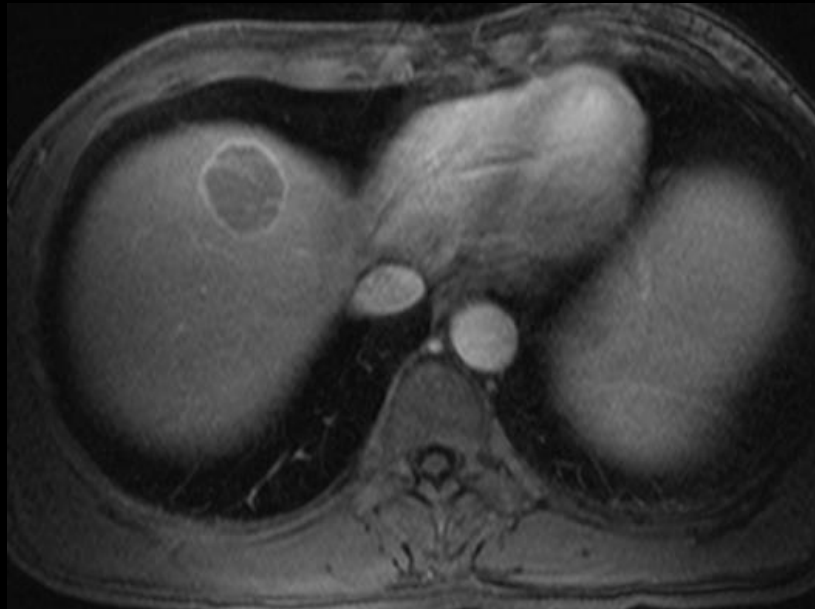
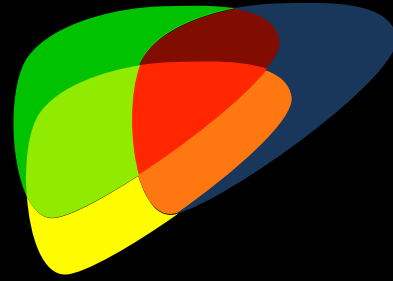


**No** There is no reduction in signal intensity over time.

Enhancing "capsule"



# Enhancing "Capsule"

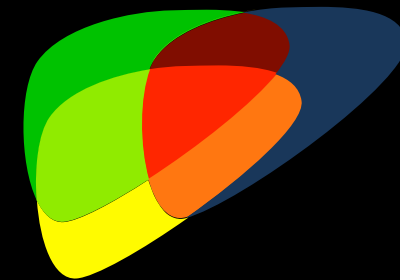


Smooth uniform, sharp border around  
most or all that is unequivocally thicker  
or more conspicuous than fibrotic tissue

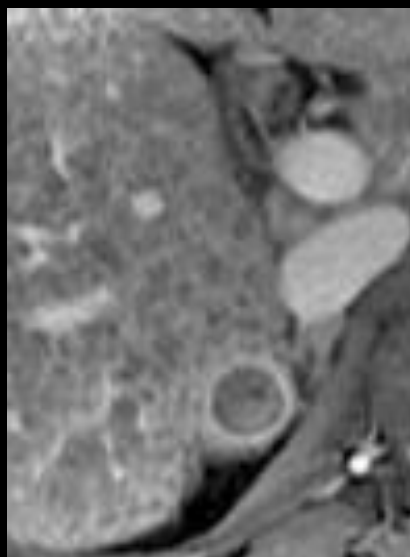
Enhancing "capsule"



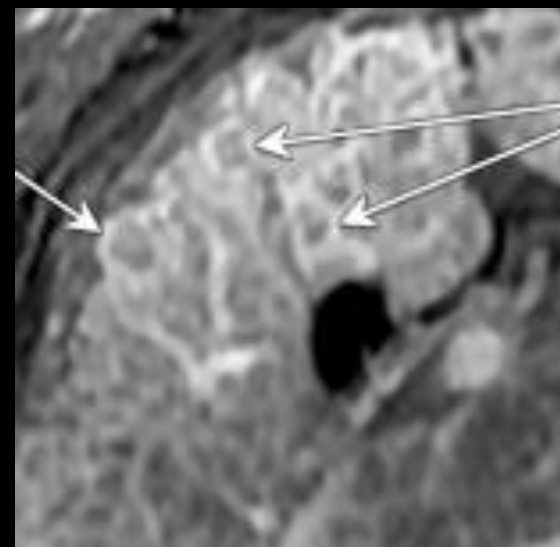
# Enhancing "Capsule"



"capsule"



No "capsule"

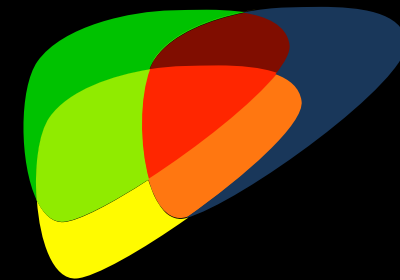


Must be thicker or more conspicuous than background fibrosis

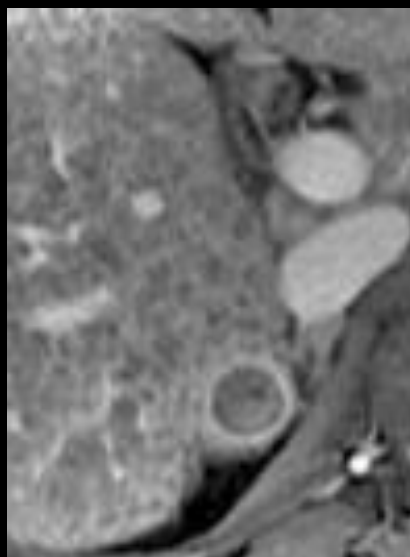
Enhancing "capsule"



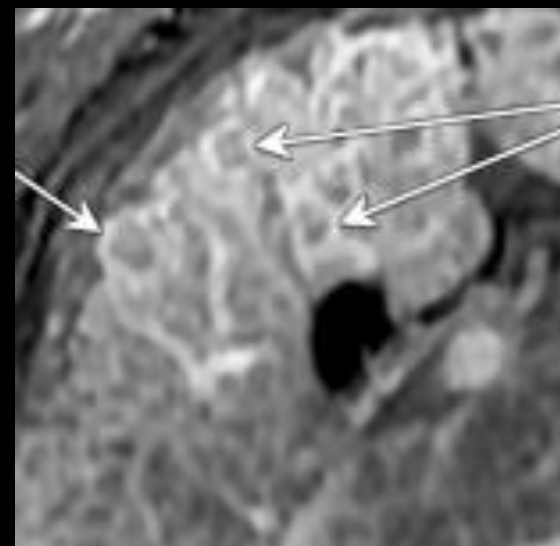
# Enhancing "Capsule"



"capsule"



No "capsule"

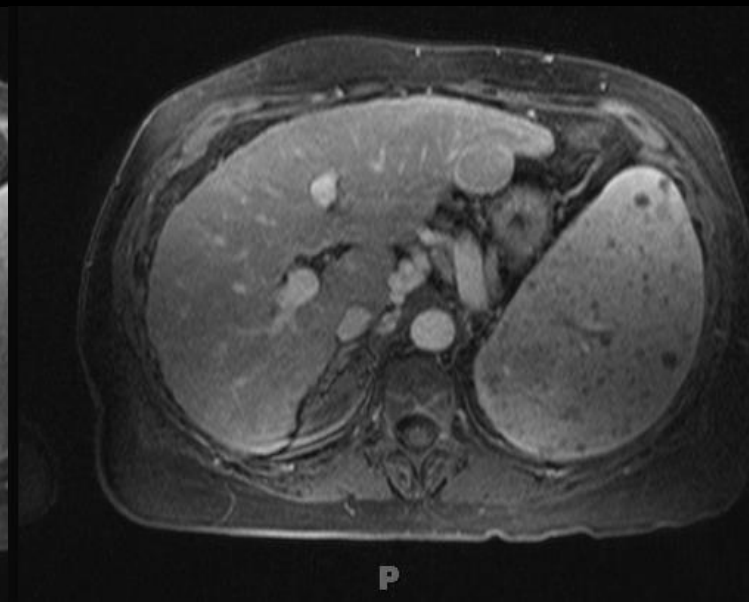
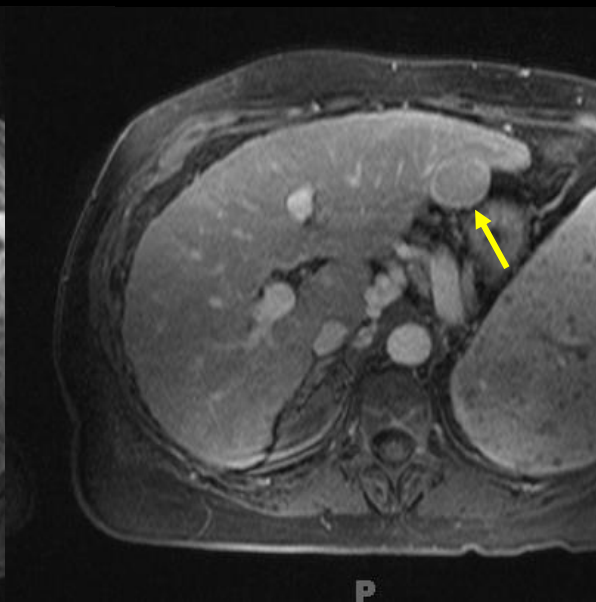
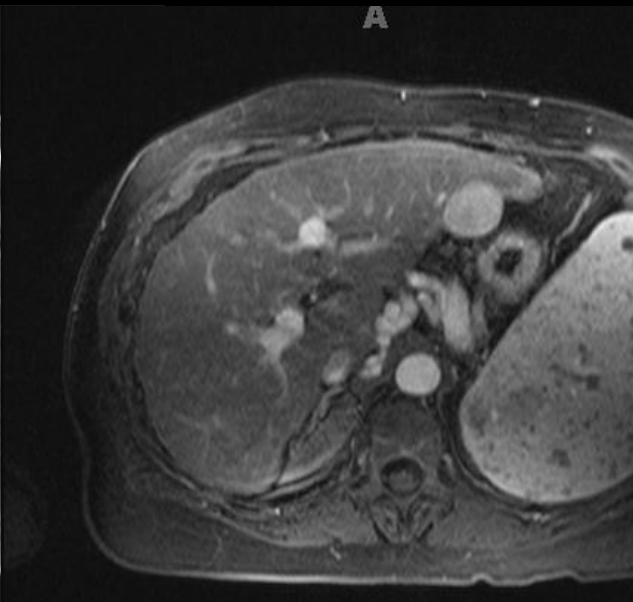
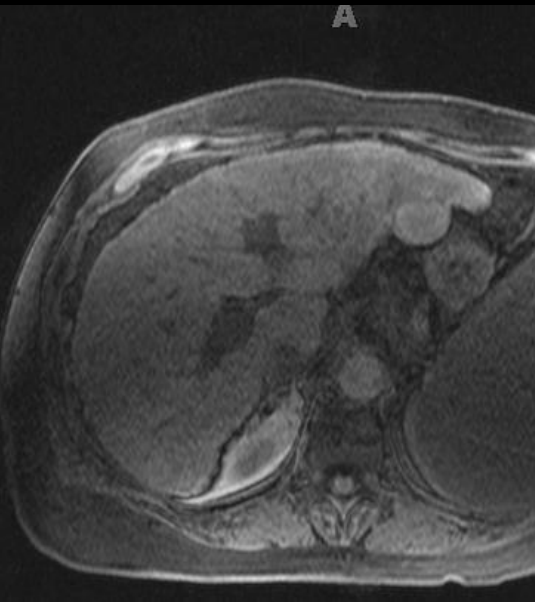


When in doubt...throw it out!



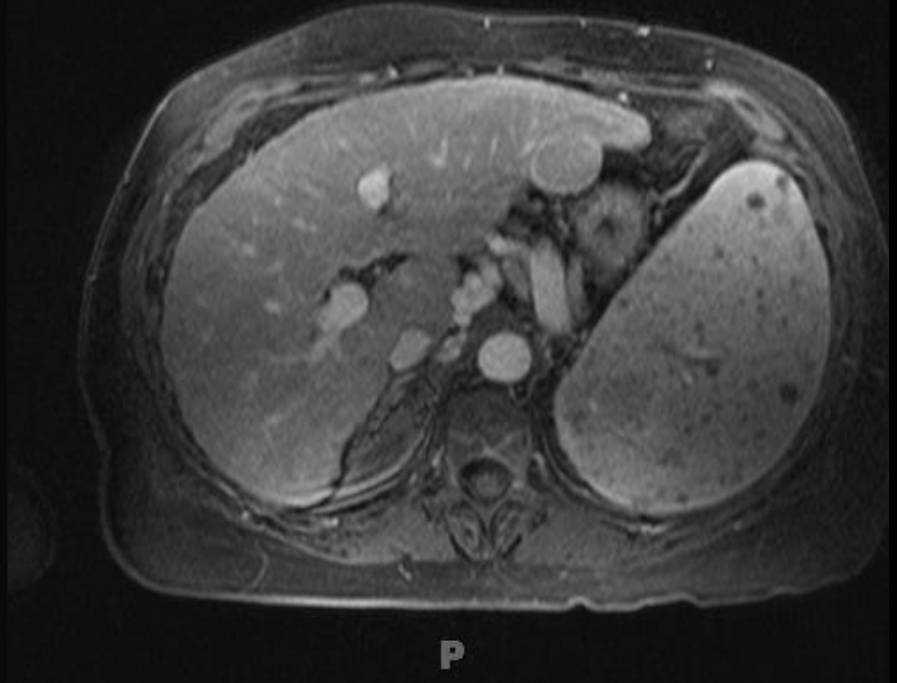
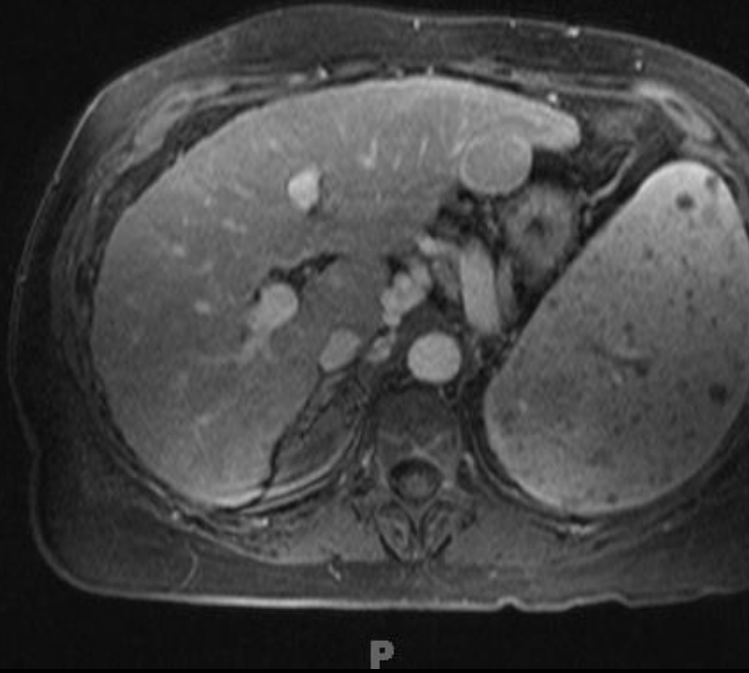
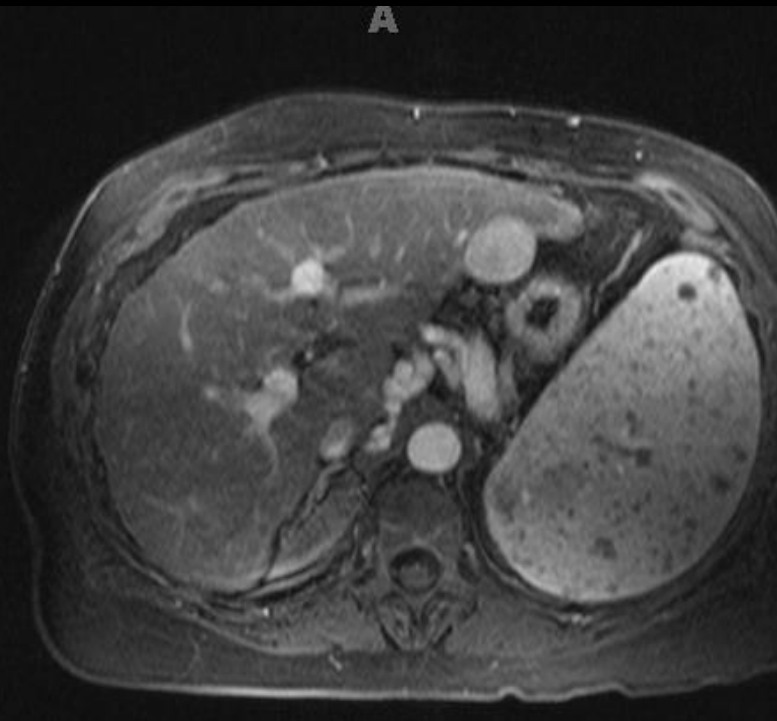
# Case 5

What *major features* are shown in the lesion?





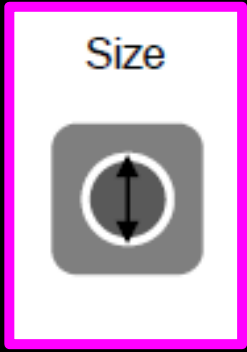
Case 5 What *major features* are shown in the lesion?



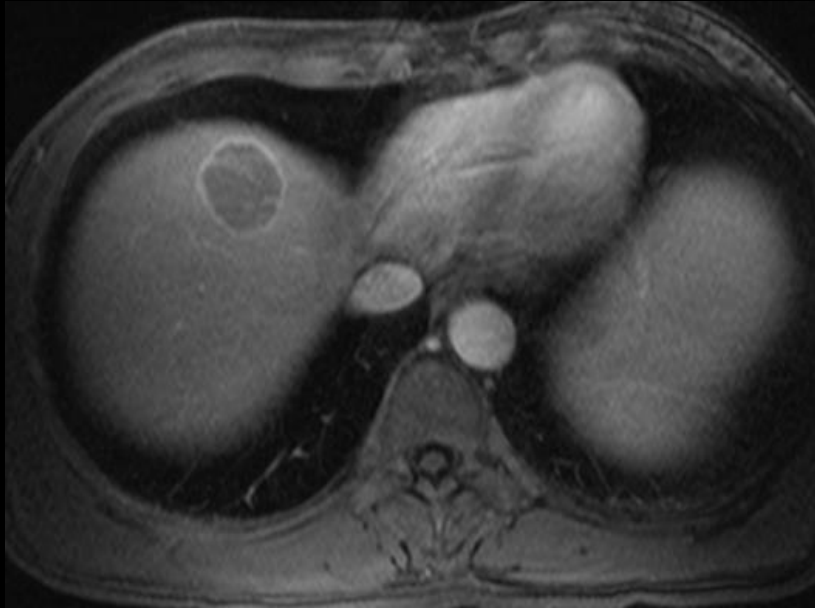
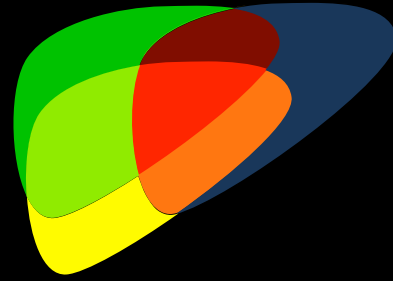
APHE, "Capsule"

No definite washout, similar to background liver



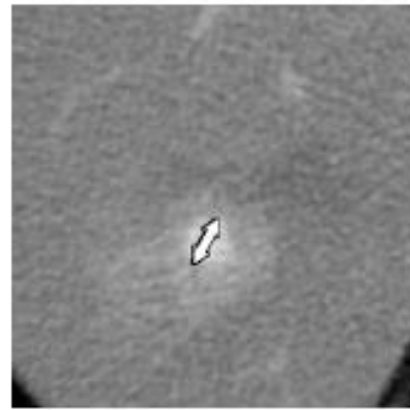
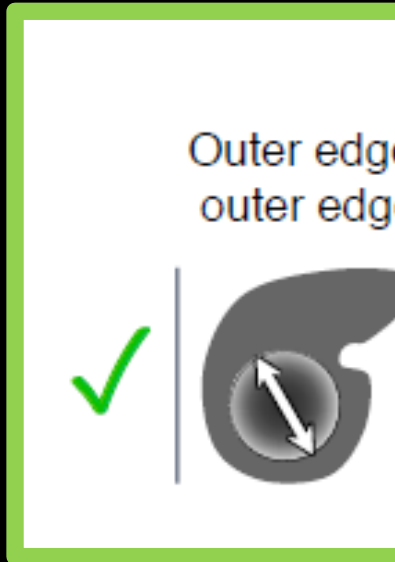
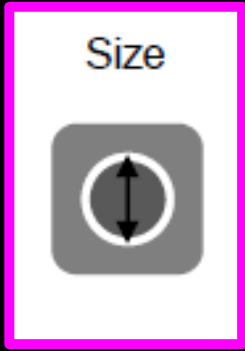
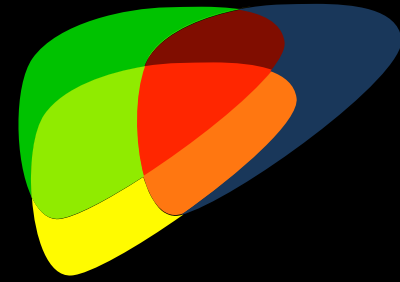


Size

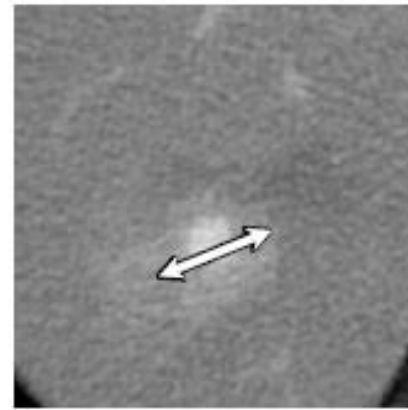


Largest out-edge-to-outer-edge  
dimension of an observation

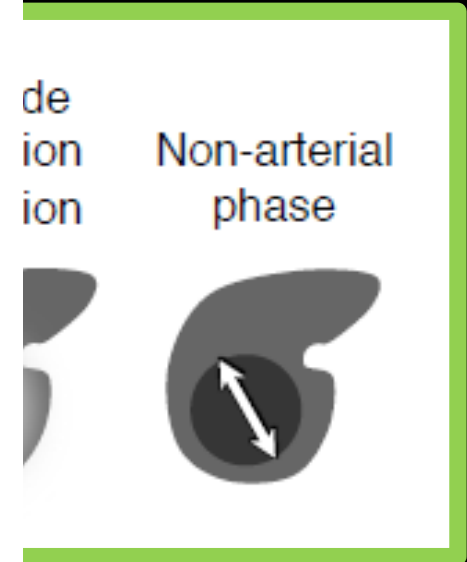
# Size



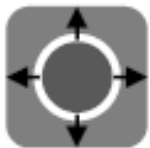✓  
Measurement  
excludes perfusion  
alteration



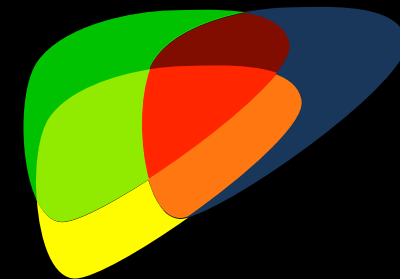
✗  
Measurement  
includes perfusion  
alteration



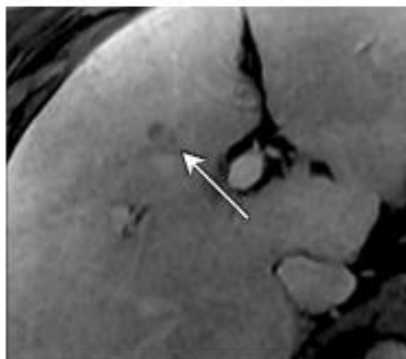
Threshold growth



# Threshold Growth

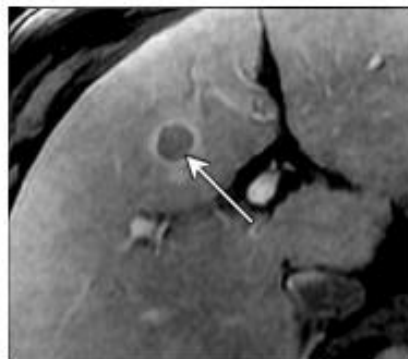

Initial MRI



Size: 12mm

4 month follow-up MRI

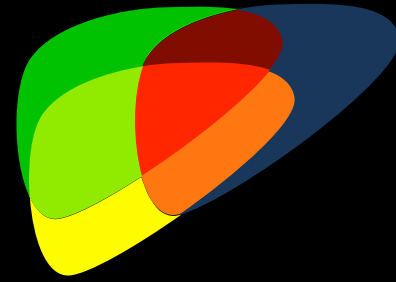


Size: 20mm

67% size increase  
in <6 mo = TG

> 50% size increase in < 6 months

# Summary



- Major Features are used to diagnose HCC (LR-5)
- Include:
  - Nonrim APHE
  - Nonperipheral WO
  - Capsule appearance
  - Size
  - TG



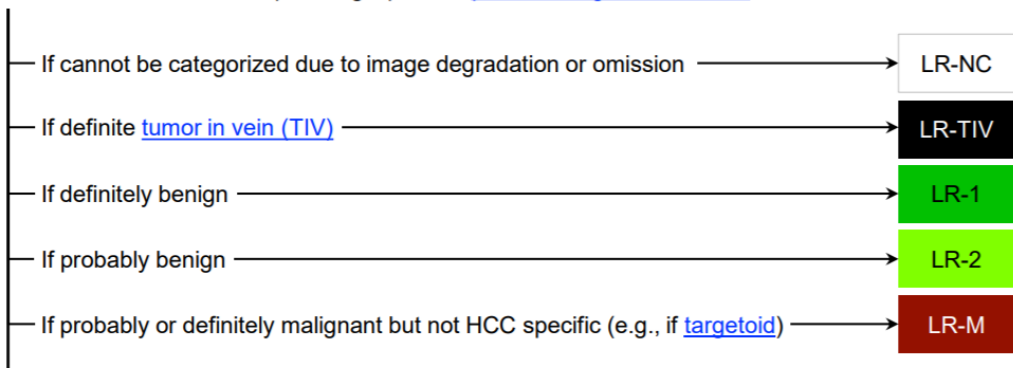
Must be unequivocally present  
Must be differentiated from LR-M



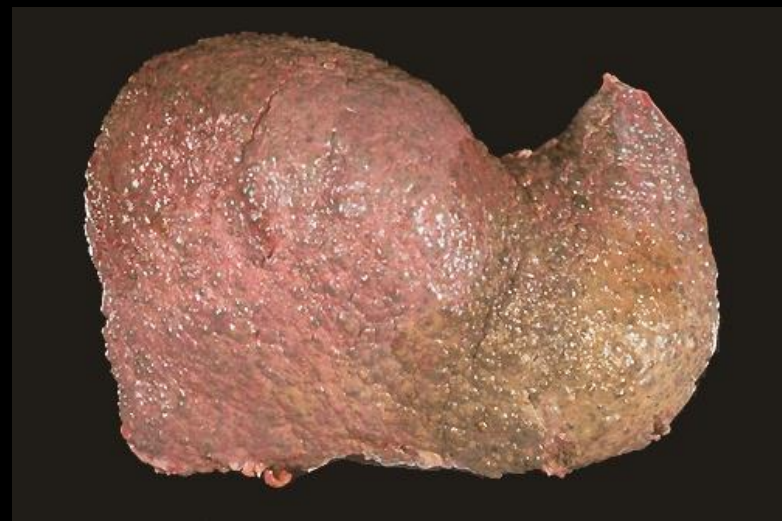
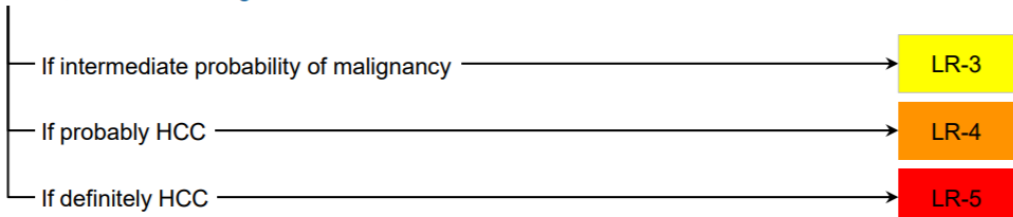


# CT/MRI LI-RADS® v2018 CORE

Untreated observation without pathologic proof in [patient at high risk for HCC](#)



Otherwise, use CT/MRI diagnostic table below



## CT/MRI Diagnostic Table

Arterial phase hyperenhancement (APHE)		No APHE		Nonrim APHE		
		< 20	≥ 20	< 10	10-19	≥ 20
Observation size (mm)						
Count additional major features: • Enhancing "capsule" • Nonperipheral "washout" • Threshold growth	None	LR-3	LR-3	LR-3	LR-3	LR-4
	One	LR-3	LR-4	LR-4	LR-4 / LR-5	LR-5
	≥ Two	LR-4	LR-4	LR-4	LR-5	LR-5

**LR-4 / LR-5** Observations in this cell are categorized based on one additional major feature:

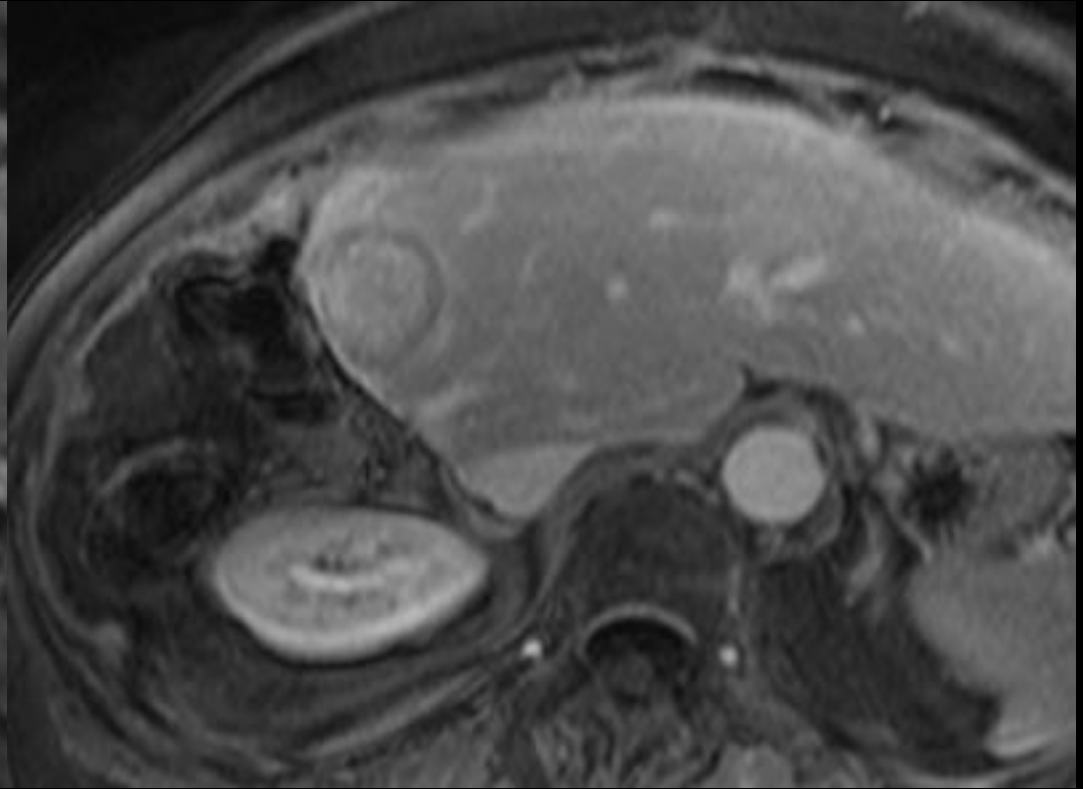
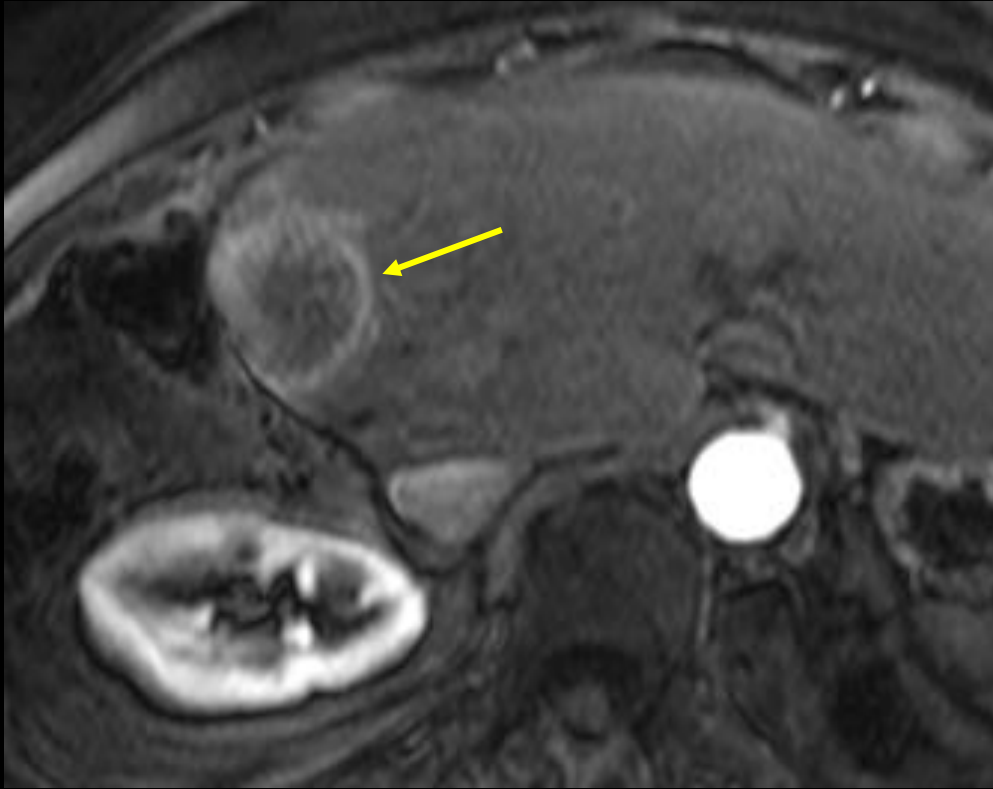
- LR-4 – if enhancing "capsule"
- LR-5 – if nonperipheral "washout" **OR** threshold growth

*If unsure about the presence of any major feature: characterize that feature as absent*



Let's apply our knowledge

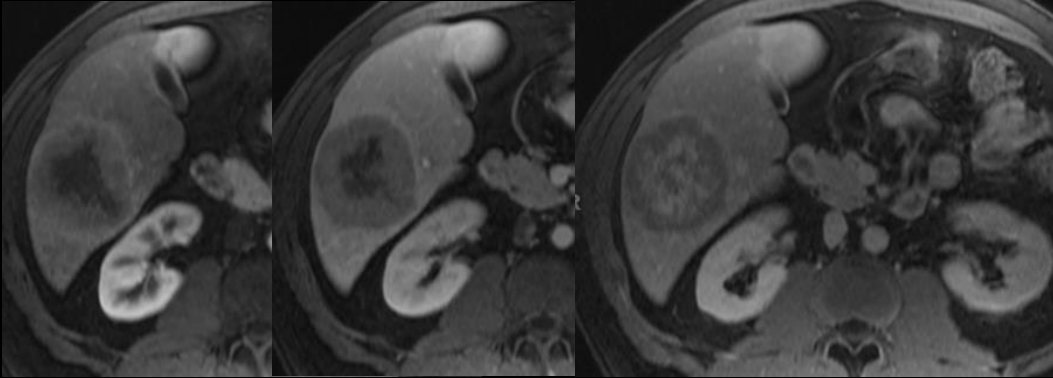
# LR-Category?



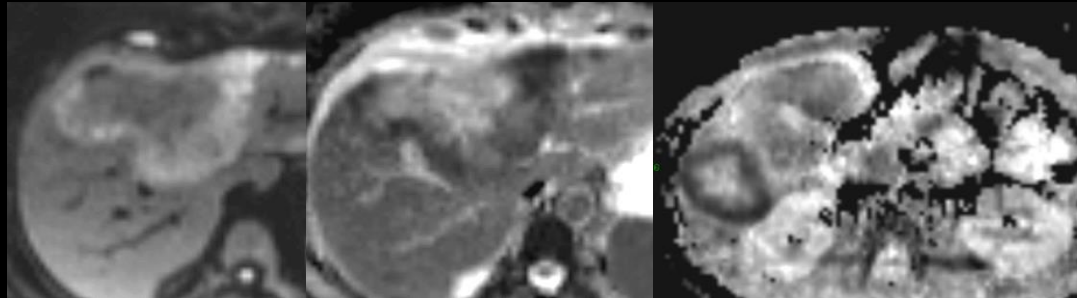


**LR-M: Probably or definitely malignant, not HCC specific**

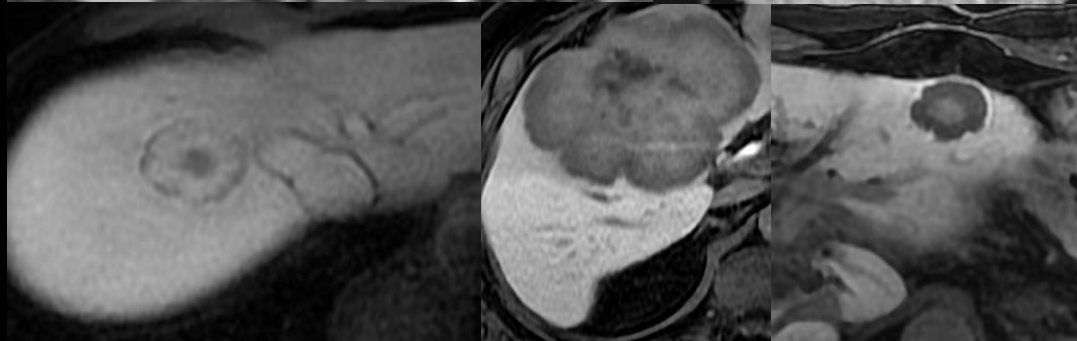
# Targetoid Features



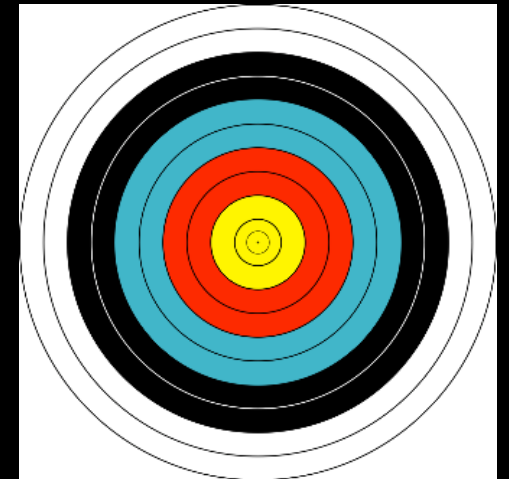
Targetoid dynamic  
enhancement pattern



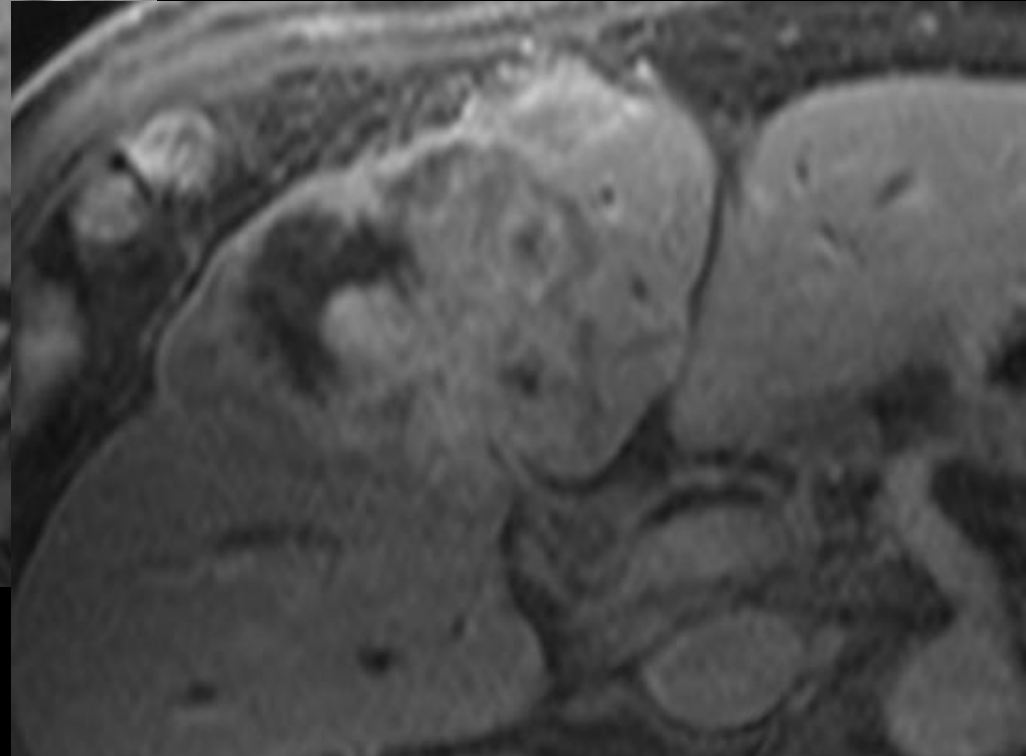
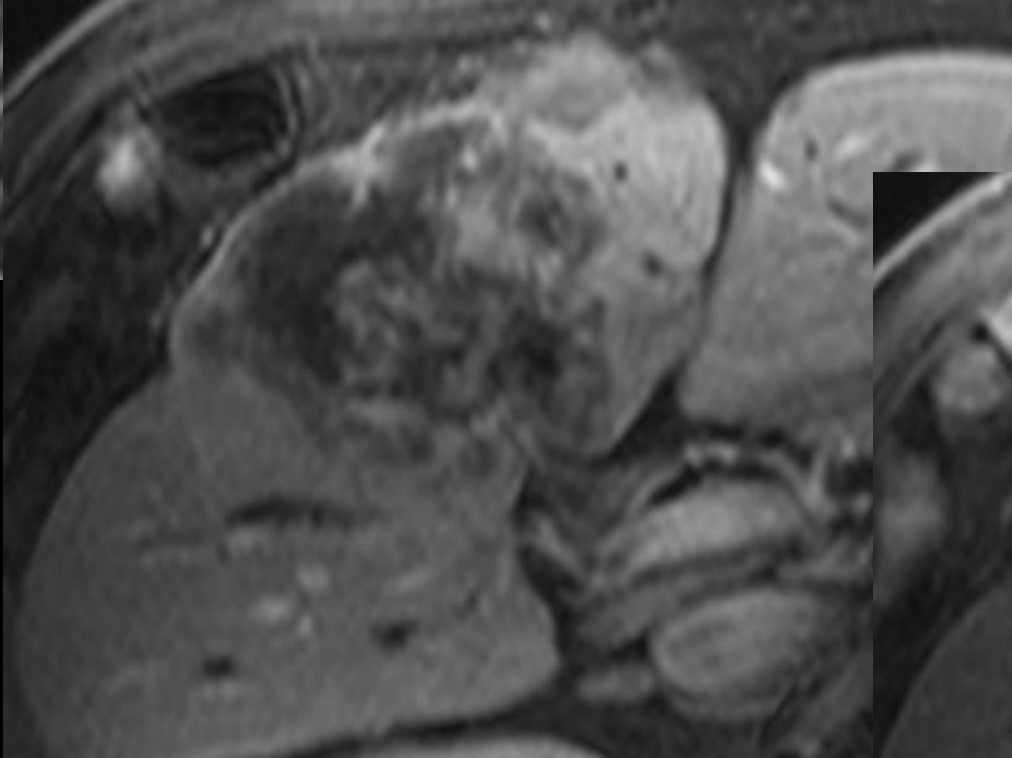
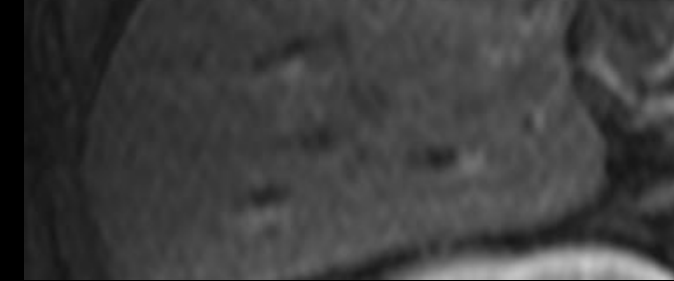
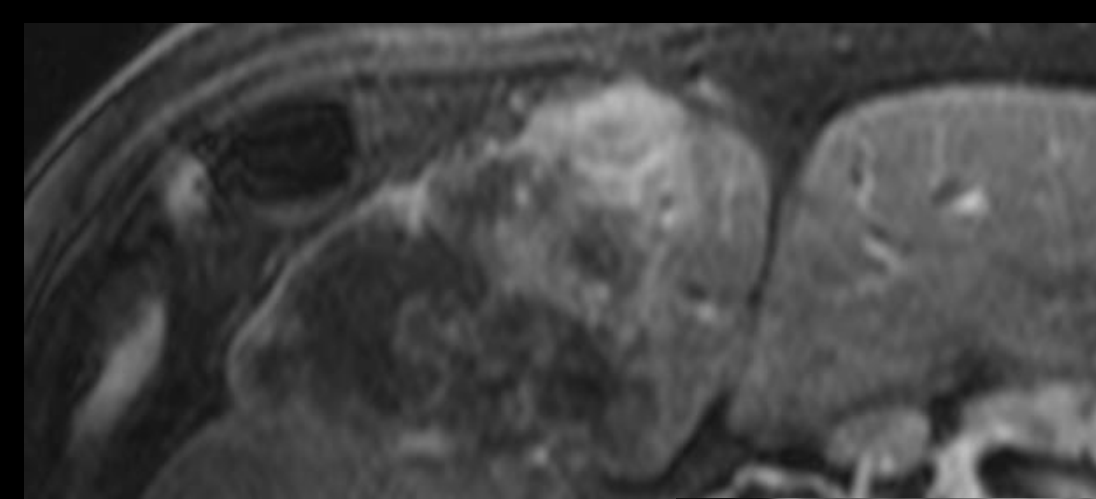
Targetoid DWI



Targetoid HBP

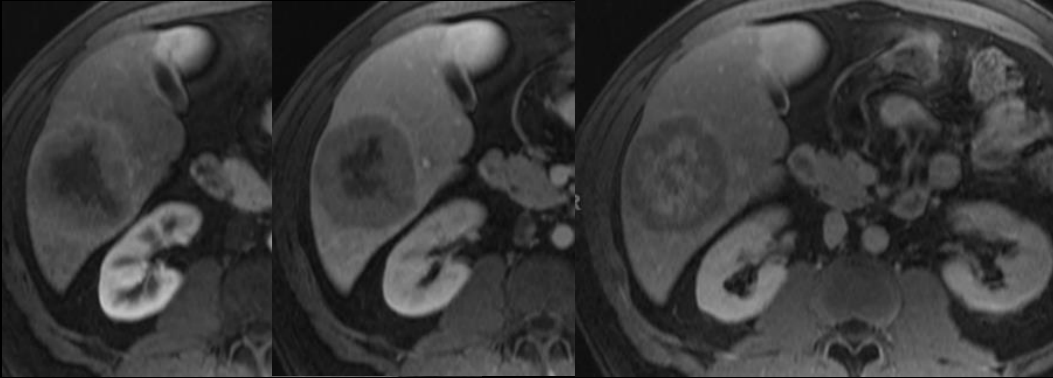


LR-Category?

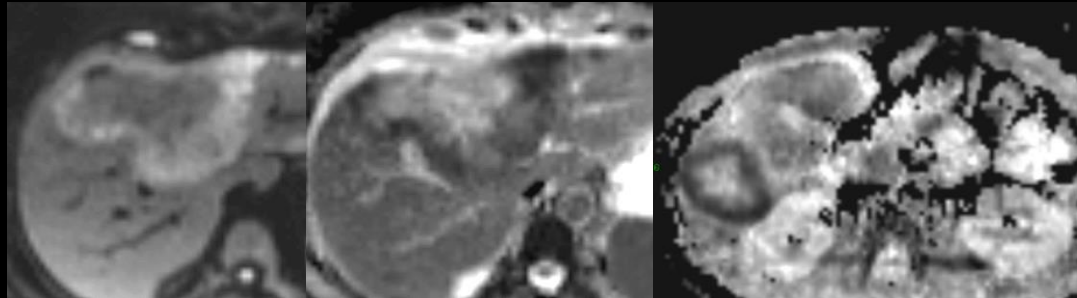


**LR-M: Probably or definitely malignant, not HCC specific**

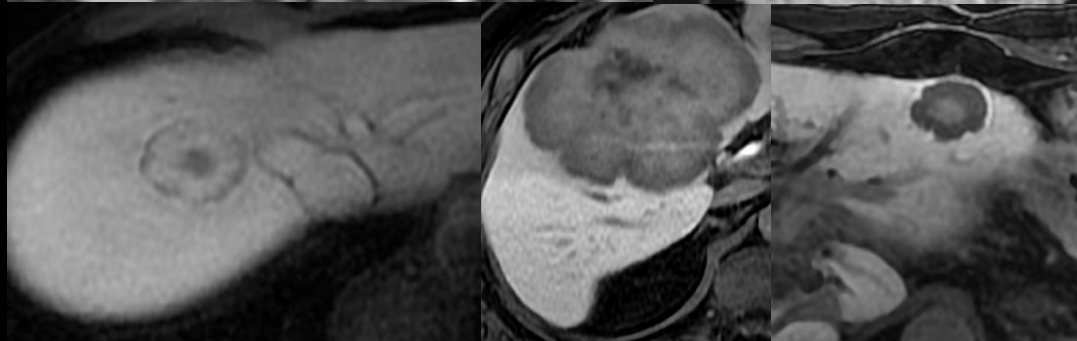
# Targetoid Features



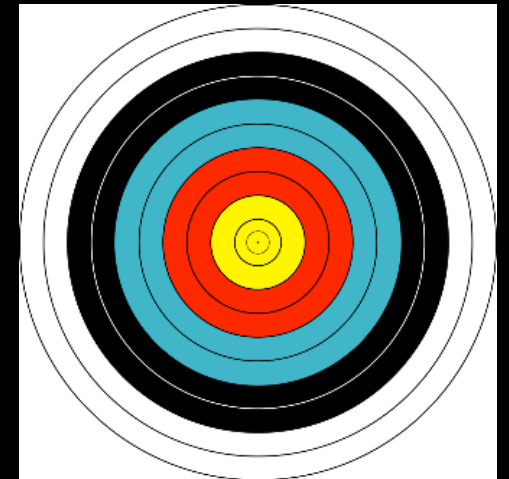
Targetoid dynamic  
enhancement pattern



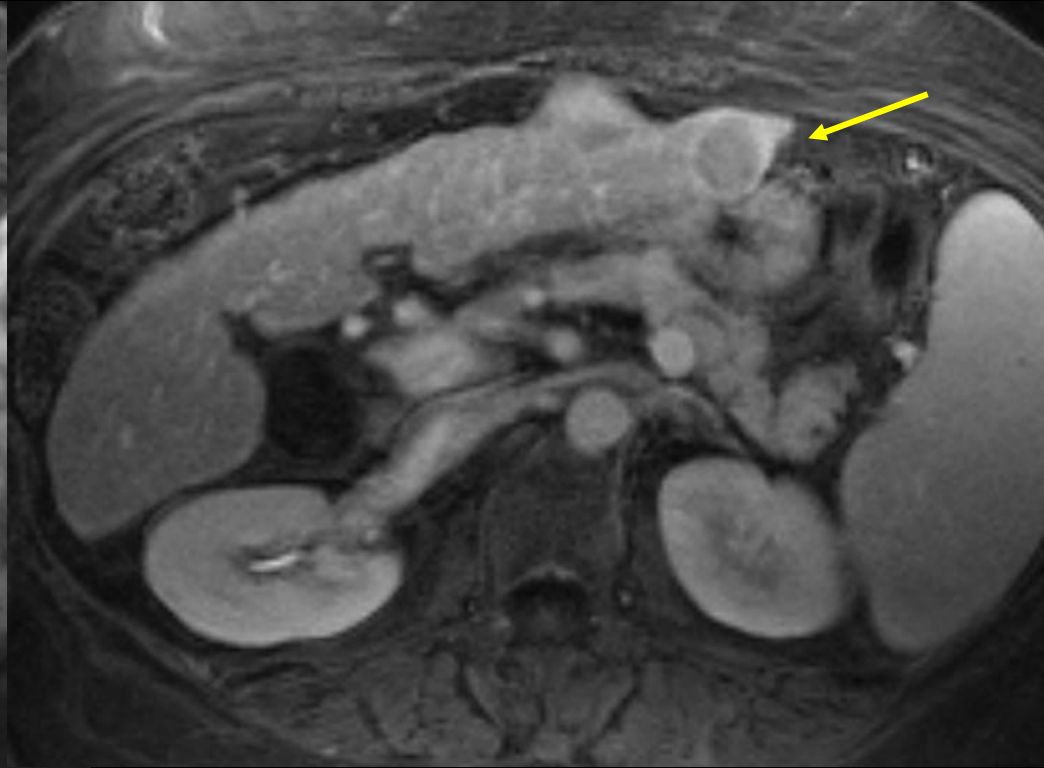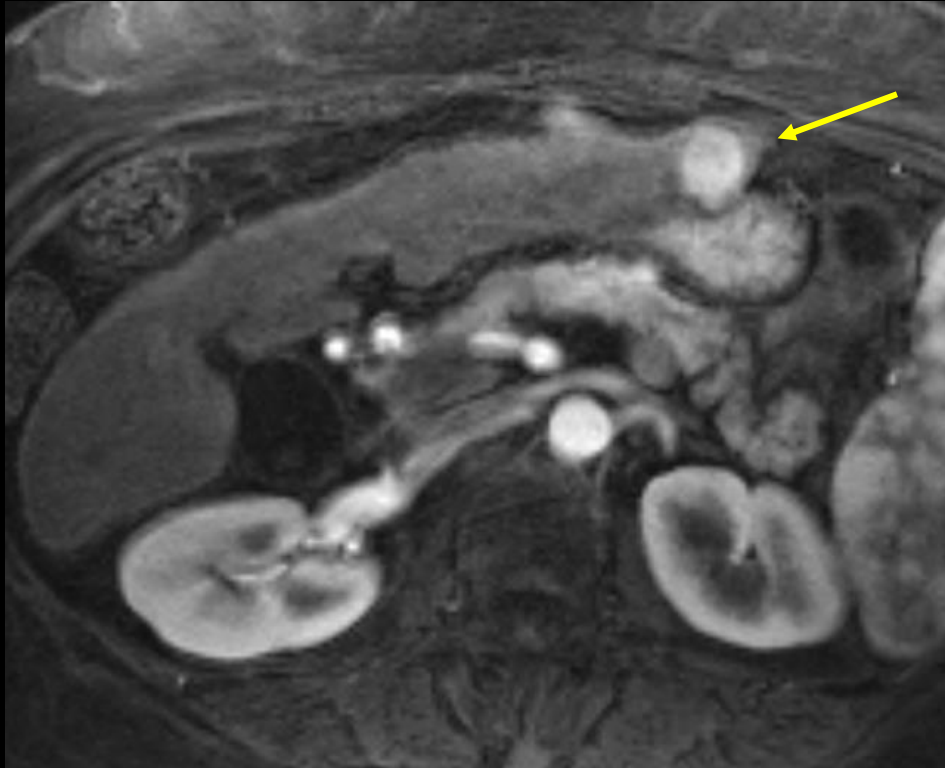Targetoid DWI



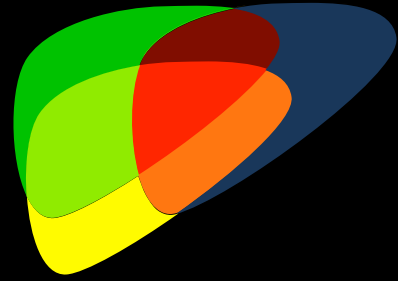
Targetoid HBP



# LR-Category?

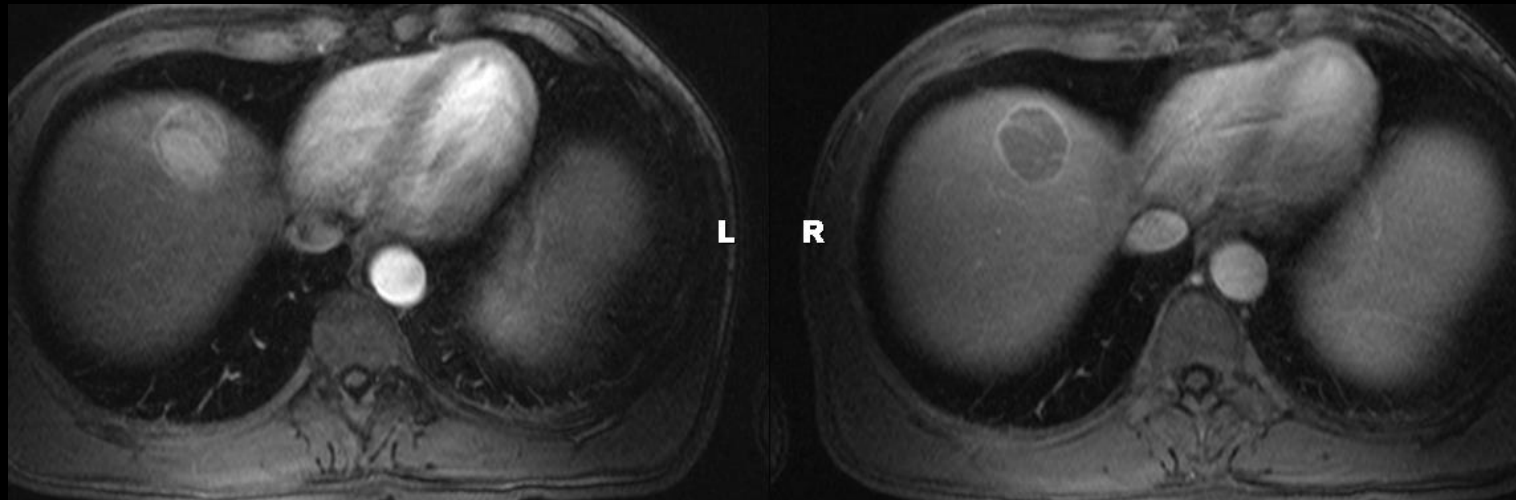


# LR-5: Criteria



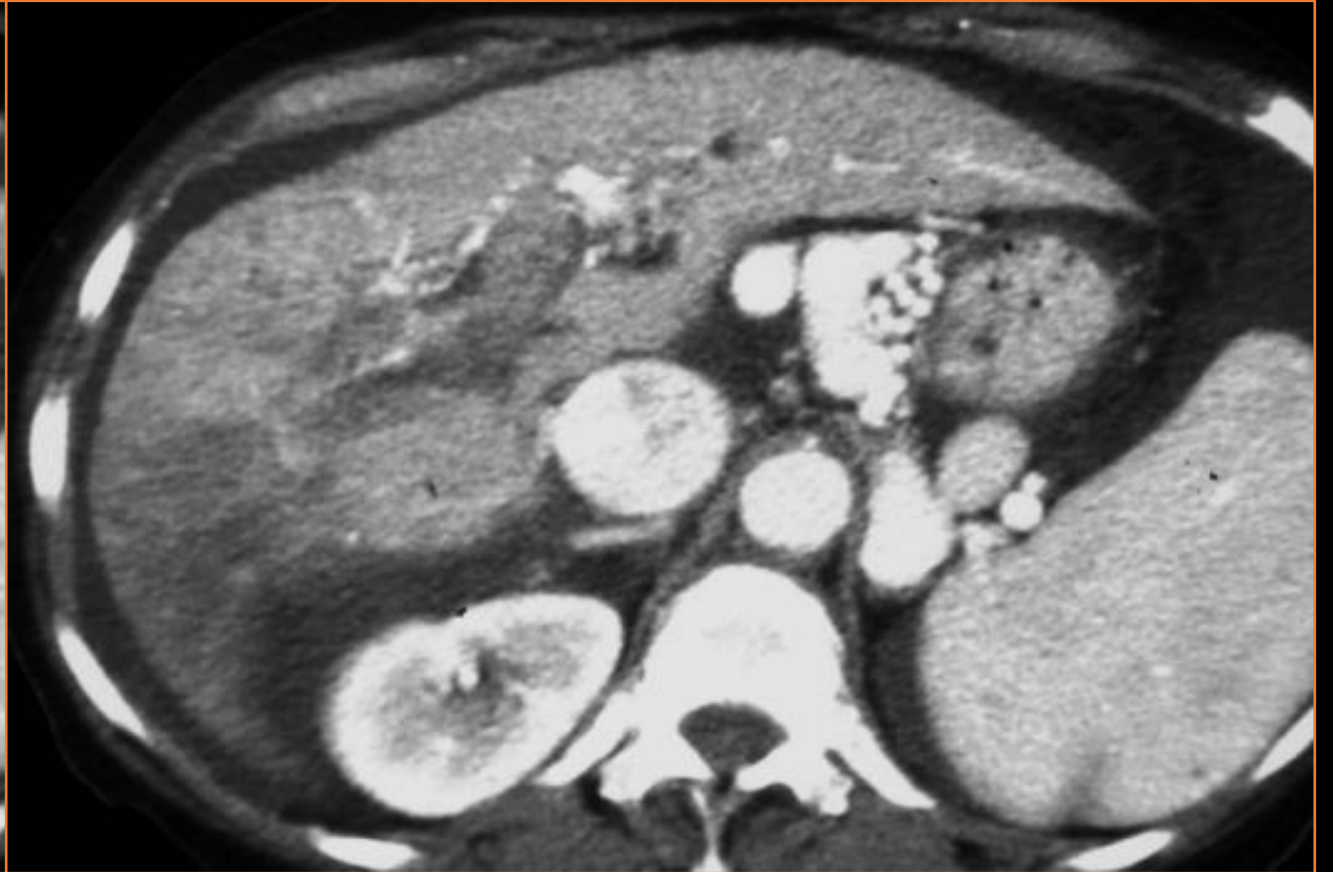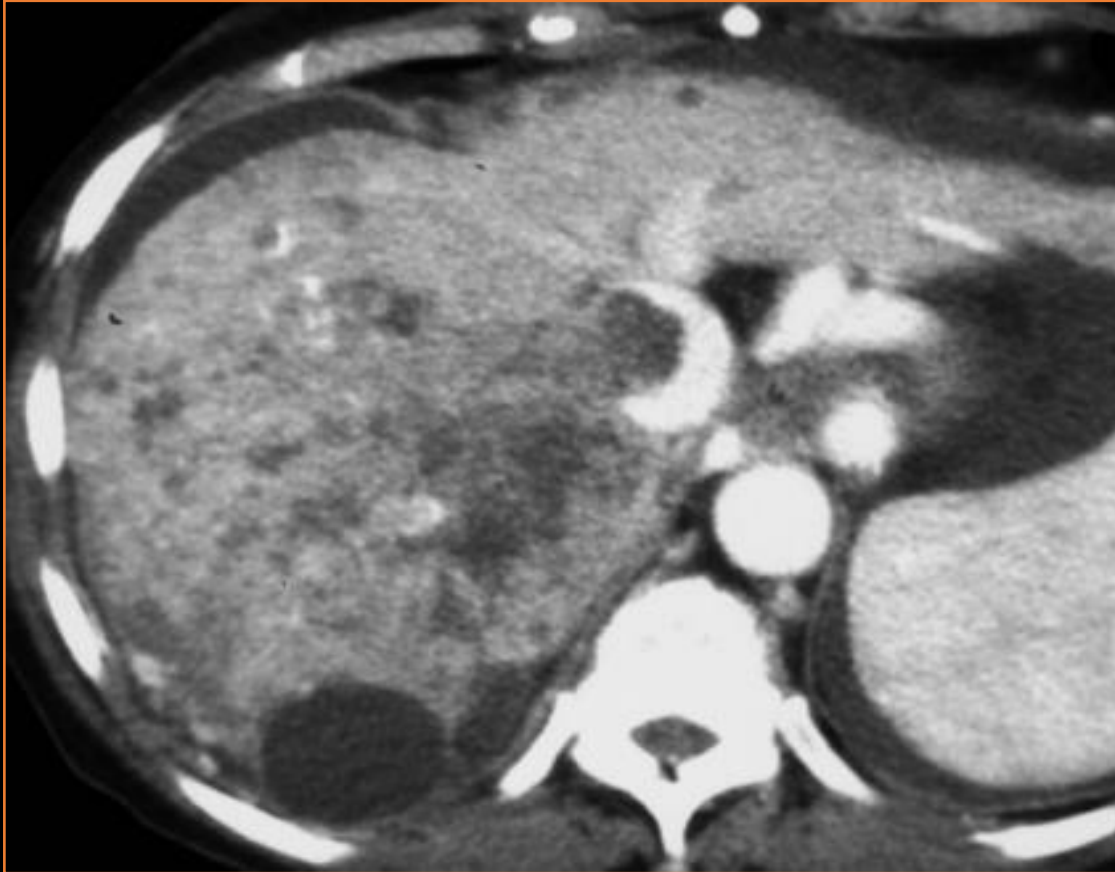## LR-5: Definitely HCC

- Unequivocal features
  - 10-19 mm: non-rim APHE + WO or APHE + TG
  - $\geq 20$  mm: non-rim APHE + WO, or APHE + Capsule, or APHE + TG

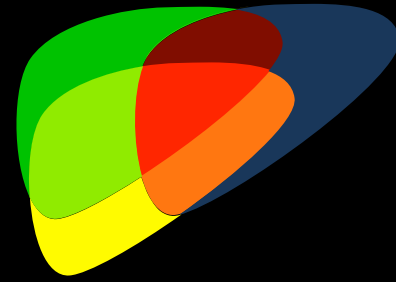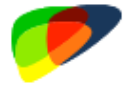




# LR-Category?

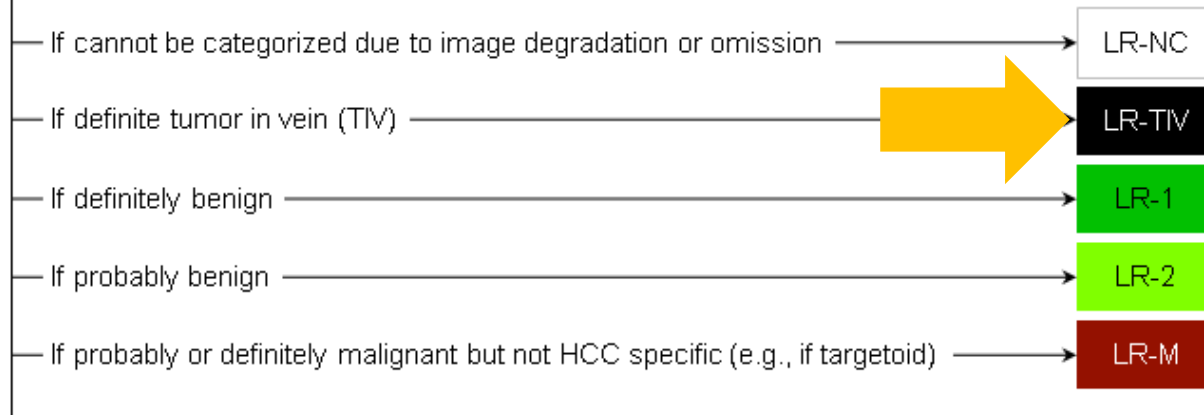


# Step-wise algorithm

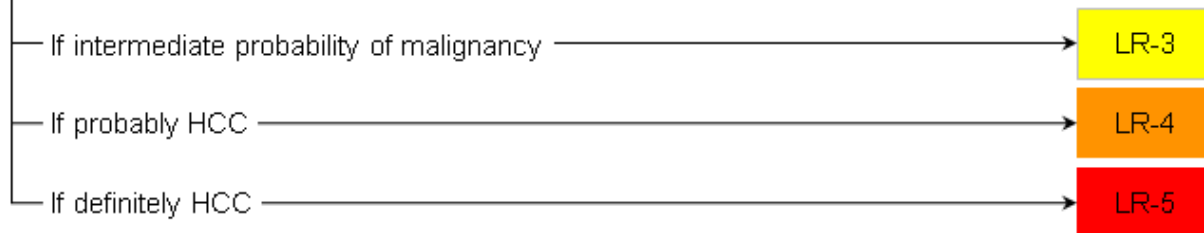


## CT/MRI LI-RADS® v2018

Untreated observation without pathologic proof in patient at high risk for HCC



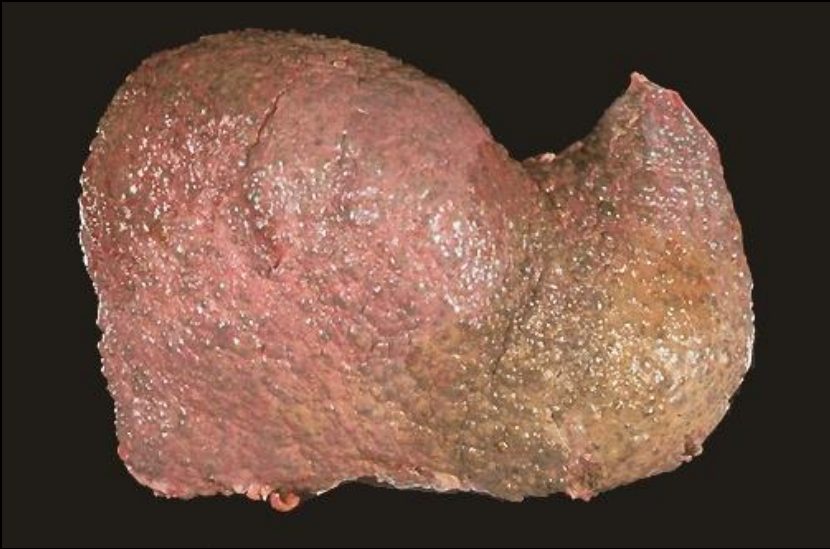


Otherwise, use CT/MRI diagnostic table below



Unequivocal enhancing soft tissue in vein





Primary Liver Cancer  
-HCC, ICC

Metastases (less common)

# Resources



**Magnetic Resonance Imaging of Focal Liver Lesions:  
Approach to Imaging Diagnosis**

Kathryn J. Fowler, Jeffrey J. Brown, and Vamsi R. Narra



LI-RADS ACR website



# Thanks!

- Questions: [k1fowler@ucsd.edu](mailto:k1fowler@ucsd.edu)